

DOI: <http://dx.doi.org/10.18203/2320-1770.ijrcog20202756>

Case Report

Pseudo-Meigs syndrome: a rare presentation of pedunculated fibroid

Sunita Dubey^{1*}, Poonam Goel¹, Nidhi Pandey¹, Pavithra H. N.²

¹Department of Obstetrics and Gynecology, Government Medical College and Hospital, Sector-32, Chandigarh, India

²Department of Pathology, Government Medical College and Hospital, Sector-32, Chandigarh, India

Received: 20 April 2020

Accepted: 28 May 2020

*Correspondence:

Dr. Sunita Dubey,

E-mail: sunitas504@gmail.com

Copyright: © the author(s), publisher and licensee Medip Academy. This is an open-access article distributed under the terms of the Creative Commons Attribution Non-Commercial License, which permits unrestricted non-commercial use, distribution, and reproduction in any medium, provided the original work is properly cited.

ABSTRACT

Serosal fibroid of uterus are usually asymptomatic but rarely; it may present with atypical symptoms to simulate malignancy and needs extensive evaluation. Authors are reporting a case of 26 years old P1L1 female with history of asymptomatic multiple intramural fibroids since 6 years came with complained of progressively increasing abdominal distension and mild pain abdomen from 2-3 months. On evaluation, she had ascites, pleural effusion and raised Ca-125. MR imaging of pelvis revealed moderate ascites and pedunculated serosal fibroid in addition to intramural fibroids with normal bilateral ovaries. She was evaluated to rule out uterine sarcoma and tuberculosis but diagnosis of them could not be established. Finally, conclusion of Pseudo-Meigs syndrome was made. Myomectomy of single pedunculated fibroid relieved her symptoms. Though, subserosal fibroids are benign in pathology, timely surgery is must to avoid morbidity and mortality owing to massive ascites and pleural effusion.

Keywords: Ascites, Leiomyoma, Meig's syndrome, Pedunculated fibroid, Pseudo-Meigs syndrome

INTRODUCTION

Meig's syndrome has been characterized by ascites and pleural effusion along with benign ovarian fibroma while Pseudo-Meigs syndrome develops in pelvic tumors other than benign ovarian fibroma.^{1,2} Fibroid uterus is the most common pelvic tumors usually present as abnormal uterine bleeding, dysmenorrhea, infertility, and pressure symptoms.³ However, very few cases of fibroids with Pseudo-Meigs syndrome have been reported. Here, we are presenting a case of young female with multiple uterine fibroids with absence of any fibroid related symptoms; however other symptoms were suspicious of malignancy.

CASE REPORT

A 26 years old P1L1 came with complaints of progressively increasing abdominal distension and mild pain in lower abdomen from 2-3 months. There were no complaints of anorexia and weight loss. Urinary and

bowel complaints were also absent. There was no history of prolonged fever and cough. Her menstrual cycles were regular with average blood flow.

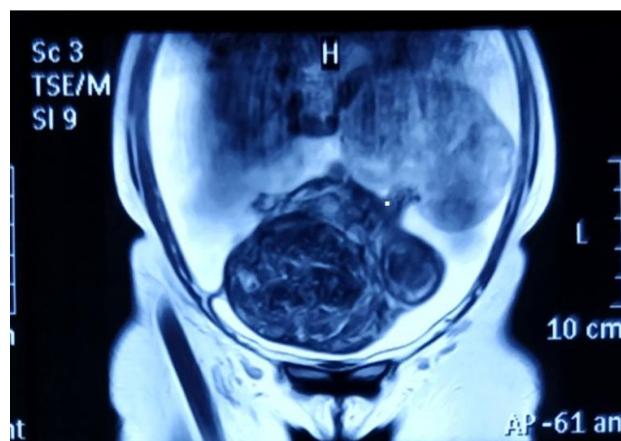


Figure 1: MRI T2 weighted of multiple intramural fibroids with one pedunculated fibroid of uterus.

She gave history of primary infertility for that she was investigated and incidentally diagnosed with asymptomatic multiple intramural fibroids uterus 6 years back. She conceived spontaneously and had normal vaginal delivery 2½ year back. Her medical and family history was not significant.

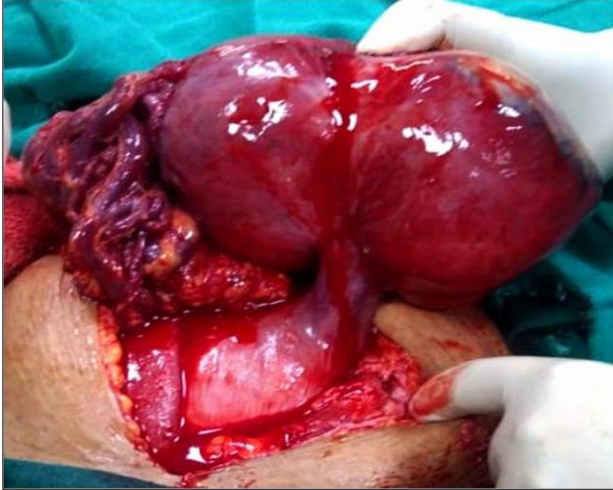

Figure 2: Intra-operative findings confirmed large pedunculated fibroid uterus with attached large bore feeding vessels from omentum.

On per abdominal examination, abdomen was slightly distended without tenderness and guarding. Shifting dullness was suggestive of abdominal ascites. However, a large firm; nontender abdominal mass of about 10×12 cm size with well-defined margin was felt and seems to be arising from the left side of uterine fundus. Vaginal examination revealed enlarged uterus (14 weeks in size), cervical movements were transmitted to the large pelvic mass which was felt in the abdomen on the left side. Bilateral fornices were full but no other separate mass felt.

Pelvic ultrasonography revealed enlarged uterus with fibroid of approx. 10.5×9 cm in posterior myometrium and another complex solid mass 11.7×7.5 cm with internal vascularity was seen in left adnexa. Right ovary was bulky and moderate amount of ascites was also seen. As left ovary was not seen separately from the mass, MRI was planned that revealed a large pedunculated lesion approx. 11.8×9.4 cm seen on left anterolateral wall of uterus with multiple small flow voids suggestive of degenerated fibroid receiving blood supply from omentum through large bore vessels with coexisting multiple intramural fibroids and significant ascites (Figure 1). Both ovaries and other organs were normal. CECT chest revealed minimal right pleural effusion. Initially ovarian tumor was suspected that's why Ca 125 (108U/mL) was done which was mildly raised. Ascitic fluid was negative for malignant cells and mycobacterium tuberculosis. Fine needle aspiration of mass (FNAC) from the pedunculated fibroid was inconclusive. Other blood investigations including ECG

were normal. Patient was counseled regarding possibility of ascites and raised CA 125 due to subserosal fibroid. As there were multiple fibroids, myomectomy of all fibroids may lend her up into hysterectomy. Considering her incomplete family, young age and asymptomatic intramural fibroids, option of only subserosal myomectomy was given to her.

She underwent laparotomy, along with moderate ascites there was one large 14.5×9.8×4.5 cm pedunculated subserosal uterine fibroid that was acquiring blood supply from omentum was removed while intramural fibroids were left untreated (Figure 2). Frozen section was also planned but deferred due to gross features of benign leiomyoma. She was discharged on post-operative day 4. Histopathological examination confirmed benign leiomyoma. She has been asymptomatic after 1 year of follow up.

DISCUSSION

Pseudo-Meig's syndrome is a rare condition characterized by pleural effusion, ascites along with masses other than ovarian fibroma. Ascites and pleural effusion usually disappear after excision of pelvic mass.¹ It has been seldom reported in pedunculated type of fibroid uterus when there is additional blood supply from the adjacent organs like bladder in anterior wall fibroid and from omentum like in present case.

There are no well-established causes of ascites in Pseudo-Meig's syndrome whereas different theories have been co-related with it. Discrepancy between massive blood supply and venous and lymphatic drainage along with transduction of fluid from the necrotic fibroid have been reported as a cause of ascites. Direct irritation of peritoneal surfaces by any hard tumor either fibroids or ovarian mass may lead to increased production of peritoneal fluid. Various mediators like vascular endothelial growth factor and interleukin-6 have also been co-related with ascites owing to increased vascular permeability. In later period, fluid from abdominal cavity may traverse through the diaphragm into pleural cavity through the partially patent foramen of Bochdalek.

Patients may be asymptomatic in initial stage like in present case whereas abdominal distension, anorexia, weight loss and dyspnoea develops later on as a result of massive accumulation of fluid in peritoneal and pleural cavity. Some atypical presentations of fibroid related Pseudo-Meigs syndrome like pericardial effusion, puerperal ascites and hemorrhagic shock have been reported.^{4,5} Raised serum cancer antigen has been found up to the level of 1007.9 U/ml in fibroid associated Pseudo-Meigs syndrome whereas in this study it was raised only mildly and raised suspicious of tuberculosis and malignancy.⁶ Other than uterine fibroids, broad ligament fibroid, ovarian leiomyoma and leiomyoblastoma of the colon have also been reported among benign causes of Pseudo-Meigs syndrome.⁷

Leiomyosarcoma is a very rare entity, it should be excluded by imaging and frozen section whenever in doubt. Authors have also reported Pseudo-Meigs syndrome in case of ovarian metastasis of gastrointestinal malignancies following evaluation of ascites where endoscopy is must that was not done in present case due to absence of symptoms.^{8,9} Authors did her timely treatment as sudden death may happen due to collapsed lungs secondary to massive pleural effusion.¹⁰ So, management in these cases may vary from initial stabilization with mechanical ventilation followed by definitive management. Ascites and pleural effusion usually disappear after removal of pathology like in present case. Therapeutic pleural tap may be required in cases of re-accumulation.

CONCLUSION

Leiomyosarcoma, gastro-intestinal malignancy and tuberculosis should be excluded prior to making diagnosis of Pseudo-Meigs syndrome due to benign pathology. Young patients with multiple fibroids can be managed by conservative surgery with myomectomy of serosal fibroid alone.

Funding: No funding sources

Conflict of interest: None declared

Ethical approval: Not required

REFERENCES

1. Meigs JV. Fibroma of the ovary with ascites and hydrothorax; Meigs' syndrome. Am J Obstet Gynecol. 1954;67:962-85.
2. Yamuna J, Rajeswaran R, Prabhu R, Usha R. Pseudo Meig's syndrome: an unusual presentation. Br J Med Res. 2016;11:1-4.
3. Zimmermann, A, Bernuit, D, Gerlinger, C, Schaefer M, Geppert K. Prevalence, symptoms and management of uterine fibroids: an international internet-based survey of 21,746 women. BMC Womens Health. 2012;12:6.
4. Kenichi O, Satoshi N, Osamu N, Masako I, Yasuhiro Y, Goh T, et al. A case of Meigs syndrome with preceding pericardial effusion in advance pleural effusion. BMC Pub Med. 2016;16:71.
5. Cowan M, Crantz J, Welsh S, Nahhas W, Lindheim SR. A rare case of acute Pseudo-Meigs' syndrome presenting with pleural effusion and ascites and a ruptured leiomyoma and hemorrhagic shock. Obstet Gynecol Cases Rev. 2016;3:70.
6. Yonehara Y, Yanazume S, Kamio M, Togami S, Tasaki T, Douchi T. Concentrated ascites re-infusion therapy for pseudo-Meigs' syndrome complicated by massive ascites in large pedunculated uterine leiomyoma. J Obstet Gynaecol Res. 2014;40(7):1944-9.
7. Kurai M, Shiozawa T, Noguchi H, Konishi I. Leiomyoma of the ovary presenting with Meigs' syndrome. J Obstet Gynaecol Res. 2005;31(3):257-62.
8. Marci R, Giugliano E, Carboni S, Martinello R, Patella A. Pseudo-Meigs' syndrome caused by a uterine leiomyosarcoma: a new clinical condition. Gynecol Obstet Invest. 2011;72:68-72.
9. Yamamoto Y, Miyagawa Y, Takehito E. Three cases of Pseudo-Meigs' syndrome secondary to ovarian metastases from colorectal cancer. Case Rep Surg. 2017:Article ID 5235368.
10. Hlasek KK, Shingange SM. Sudden death associated with Meigs syndrome: an autopsy case report. Am J Forensic Med Pathol. 2012;33(1):58-60.

Cite this article as: Dubey S, Goel P, Pandey N, Pavithra HN. Pseudo-Meigs syndrome: a rare presentation of pedunculated fibroid. Int J Reprod Contracept Obstet Gynecol 2020;9:3052-4.