

Original Research Article

Clinical and radiological profile of patients with cerebral venous and sinus thrombosis in a tertiary care hospital

Sudha Vidyasagar, Aasish Peddu, Nandakrishna Bolanthakodi*, Cynthia Amrutha

Department of Medicine, Kasturba Medical College, Manipal Academy of Higher Education, Manipal, India

Received: 11 May 2021

Revised: 06 June 2021

Accepted: 08 June 2021

*Correspondence:

Dr. Nandakrishna Bolanthakodi,
E-mail: nandaksb@gmail.com

Copyright: © the author(s), publisher and licensee Medip Academy. This is an open-access article distributed under the terms of the Creative Commons Attribution Non-Commercial License, which permits unrestricted non-commercial use, distribution, and reproduction in any medium, provided the original work is properly cited.

ABSTRACT

Background: Cerebral venous and sinus thrombosis (CVT) is one of the common causes of stroke in young people. It is a relatively uncommon neurologic disorder that is potentially reversible with prompt diagnosis and appropriate medical care. The purpose of this study is to identify the clinical and radiological features aiding diagnosis of cortical vein thrombosis

Methods: A cross-sectional study was conducted from November 2015 to May 2017 in tertiary care centre in Manipal after institutional ethical clearance. A total of 46 patients diagnosed with CVT were included in the study. Clinical symptoms and signs at admission and radiological features were documented.

Results: A total of 46 subjects were included. Males (53.3%) were more affected than females (46.7%), mostly in the 3rd decade. The most common risk factors were polycythaemia (31.1%) and oral contraceptive pill intake (17.7%). Headache was the most common symptom followed by paralysis and seizures. Multiple sinuses were involved in two-thirds of the patients. Superior sagittal sinus thrombosis was the most common sinus involved followed by transverse sinus thrombosis

Conclusions: The most common clinical feature is headache followed by paresis and seizures. Superior sagittal sinus thrombosis is more common than transverse and sigmoid sinus thrombosis in Indian population. Normal CT scan of brain doesn't rule out cerebral venous sinus thrombosis.

Keywords: Cerebral venous sinus thrombosis, Stroke, CVT

INTRODUCTION

Cerebral venous and sinus thrombosis (CVT) is a type of cerebrovascular disease marked by thrombosis of blood in the cerebral veins, or dural sinuses, and cortical veins. CVT accounts for 0.5 % of all strokes and its annual incidence is estimated to be 3-4 cases per 1 million population. CVT is one of the common causes of stroke in young people, although it may present at any age. Strokes in the young account for nearly 30% of all cases of stroke in India and CVT accounts for 10-20% of these cases. Clinical features at presentation are variable across studies.

Symptoms like headache, seizures, diplopia and hemiparesis may be seen in isolation or combinations.^{1,2}

The mortality is relatively minimal compared with the arterial stroke as most of the patients have a good long-term prognosis.³ Most patients recover completely, or have only mild functional or cognitive deficits. Mortality in majority of the cases occur within few days of presentation and is mainly due to transtentorial herniation of the brain due to edema or haemorrhage. Hence early diagnosis and treatment is valuable.⁴⁻⁵ We conducted this study for better understanding of clinical presentation and radiological profile of patients with CVT.

METHODS

A cross-sectional observational study was conducted at Kasturba Hospital, Manipal from November 2015 to May 2017. Data collection was commenced after obtaining ethical clearance certificate from Kasturba Medical College and Hospital Ethics Committee. Adults aged more than 18 years diagnosed with CVT either by computed tomography scan (CT) or Magnetic resonance imaging (MRI) of the brain were included in the study. Patients with arterial infarcts and arterial malformations and those who developed CVT as a result of diagnostic and therapeutic neurosurgical procedures were excluded from the study.

Information regarding baseline patient characteristics, history pertaining to risk factors of CVT such as intake of oral contraceptive pills were filled in a standard proforma. Laboratory tests such as hemogram, serum homocysteine levels, antinuclear antibody tests and coagulation studies were done to identify the thrombophilic risk factors. Diagnosis of Polycythemia Vera was made based on the WHO 2016 criteria.⁶ Diagnosis of Antiphospholipid syndrome (APS) was made based on the revised Sapporo APS Classification Criteria (also called the Sydney criteria).⁷ Cut off values for raised serum homocysteine levels were taken as >15 mg/100 ml in those below 60 years, and >20 mg/100 ml in those above 60 years of age.⁸

All the patients underwent MRI brain with MR venography. Radiological features like site of venous thrombosis, cerebral edema and infarction were noted. CT scan findings of the patients were also documented. All patients were treated with anticoagulation as per standard guidelines and protocols.

Statistical methods used

Data analysis and interpretation was done with Statistical Package for the Social Sciences (SPSS) version 15.0. Continuous variables like age are expressed as mean±SD. Non continuous variables are described in frequencies.

RESULTS

About 56 patients diagnosed with CVT were considered for screening and enrolment into the study. Of these, 11 patients were excluded based on the exclusion criteria. A total of 45 patients were included in the study. Mean age of the population was 36.13±13.47 years. The demographic profile of the study participants is described in table 1. The most common identified risk factors were polycythemia (31.1%) followed by intake of oral contraceptive pills (17.7%) as shown in table 2.

The most common presenting complaints in our study were headache (86.7 %) and vomiting (48.9 %) followed by weakness of limbs (42.2 %) and seizures (40 %). Frequencies of other symptoms are described in figure 1. Among the 18 patients (40 %) who presented with seizures

in our study, the most common seizures were generalised seizures which were seen in 8 patients followed by focal seizures with secondary generalisation in 5 patients. Two patients had status epilepticus. Two patients (4.4 %) presented with comatose state (GCS of < 8) and 13 patients (28.9%) presented with impairment in consciousness level (GCS of 8-14) while the remaining 30 patients (66.7 %) presented with fully conscious state (GCS of 15) to the hospital in our study.

Table 1: Demographic profile of study participants.

Mean age	36.13±13.47 years (Mean± SD)
Age<40 years	n=31 (68.9%)
Age>40 years	n=14 (31.1%)
No of Males	24 (53.3%)
No of females	21 (46.7%)
Male: female ratio	1.1:1

Table 2: Frequency of different aetiologies for CVT.

Aetiology for CVT	Number of patients, n=45 (percentage)
Polycythaemia	14 (31.1%)
Oral contraceptive pills	8 (17.7%)
Antiphospholipid antibody syndrome	6 (13.3%)
Pregnancy and puerperium	5 (11.1%)
Hyperhomocysteinemia	5 (11.1%)
Infection	4 (8.8%)
Malignancy	2 (4.4%)
Paroxysmal Nocturnal Hemoglobinuria	1 (2.2%)

The most frequent findings on examination in our study were found to be paresis i.e; paralysis of limbs (42.2 %) and upper motor neuron type of facial nerve palsy (28.9 %) followed by papilledema (24.4 %). Dysarthria was present in 8 patients. None of them had aphasia and sensory deficits. Among the 19 patients (42.2 %) with weakness of limbs (paresis) in our study, 11 patients (24.4 %) had hemiparesis, 6 patients (13.3 %) had paraparesis and 2 patients (4.4 %) had quadriparesis.

A total of 34 patients underwent computed tomography scan prior to MRI Brain. Eight patients (23.5%) had normal scan. Nineteen patients (55.8%) had cerebral oedema. Venous thrombosis was visualised in 15 patients (44.11%). All patients underwent MRI brain as per clinician's discretion. The most common dural venous sinus involved in our study was superior sagittal sinus (80%) followed by transverse sinus (64.4%) as shown in figure 2. Cavernous sinus was involved in one patient (2.2 %). More than one venous sinuses were involved in 30 patients (66.7 %) in our study. Among the combination of various venous sinuses involved in our study, the most common was found to be combination of Sagittal, Transverse and Sigmoid sinuses which were involved in

13 patients (28.8%) followed by combination of Sagittal and Transverse sinuses in 6 patients (13.3 %).Six patients (13.3 %) had venous infarction without haemorrhage, 13 patients (28.8 %) had intracerebral haemorrhage, 4

patients (8.9 %) had subarachnoid haemorrhage and 3 patients (6.7 %) had both intracerebral and subarachnoid haemorrhages in our study.

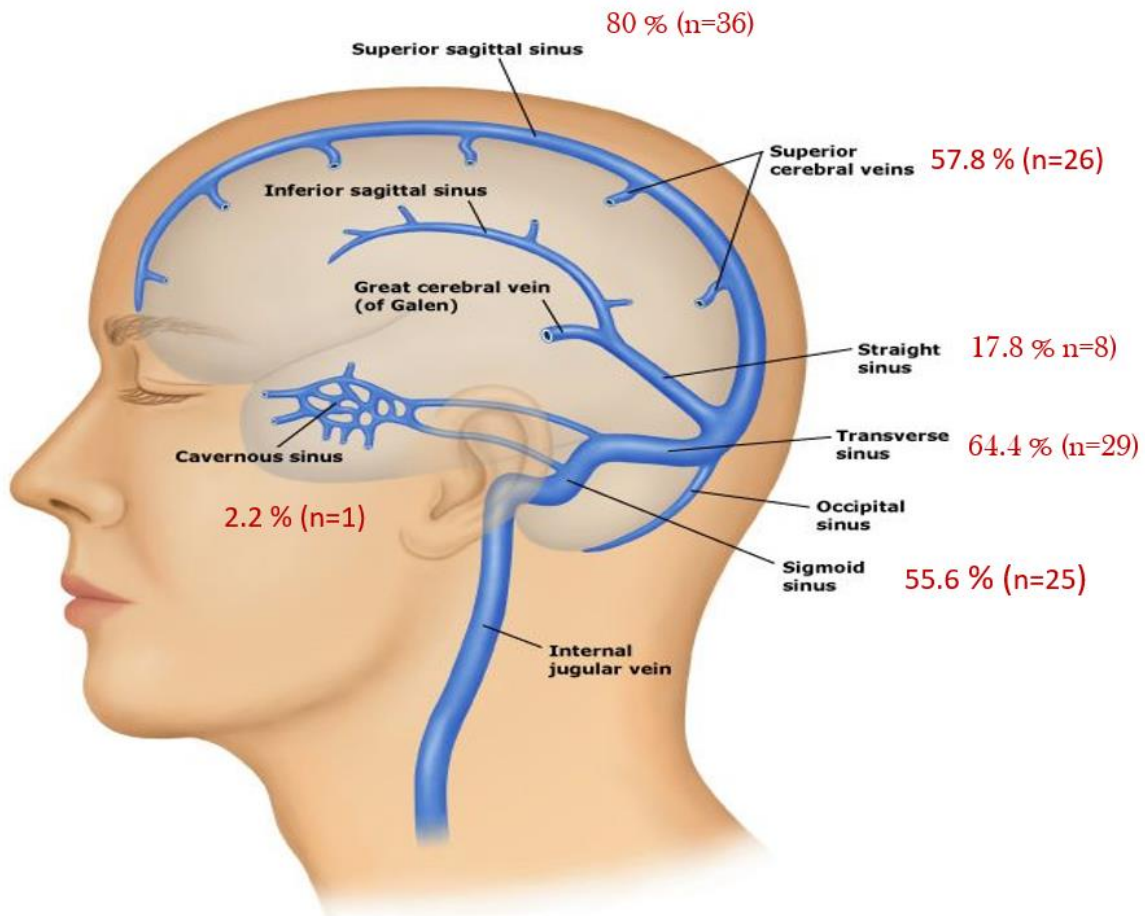
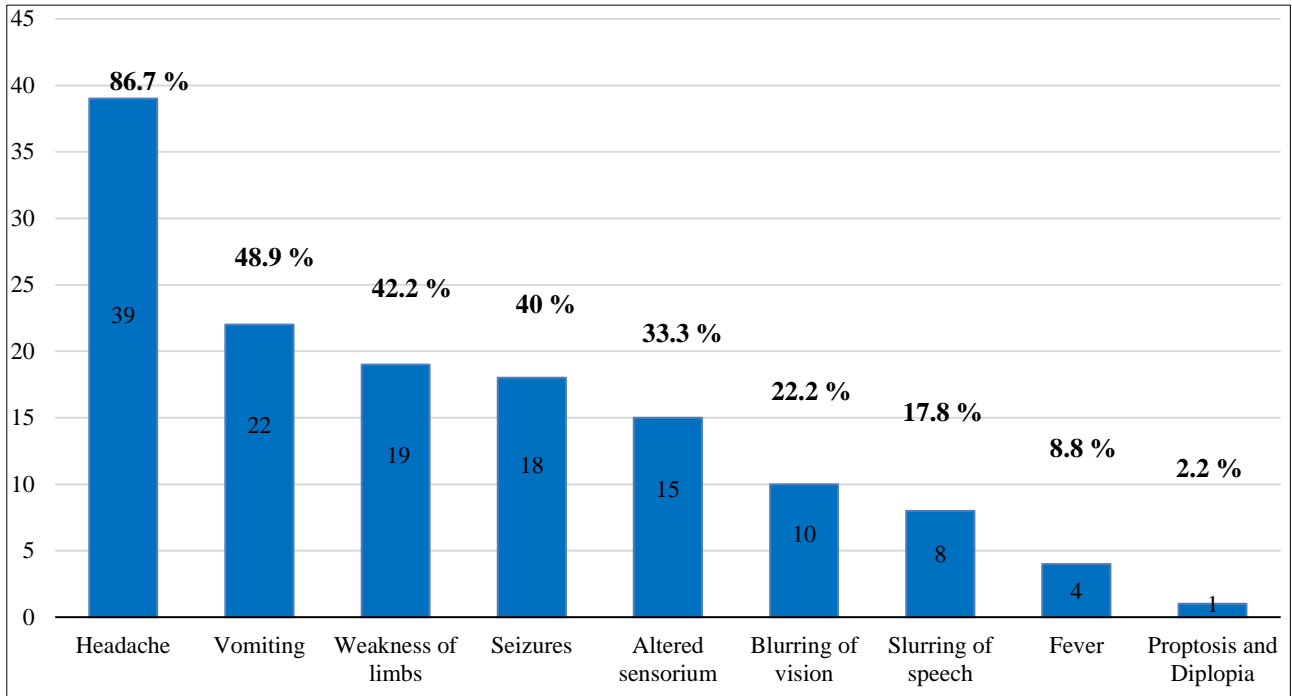


Figure 2: Type of venous sinuses involved in MRI Brain with MR Venography (expressed in numbers and percentages).

DISCUSSION

The most common presenting complaints in our study were headache (86.7%) and vomiting (48.9%) followed by weakness of limbs (42.2%) and seizures (40%). The most frequent findings on examination in our study were found to be paralysis of limbs (42.2%) and upper motor neuron type of facial nerve palsy (28.9%) followed by papilledema (24.4%). None of the patients were found to have aphasia or sensory deficits in our study. Previous studies on CVT by Pai et al and Ferro et al also described headache as commonest symptom in over 80% of cases.^{1,9} Mechanism of this headache was postulated to be due to the stretching of the nerve fibres in the walls of the occluded sinuses and local inflammation, as well as due to cerebral oedema and associated intracerebral haemorrhage.

Focal neurological deficits may occur depending on the area involved, hemiparesis may be encountered, and in some cases of sagittal sinus thrombosis, there is involvement of bilateral lower extremities. It is mainly due to the oedema occurring in the motor area of the cortex leading to weakness of limbs. Among the 19 patients (42.2 %) with weakness of limbs (paresis) in our study, 11 patients (24.4 %) had hemiparesis, 6 patients (13.3 %) had paraparesis and 2 patients (4.4 %) had quadriparesis. Twelve (63.5%) out of 19 patients with paralysis of limbs had GCS <15 at onset in our study. Eight (42.5%) out of 19 patients with paralysis of limbs had seizures in our study. 16 (84.2%) out of 19 patients with paralysis of limbs had superior sagittal sinus involvement whereas transverse sinus involvement was seen in 11 patients (57.8%). Six (31.6%) out of 19 patients with paralysis of limbs had venous infarction without haemorrhage whereas haemorrhagic infarction was seen in 13 patients (68.4%).

Among the 18 patients (40%) who presented with seizures in our study, the most common seizures were generalised seizures which were seen in 8 patients (17.7%) followed by focal seizures with secondary generalisation in 5 patients (11.1%). Focal seizures without generalisation were seen in 3 patients (6.6%) and status epilepticus was seen in 2 patients (4.4%). In comparison to the ISCVT (International Study on Cerebral Vein and Dural Sinus Thrombosis) done by Ferro et al which showed that 9.3% had focal seizures without generalization, 19.7% had generalized seizures from onset, and the remaining 10.3% had both the types.¹

Seizures are in general, most commonly seen in patients with superior sagittal sinus thrombosis or cortical vein thrombosis due to involvement of cortical gray matter. 15 (83.3%) out of 18 patients with seizures had superior sagittal sinus involvement, 12 patients (66.7%) had cortical vein thrombosis and transverse sinus involvement was seen in 10 patients (55.5%). Frequency of seizures in our study was almost similar to other studies stated above. Frequency of papilloedema in our study was lower in

comparison to the other studies and the reason could be due to larger sample size of other studies when compared to our study

About 75.5% (N=34) patients underwent CT scan of brain prior to MRI brain. Eight patients (23.5%) had normal CT scan. All patients in our study underwent MRI brain with MR venography and found that the most common dural venous sinus involved was superior sagittal sinus (80%) followed by transverse sinus (64.4%). Studies in Indian population have shown predominant involvement of superior sagittal sinus whereas study by Walecki et al showed predominant involvement of transverse and sigmoid sinus.^{10-12,14} A study by Matias et al from Argentina found that transverse sinus was commonly affected by CVT followed by sigmoid sinus. Reason behind this anatomical difference in venous sinus involvement is unclear. More than one venous sinuses were involved in 30 patients (66.7 %) in our study similar to other studies. Among the combination of various venous sinuses involved in our study, the most common was found to be combination of Sagittal, Transverse and Sigmoid sinuses which were involved in 13 patients (28.8%) followed by combination of Sagittal and Transverse sinuses in 6 patients (13.3 %).^{15,16}

Altered sensorium was most commonly seen in cortical vein thrombosis (42.3% i.e; 11 out of 26 patients with cortical vein involvement) followed by superior sagittal sinus thrombosis (36.1% i.e; 13 out of 36 patients with superior sagittal sinus thrombosis). Only 27.5% patients with transverse sinus involvement had altered sensorium at onset. 6 patients (13.3%) had venous infarction without haemorrhage, 13 patients (28.8%) had intracerebral haemorrhage, 4 patients (8.9%) had subarachnoid haemorrhage and 3 patients (6.7%) had both intracerebral and subarachnoid haemorrhages in our study. Cerebral oedema was seen in 14 patients (31.1%) in our study.⁷ (53.8%) out of 13 patients with intracerebral haemorrhage had seizures whereas 2 (33.3%) out of 6 patients with venous infarction without haemorrhage had seizures. This shows that seizures were most commonly seen in haemorrhagic infarction when compared to venous infarction without haemorrhage.⁹ (69.2%) out of 13 patients with intracerebral haemorrhage had altered sensorium at onset whereas 3 (50%) out of 6 patients with venous infarction without haemorrhage had altered sensorium at onset. This shows that altered sensorium at onset was most commonly seen in haemorrhagic infarction when compared to venous infarction without haemorrhage.

In our study, haemorrhagic infarction was most common than venous infarction without haemorrhage which was similar to the observation made from other Indian study by Thota Naveen et al. However western studies such as Walecki et al and Ferro et al have shown that venous infarction without haemorrhage was most common when compared to haemorrhagic infarction.^{13,14}

Limitations of the study

Our study findings are limited by the sample size. Hence robust studies are required in future to confirm the findings. Extensive etiological workup was not possible in all study participants in view of financial constraints. Clinical findings like fundus examination were limited in few patients during presentation because of severity of illness.

CONCLUSION

Cerebral venous sinus thrombosis presents with headache as predominant symptom. Focal neurological deficits associated with infarction or haemorrhage are common with superior sagittal sinus involvement. Superior sagittal sinus is commonly involved followed by transverse sinus involvement. Normal CT scan of the brain doesn't rule out CVT.

Funding: No funding sources

Conflict of interest: None declared

Ethical approval: The study was approved by the Institutional Ethics Committee

REFERENCES

1. Ferro JM, Canhao P, Stam J. Prognosis of cerebral vein and dural sinus thrombosis: results of the International Study on Cerebral Vein and Dural Sinus Thrombosis (ISCVT). *Stroke*. 2004;35:664.
2. Dash D, Prasad K, Joseph L. Cerebral venous thrombosis: An Indian perspective. *Neurol India*. 2015;63:318-28.
3. Ferro JM, Lopes MG, Rosas MJ, Ferro MA, Fontes J. Cerebral venous Thrombosis-Portuguese collaborative study group (VENOPORT): long-term prognosis of cerebral vein and dural sinus thrombosis: results of the VENOPORT study. *Cerebrovasc Dis*. 2002;13:272-8.
4. de Bruijn SFTM, de Haan RJ, J Stam. Clinical features and prognostic factors of cerebral venous sinus thrombosis in a prospective series of 59 patients. *J Neurol Neurosurg Psychiatry*. 2001;70:105-8.
5. Hameed B, Syed NA. Prognostic indicators in cerebral venous sinus thrombosis. *J Pak Med Assoc*. 2006;56(11):551-4.
6. Arber DA, Orazi A, Hasserjian R. The 2016 revision to the World Health Organization classification of myeloid neoplasms and acute leukemia. *Blood*. 2016;127:2391.
7. Bobba RS, Johnson SR, Davis AM. A review of the sapporo and revised Sapporo criteria for the classification of antiphospholipid syndrome. Where do the revised sapporo criteria add value? *J Rheumatol*. 2007;34:1522.
8. Ueland PM, Refsum H, Stabler SP, Malinow R, Andersson A, Allen RH. Total homocysteine in plasma or serum: Methods and clinical applications. *Clin Chem*. 1993;39:1764-79.
9. Pai N, Ghosh K, Shetty S. Hereditary thrombophilia in cerebral venous thrombosis: A study from India. *Blood Coagul Fibrinolysis*. 2013;24:540-3.
10. Narayan D, Kaul S, Ravishankar K, Suryaprabha T, Bandaru VC, Mridula KR, et al. Risk factors, clinical profile, and long term outcome of 428 patients of cerebral sinus venous thrombosis: Insights from Nizam's Institute Venous Stroke Registry, Hyderabad (India). *Neurol India*. 2012;60:154-9.
11. Wassay M, Bakshi R, Bobustuc G, Kojan S, Sheikh Z, Dai A, et al. Cerebral venous thrombosis: Analysis of a multicenter cohort from the United States. *J Stroke Cerebrovasc Dis*. 2008;17:49-54.
12. Patil VC, Choraria K, Desai N, Agrawal S. Clinical profile and outcome of cerebral venous sinus thrombosis at tertiary care center. *J Neurosci Rural Pract*. 2014;5:218-24.
13. Naveen T, Krishna GR, Vengamma B, Dayakar D, Dushyanth J. Clinical Manifestations, Radiological Findings and Outcome in Cerebral Vein and Dural Sinus Thrombosis: A Prospective Study. *J Evid based Med Healthc*. 2015;2(39):6171-81.
14. Walecki J, Mruk B, Nawrocka-Laskus E. Neuroimaging of Cerebral Venous Thrombosis (CVT) Old Dilemma and the New Diagnostic Methods. *Polish Journal of Radiology*. 2015;80:368.
15. Alet M, Ciardi C, Alemán A, Bando L, Bonardo P, Cea C, Cirio J. Argentinian Stroke and Cerebrovascular Diseases Study Group - Argentine Neurological Society. Cerebral venous thrombosis in Argentina: clinical presentation, predisposing factors, outcomes and literature review. *J Stroke Cerebrovasc Dis*. 2020;29(10):105145.
16. Dhadke VN, Dhadke SV, Kulkarni A. Clinical Profile of Cerebral Venous Sinus Thrombosis. *J Assoc Physicians India*. 2020;68(3):33-5.

Cite this article as: Vidyasagar S, Peddu A, Bolanthakodi N, Amrutha C. Clinical and radiological profile of patients with cerebral venous and sinus thrombosis in a tertiary care hospital. *Int J Res Med Sci* 2021;9:1955-9.