

## Case Report

# Giant retroperitoneal liposarcoma: report of a rare case

Subrata Pal\*, Sanjay Sengupta, Biplab Kr Biswas, Sritanu Jana

Department of Pathology, Bankura Sammilani Medical College, Bankura, West Bengal, India

**Received:** 25 May 2013

**Accepted:** 14 June 2013

**\*Correspondence:**

Dr. Subrata Pal,

E-mail: subratapal1985@gmail.com

© 2013 Pal S et al. This is an open-access article distributed under the terms of the Creative Commons Attribution Non-Commercial License, which permits unrestricted non-commercial use, distribution, and reproduction in any medium, provided the original work is properly cited.

### ABSTRACT

Retroperitoneal liposarcoma is an uncommon malignant mesenchymal tumour of adipocytic differentiation. Giant retroperitoneal liposarcoma is a rare entity which achieves such a large tumour bulk without any significant clinical symptoms due to deep seated location of the tumour. Though incidence of distant metastasis is less but local recurrence is fairly common. Surgical management is the key of management in retroperitoneal liposarcoma in spite of its large size and local invasion to vital organs. We are reporting a case of giant retroperitoneal liposarcoma of 27.5 Kg in a 45 year old female patient.

**Keywords:** Retroperitonium, Liposarcoma, Giant size

### INTRODUCTION

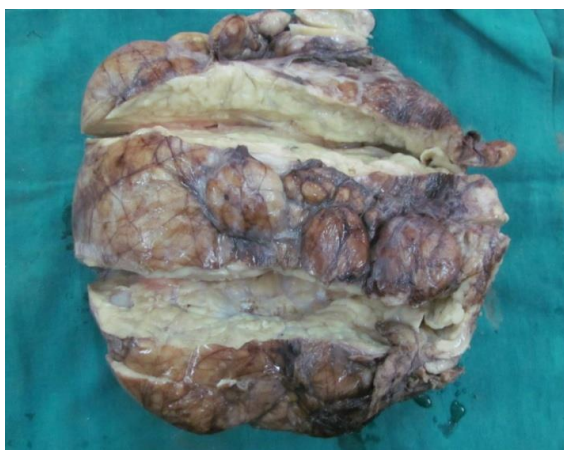Liposarcoma is a malignant mesenchymal tumour of adipocytic differentiation.<sup>1</sup> It is the most frequent histological type of retroperitoneal sarcoma constituting 41% of all retroperitoneal sarcomas.<sup>2</sup> Liposarcomas commonly occur in elderly age (50-70 year) with a slight predilection to male sex<sup>3</sup>. According to descending order, liposarcomas are distributed in retroperitonium (42%), lower extremities (41%) favouring thigh, upper extremities (11%) and head-neck region (6%).<sup>3</sup> On the basis of histomorphology, liposarcomas are classified into five categories – myxoid, round cell, well differentiated, pleomorphic and dedifferentiated liposarcomas. Retroperitoneal liposarcomas often show an expansive growth without any symptom due to deep location of the tumours<sup>3</sup>. But giant retroperitoneal liposarcoma is a rare entity. Till now only few cases have been reported in English literature. Clinical presentation is often late and it involves slow enlargement of abdominal girth, palpable abdominal mass, diffuse abdominal pain with anorexia and weight loss. Surgical resection is the gold standard management even in case of very large tumour or involvement of surrounding vital

organs. Local recurrence is common but metastasizing potentiality is very low. We are reporting such an interesting case of giant retroperitoneal liposarcoma in an elderly woman.

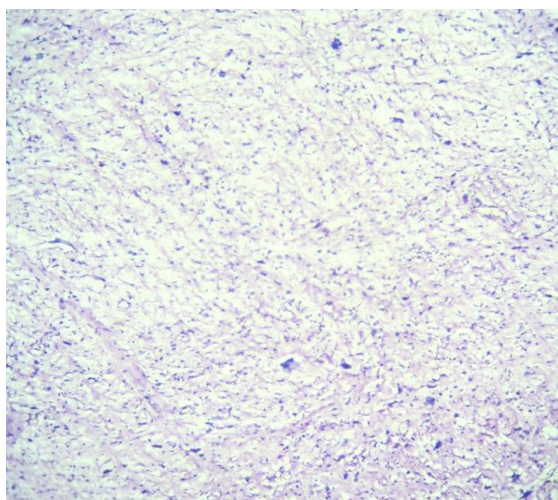
### CASE REPORT

A 45 year old female patient was admitted to surgery ward with diffuse abdominal pain for 3 days and chest tightness. She had given history of increased abdominal girth with loss of weight and anorexia for last 8 months. On examination, she had poor nutritional status and moderate pallor. Abdominal examination revealed huge distension, mild tenderness and fullness of flanks. A huge mass was palpable approximately (25×20) cm, occupying left lumbar region, left iliac fossa, umbilical region and extending up to right lumbar region. Other systemic examinations were within normal limit. Her laboratory investigations were unremarkable except haemoglobin level (9.9gm %). Blood biochemical profile was normal. On ultrasonography, it was a heterogeneous; hugely enlarged mass displacing adjacent bowel loops, stomach and left kidney. The diaphragm was pushed upward and left kidney showed mild hydronephrotic changes.

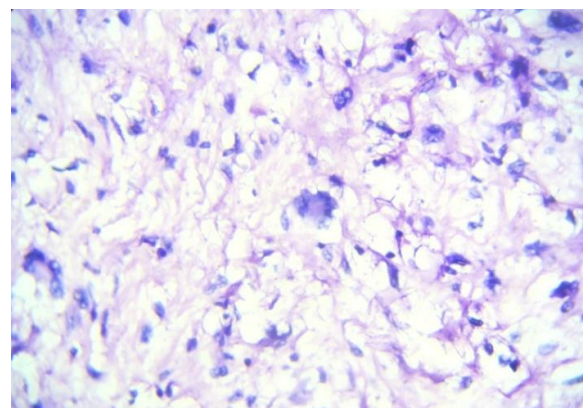
Exploratory laparotomy was done under general anaesthesia. On laparotomy, it revealed a huge fatty mass involving almost the whole abdominal cavity and encroaching to pelvic cavity. Surprisingly no visceral involvement was noted during surgery. The entire tumour mass was resected and sent for histopathological examination. She responded well to post-operative care and after 6 month follow up she was free from any recurrence. On gross examination, it was a well circumscribed large soft tumour mass measuring (30×26×20) cm in size and weighting 27.5kg (Figure 1). Cut surface of the tumour was yellowish fatty and radiating fibrous septa were found at central portion. No area of haemorrhage and necrosis was seen in the tumour mass. Microscopy from different parts of the tumour show admixture of large round shaped adipocytes, spindle cells and large pleomorphic multinucleated giant cells having bizarre, hyperchromatic, scalloped nuclei and perinuclear vacuolated cytoplasm (pleomorphic lipoblasts) (Figure 2 & 3). Histopathological diagnosis of pleomorphic liposarcoma was made.



**Figure 1: Gross picture of the retroperitoneal mass.**



**Figure 2: Microscopy of retroperitoneal liposarcoma (Low power view, H & E stain).**



**Figure 3: Microscopic picture of giant retroperitoneal liposarcoma (High power view, H & E stain).**

## DISCUSSION

Liposarcomas are malignant mesenchymal tumour with a great predilection to retroperitoneal space. They constitute 41% of all retroperitoneal sarcomas.<sup>3</sup> Liposarcomas are slightly more common in male with age distribution of 50-70 years.<sup>4,5</sup> Histological subtypes of liposarcoma are myxoid, well differentiated, round cell, pleomorphic and dedifferentiated type.<sup>1,6</sup> Myxoid liposarcoma is commonest type of liposarcoma but it is unlikely to occur at retroperitoneal space.<sup>1</sup> Well differentiated liposarcomas are the most frequent subtype encountered at retroperitoneum.<sup>7,8</sup> Due to deep location, the tumour is often asymptomatic before reaching to a large size.<sup>2,3</sup> Approximately 20% of retroperitoneal liposarcomas are >10cm in size at the time of diagnosis.<sup>2</sup> But giant retroperitoneal liposarcomas are very rare malignancy. Till now largest retroperitoneal liposarcoma was reported to be 42kg by Yol S et al.<sup>9</sup> Non-specific abdominal pain and discomfort or a palpable abdominal mass with increased abdominal girth is the common presentation accompanying with anorexia, cachexia. The symptoms are often due to compression of adjacent structures (organs) by the enlarged tumour mass. Retroperitoneal liposarcoma have very less potential due to metastasis to distant site (7% Vs 15-34% in other sarcomas).<sup>3</sup> But loco-regional recurrence is very common, particularly in case of incomplete removal of primary tumour due involvement of vital organs.<sup>2</sup> Many previous reviewers concluded that complete surgical removal of the tumour mass is the key of management and further disease free survival.<sup>3,8,10</sup> Sometimes complete resection may needs removal of involving organs like kidney, adrenal, colon, small intestine and pancreas.<sup>3,5,10</sup> In our patient, no vital organ was removed in spite of large size of the tumour mass. Few literatures suggested post-operative radiation therapy may improve survival but it is controversial.<sup>3,5</sup> In giant retroperitoneal liposarcoma, required radiation dose to get desired tumorocidal effect may lead to substantial morbidity.<sup>3,5</sup> Role of chemotherapy in the treatment of retroperitoneal liposarcoma is disappointing.<sup>3,10</sup> Prognosis of retroperitoneal liposarcomas depends on completeness of

resection, histological subtype, differentiation and location of the tumour but not on the tumour size.<sup>2,3,8,10</sup> Overall 5 years survival rate varies from 90% in well differentiated tumour to less than 20% in high grade (pleomorphic, dedifferentiated subtype) retroperitoneal liposarcoma.<sup>3,5</sup>

## CONCLUSION

Giant retroperitoneal liposarcoma is a rare entity but diagnostically important due to its wide histological variation and delayed presentation in spite of large size. Early diagnosis and complete surgical resection is the cornerstone of management. Till now prognosis is unfavourable due to local recurrence. This tumour, reported by us is one of the largest retroperitoneal liposarcoma diagnosed in Indian subcontinent.

## REFERENCE

1. Mohammad Reza A, M Omranifard. Huge retroperitoneal liposarcoma. *JRMS* 2011;16(4): 565-7.
2. Navdeep S Saini, RKapoor. Giant Retroperitoneal Liposarcoma. *JK Science* 2012;14(1):51-3.
3. Selmani R, Begovic G, Janevski V, Rushiti Q, Karpuzi A. Giant Retroperitoneal Liposarcoma: A case report. *Sec. Biol. Med. Sci* 2011;32(1):323-32.
4. Chavan S, Parasnis A, Punia P and Tekade S. Giant Retroperitoneal Liposarcoma: A Case Report. *Case Rep Oncol Med* 2012;2012:869409.
5. Pedro Leão, SóniaVilaça, Mário Oliveira, and JoaquimFalcão. Giant recurrent retroperitoneal liposarcoma initially presenting as inguinal hernia: Review of literature. *Int J Surg Case Rep* 2012;3(3):103-6.
6. Murphey MD. World Health Organization classification of bone and soft tissue tumors: modifications and implications for radiologists. *Semin Musculoskelet Radiol* 2007;11(3):201-14.
7. Linehan DC, Lewis JJ, Leung D, et al. Influence of biologic factors and anatomic site in completely resected liposarcoma. *J Clin Oncol* 2000;18:1637-43.
8. Yi Gan, Jun Z, Tie-Q Lai, Jun-H Wu and Chang-Qing Gao. Giant retroperitoneal liposarcoma. *JRSM Short Rep* 2012;3:9.
9. Yol S, Tavli S, Tavli L, Belviranli M, Yosunkaya A. Retroperitoneal and scrotal giant liposarcoma: report of a case. *Surg Today* 1998;28:339-42.
10. Nfifakh A, Bouabdallah Z. Giant retroperitoneal Liposarcoma. *Webmed Central Urology* 2012; 3(6):WMC003503.

DOI: 10.5455/2320-6012.ijrms20130832

**Cite this article as:** Pal S, Sengupta S, Biswas BK, Jana S. Giant retroperitoneal liposarcoma: report of a rare case. *Int J Res Med Sci* 2013;1:301-3.