

## Original Research Article

# Diagnostic usefulness of transtracheal aspiration in lower respiratory tract infections

Aroop Mohanty<sup>1\*</sup>, Ankita Kabi<sup>2</sup>, Ambika Prasad Mohanty<sup>3</sup>, Pratima Gupta<sup>1</sup>, Priyanka Gupta<sup>1</sup>

<sup>1</sup>Department of Microbiology, <sup>2</sup>Department of Anaesthesia, All India Institute of Medical Sciences, Rishikesh, Uttarakhand, India

<sup>3</sup>Department of Medicine, Kalinga Institute of Medical Sciences, Bhubaneswar, Odisha, India

**Received:** 26 October 2017

**Accepted:** 30 October 2017

### \*Correspondence:

Dr. Aroop Mohanty,

E-mail: aroopmohanty7785@yahoo.com

**Copyright:** © the author(s), publisher and licensee Medip Academy. This is an open-access article distributed under the terms of the Creative Commons Attribution Non-Commercial License, which permits unrestricted non-commercial use, distribution, and reproduction in any medium, provided the original work is properly cited.

## ABSTRACT

**Background:** The incidence of pulmonary infections is on a constant rise. The present study was undertaken in order to identify those patients in whom transtracheal aspiration is most likely to provide information not obtainable from evaluation of expectorated sputum and delineates the clinical conditions under which transtracheal aspiration is indicated.

**Methods:** A total of 50 patients of lower respiratory tract infections were studied. Both sputum and trans-tracheal aspirate samples were compared by Gram's stain and culture methods.

**Results:** Gram's staining of the sputum was non-helpful in most cases as it showed mixed organisms while trans-tracheal aspiration showed only single type of colony. Culture showed less growth in sputum samples as compared to trans-tracheal aspirates.

**Conclusions:** Trans-tracheal aspirate appears to be a very good method for isolating infective agents in lower respiratory tract infections. Besides by passing the contaminants of the oropharynx, it pinpoints the organism in most cases.

**Keywords:** Trans-tracheal aspirate, Lower respiratory tract infections

## INTRODUCTION

Should trans-tracheal aspiration replace the bedside sputum cup for obtaining specimens for bacteriological examination in lower respiratory tract infection? Present incidence of pulmonary infection with gram-negative bacilli and other unusual pathogens is on a rise and because expectorated sputum is contaminated by mouth flora, it is not always a reliable indicator of the organisms present in the lower respiratory tract.<sup>1-5</sup> Furthermore, in some cases the flora of the upper tract secretions may falsely indicate a pulmonary pathogen or may overgrow the actual pathogen. Attempts have been made to avoid the problem of contamination by the oropharyngeal secretions by sampling the lower respiratory tract through a bronchoscope, trans-tracheal aspiration, and

transthoracic lung aspiration. However, in collecting secretions through a bronchoscope it is impossible to avoid contamination of the bronchoscope by the large number of organisms in the oropharynx. An additional objection to obtain specimen through a bronchoscope is the bactericidal effect of the local anesthetic.

Since the antimicrobial therapies are specific, a number of invasive procedures have recently been popularized in an attempt to achieve a rapid and precise bacteriologic diagnosis of the patients with lower respiratory tract infections. Of late, transtracheal aspiration has found increasing use in identifying the cause of pneumonia since cultures obtained by this method more accurately reflect the bacterial flora of an infection of the lower respiratory tract than expectorated sputum.<sup>6-10</sup> Besides

being simple and safe it does not require any sophisticated equipments and can be carried out at the bedside of a patient. The present study was undertaken in order to identify those patients in whom transtracheal aspiration is most likely to provide information not obtainable from evaluation of expectorated sputum and delineates the clinical conditions under which transtracheal aspiration is indicated.

**METHODS**

***Patient population***

Fifty consecutive cases of lower respiratory tract infections admitted in a tertiary care hospital were taken up for the study. Detailed history was taken, and physical examination carried out to arrive at the clinical diagnosis of lower respiratory tract infections, to delineate any other co-existing diseases and to find out any pre-disposing conditions. Other investigations included were complete blood count, bleeding time, clotting time, prothrombin time. Patients presenting with fever, cough with expectoration, chest pain along with radiological signs of consolidation, cavitation or bronchiectasis and no antibiotic therapy within the previous 4 weeks were included in this study. Patients suspected with pulmonary tuberculosis, chronic bronchitis, clinical or laboratory evidence of a bleeding disorder or presenting with haemoptysis were excluded from the study.

***Sputum collection***

Sputum samples were collected before and just after the procedure of transtracheal aspiration. Before collection the patients were given sterile isotonic saline to clean the mouth in order to reduce the contamination of the sputum by the oropharyngeal flora. Patients were instructed to bring out the sputum after a deep cough. This was directly expectorated in a sterile screw capped bottle. The sputum was taken to the laboratory immediately along with the tracheal aspirate.

***Transtracheal aspiration***

A small pillow was placed beneath the supine patient’s shoulders to hyperextend the neck. The anterior aspect of the neck was prepared with an antiseptic and draped with sterile towels. A small cutaneous wheal of 1.0% procaine was made approximately 1cm below the cricoid cartilage in the midline. A sharp 15gauge needle was then inserted through the skin with a twisting motion. The trachea was punctured between the cartilaginous rings, the bevel and point of the needle being directed caudally. A 6-inch length of vinyl tubing sterilized by autoclaving, was inserted into the trachea through the needle, which was withdrawn. A sterile 10-ml syringe was attached to the external end of the tubing by means of a 20-gauge needle. The patient was encouraged to cough as suction was applied to the tube by the syringe. If secretions were not obtained approximately 2-3ml of 0.9% sterile saline

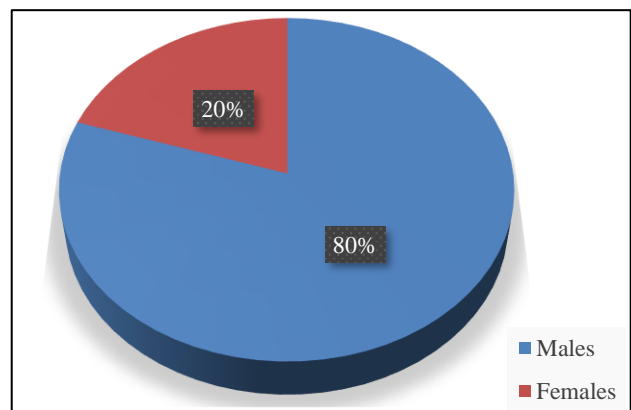
solution was rapidly injected through the tube and suction was again immediately applied when the patient while the patient was encouraged to cough. To obtain the best results this had to be done in one continuous rapid motion. Those cases where manual aspiration through the syringe does not bring secretions a suction machine is applied to suck the secretions. The material thus obtained was discharged into a sterile tube. The patient also was asked to cough out sputum simultaneously through the mouth and the sputum is collected in another tube. After this the needle is withdrawn and pressure is applied at the puncture site for 5-10 minutes to avoid hematoma and subcutaneous emphysema. These patients were kept under observation for at least 24 hours for any evidence of arrhythmias.

***Bacteriological examination***

The sample thus obtained and collected was taken to the laboratory immediately after the procedure. Both the samples obtained by trans-tracheal aspiration and the expectorated sputum were examined by gram’s, AFB stain, followed by culture. The expectorated sputum and the tracheal aspirate were cultured both for aerobic and anaerobic culture. The samples were inoculated on blood, chocolate and MacConkey agar under increased carbon dioxide tension. These were incubated at 37°C aerobically for 24 hours. The plates were examined for colony characters, haemolysis on blood agar and lactose fermentation in MacConkey agar. Gram’s stain was made from the portion of the colony and examined. Further identification of the various organisms was done by routine bacteriological techniques.

**RESULTS**

Fifty consecutive cases of lower respiratory tract infections were taken up during the study period. Majority of them were males (80%) and belonged to the age group of 21- 40 years (60%) (Figure 1). Thirty-five patients had clinico-radiological evidence of pneumonia, nine presented as bronchiectasis, four with lung abscess and rest two had emphysema with bronchopleural fistula (Figure 2).



**Figure 1: Sex-wise distribution of total cases.**

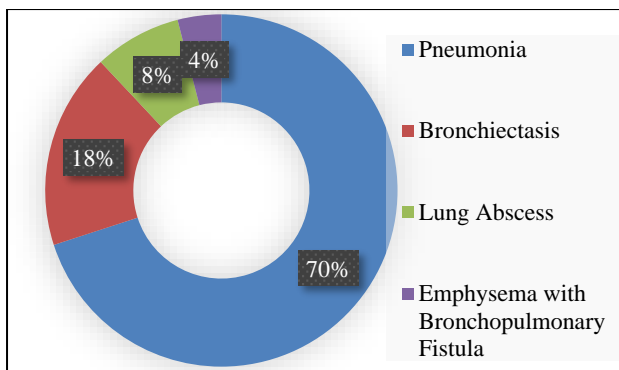


Figure 2: Clinical spectrum of cases.

Most of these cases were community acquired who were primarily admitted for lower respiratory tract infections. Three patients had painful dry cough due to pneumonia at the time of trans-tracheal procedure and hence the expectorated sputum was not available for comparison. Gram’s stain was positive in 85% (40/47) of cases who could expectorate sputum whereas it was positive only in 64% (32/50) in cases of trans-tracheal aspirate samples.

Mixed bacteria were seen on gram’s stain in 49% (23/47) of expectorated sputum samples whereas on the contrary trans-tracheal aspirate samples revealed only single type (32/50) of bacteria (Figure 3).

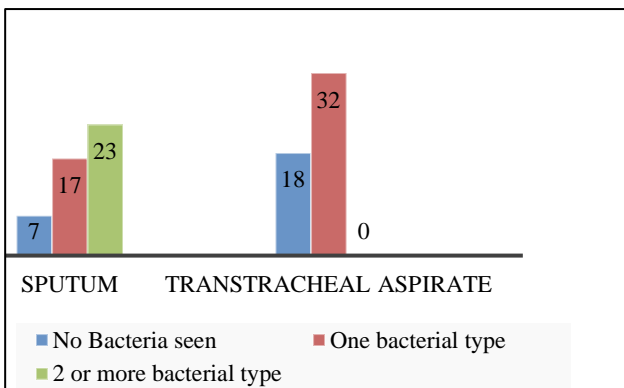


Figure 3: Comparison of Gram’s stain between sputum and trans-tracheal aspirate.

Positive sputum cultures were obtained in 57% (27/47) of expectorated sputum subjected for aerobic culture out of which 17 had single bacterial type whereas 10 had more than one organism.

This was in contrast to the trans-tracheal aspirate culture where 72% (36/50) were culture positive and in each case the growth was of single bacterial type (Figure 4).

*Streptococcus pneumoniae* was the predominant organism (9/27) in the sputum culture positive cases. 4% of cases had β-haemolytic streptococcus but the corresponding trans-tracheal aspirates were sterile (Figure 5).

Mixed growth was obtained in 10 of the sputum samples whereas no such growth was seen in the trans-tracheal cultures implicating the contamination of the expectorated sputum samples by the commensals of the oropharynx. 10 cases showed growth of similar organisms in both the types of samples. Mild and self-limiting haemoptysis occurred in a total of 5 cases, which consisted of streaks of blood along with the sputum. One case developed mild subcutaneous emphysema localized to the neck despite adequate local compression. There was no other complication observed and no fatality observed as a result of this procedure.

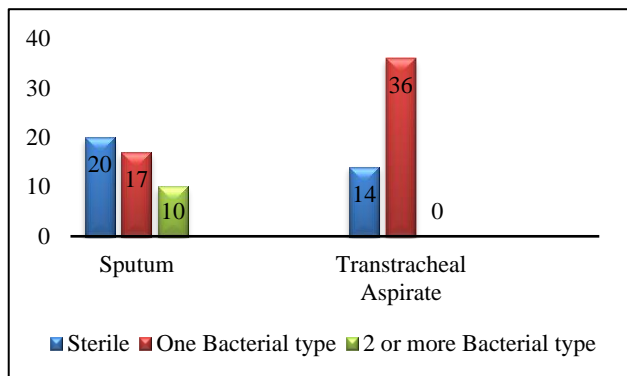


Figure 4: Comparison of culture between sputum and trans-tracheal aspirate.

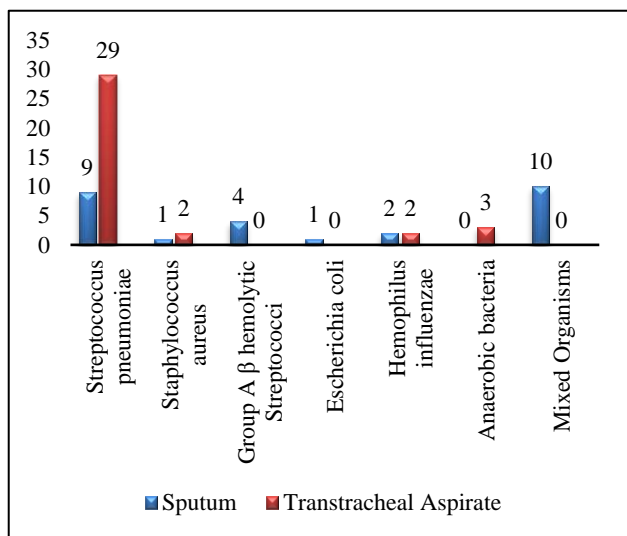


Figure 5: Distribution of bacterial strains in positive cultures.

DISCUSSION

In infections of the lower respiratory tract, bacteriologic examination of the sputum is a common method, but the results obtained by this method are difficult to evaluate. Firstly, the sputum may be heavily contaminated with micro-organisms from the oral cavity and pharynx. Secondly, the pathogens may be irregularly distributed in the sputum necessitating homogenization of the sputum

sample. Lastly, a considerable amount of the sputum specimens merely consists of saliva and therefore lacks any diagnostic significance. In our bacteriology laboratories examination of these important specimens takes a disproportionate amount of time. Trans-tracheal aspirate has been perceived as a safe and reliable diagnostic modality for sampling lower respiratory tract infections and with major implications for therapy.<sup>9</sup>

In our study, cultures of trans-tracheal aspirates produced a higher yield of pulmonary pathogens from patients with lower respiratory tract infections than did cultures of expectorated sputum. In addition, trans-tracheal aspirates contained fewer varieties of bacteria and were seldom contaminated by *staphylococci* and gram-negative *bacilli*. Gram's stains of specimen obtained by trans-tracheal aspiration correlated more closely with the results of cultures than did gram's stain of expectorated sputum. This was a useful feature of this technique when used in patients with lower respiratory tract infections, because it allowed early and more confident selection of an appropriate antibiotic. Some studies have also compared trans-tracheal aspirate with that of bronchoscopy evaluation. Besides being uncomfortable and cannot be prescribed repeatedly, the contamination by oropharyngeal secretions is not eliminated since the tip of the bronchoscope may carry them to the bronchial mucosa.

It also has been difficult to eliminate the bactericidal effect from the use of the anaesthetics. The procedure is probably most helpful in patients who are severely ill and unable to raise sputum spontaneously. It is also likely to be useful in patients who can produce sputum but have complicating conditions that predispose to pulmonary infections with unusual organisms. If gram-negative bacilli or gram-positive cocci in clusters are present in large numbers on the gram stain of the expectorated sputum from such patients, a trans-tracheal aspiration may be helpful. The procedure is probably not indicated in the evaluation of previously healthy individuals with uncomplicated pneumonia.

## CONCLUSION

Morphometric features of transverse and sigmoid sinus with other superficial landmarks is essential during posterolateral approaches to the posterior cranial fossa. The measurements of asterion with other bony landmarks

provide database for the clinical-surgical practice and also for forensic and anthropological application.

*Funding: No funding sources*

*Conflict of interest: None declared*

*Ethical approval: The study was approved by the Institutional Ethics Committee*

## REFERENCES

1. Lerner AM, Tillotson JR. Pneumonias caused by gram-negative bacilli. Michigan medicine. 1968;67(1):35-8.
2. Pierce AK, Edmonson EB, McGee G, Ketchersid J, Loudon RG, Sanford JP. An Analysis of Factors Predisposing to Gram-Negative Bacillary Necrotizing Pneumonia 1, 2. Ame Rev Res Dis. 1966;94(3):309-15.
3. Brumfitt W. An evaluation of sputum examination in chronic bronchitics. Lancet. 1957;2:1306-9.
4. Lees AW, McNaught W. Bacteriology of lower-respiratorytract secretions, sputum, and upper-respiratory-tract secretions in. Lancet. 1959;274(7112):1112-5.
5. Laurenzi GA, Potter RT, Kass EH: Bacteriologic flora of the lower respiratory tract. New Eng J Med. 1961;265:1273-8.
6. Pecora DV. A comparison of transtracheal aspiration with other methods of determining the bacterial flora of the lower respiratory tract. N Eng J Med. 1963;269:664-6.
7. Kalinske RW, Parker RH, Brandt D, Hoepflich PD. Diagnostic usefulness and safety of transtracheal aspiration. N Eng J Medic. 1967;276(11):604-8.
8. Hahn HH, Beaty HN. Transtracheal aspiration in the evaluation of patients with pneumonia. Ann Intern Med. 1970;72:183-8.
9. Ries K, Levison ME, Kaye D. Transtracheal aspiration in pulmonary infection. Arch Intern Med. 1974;133:453-58.
10. Bartlett JG. Diagnostic accuracy of transtracheal aspiration bacteriologic studies. Am Rev Respir Dis. 1977;115:777-82.

**Cite this article as:** Mohanty A, Kabi A, Mohanty AP, Gupta P, Gupta P. Diagnostic usefulness of transtracheal aspiration in lower respiratory tract infections. Int J Res Med Sci 2017;5:5203-6.