

## Case Report

# Primary intratesticular rhabdomyosarcoma: a rare aggressive childhood neoplasm

Rajnish Kumar<sup>1</sup>, Bhawna Sethi<sup>2\*</sup>, Madhukar Maletha<sup>3</sup>

<sup>1</sup>Department of Pathology, Teerthanker Mahaveer Medical College & Research Centre, Moradabad, Uttar Pradesh, India

<sup>2</sup>Department of Pathology, Shaheed Hasan Khan Mewati Government Medical College, Nuh, Mewat, Haryana, India

<sup>3</sup>Department of Surgery, Shri Guru Ram Rai Institute of Medical and Health Sciences, Patel Nagar, Dehradun, Uttarakhand, India

**Received:** 16 December 2019

**Revised:** 24 January 2020

**Accepted:** 31 January 2020

**\*Correspondence:**

Dr. Bhawna Sethi,

E-mail: [bhanuyogesh@gmail.com](mailto:bhanuyogesh@gmail.com)

**Copyright:** © the author(s), publisher and licensee Medip Academy. This is an open-access article distributed under the terms of the Creative Commons Attribution Non-Commercial License, which permits unrestricted non-commercial use, distribution, and reproduction in any medium, provided the original work is properly cited.

### ABSTRACT

Testicular tumors are relatively uncommon in children. The tumors of germ cell origin are still frequently encountered. The pure embryonal rhabdomyosarcomas of testis, not associated with sarcomatous component of the germ cell tumor, is a very rare entity. It is a highly aggressive tumor of childhood and young adolescents. In testes, it arises commonly from paratesticular tissue; primary intratesticular being extremely rare. To the best of authors knowledge, only fifteen cases of primary pure intratesticular tumor have been reported in the literature so far. We report a case of eight-year-old child who presented with a progressive painless right testicular enlargement over two months. Ultrasonography showed a heterogenous intratesticular mass. High orchidectomy was performed. Histopathological examination of the specimen assisted with immunohistochemistry revealed embryonal rhabdomyosarcoma.

**Keywords:** Childhood Intratesticular tumor, Embryonal rhabdomyosarcoma, Paratesticular tumor

### INTRODUCTION

Testicular sarcomas constitute only 1-2% of all testicular tumors and mostly appear as a component of germ cell tumor. Intra-scrotal sarcomas could be either paratesticular or intratesticular. Pure primary intratesticular Rhabdomyosarcomas (RMS), not associated with a germ cell tumor, are very rare.<sup>1</sup> Authors review the clinical features, histology, its differentials, prognosis and the treatment modalities.

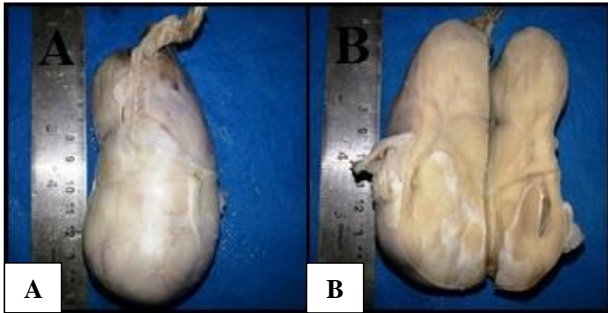
### METHODS

An eight-year-old child presented with rapidly progressive, painless right scrotal mass of two months' duration. On examination, it was well-defined, firm, and

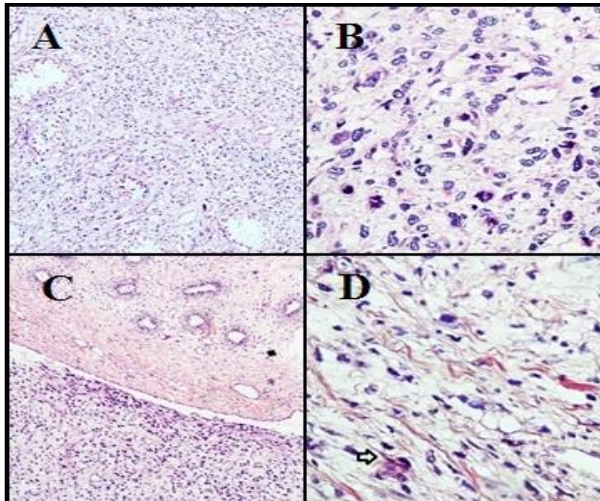
non-tender and measured 12.0 x 5.0 cm, and had restricted motility though not fixed to the scrotum. Ultrasonography confirmed a hetero-hyperechoic mass involving almost whole of the right testis. It revealed increased vascularity on color-doppler. There was no intra-abdominal lymph-node enlargement. Left testis appeared normal. The Chest radiograph, abdominal and chest computed-tomograph were normal. Serum alpha-fetoprotein and beta-human chorionic gonadotropin were normal. Subsequently, right-sided high orchidectomy was performed.

Grossly, the testis measured 11.5 x 4.8 x 4.0 cm. Tunica albuginea was intact and not involved by tumor. Cut-surface revealed nearly complete replacement of testis by a grey-white to grey-brown firm tumor contained within

the tunica. No haemorrhagic/necrotic areas seen. A portion of uninvolved epididymis was noticed. Attached spermatic cord measured 4.2 cm with free resected end (Figure 1).



**Figure 1: Gross appearance of testicular mass. (A) resected testicular mass: congested external surface and stretched but intact tunica. (B) cut surface shows a grey-white to grey-brown solid mass replacing almost whole of the testis.**

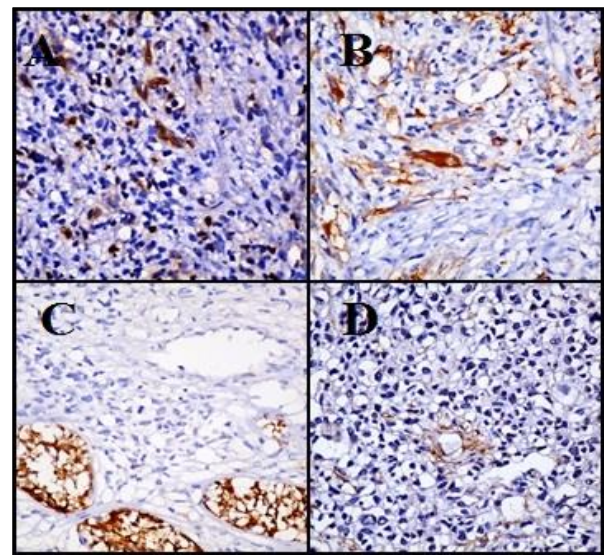


**Figure 2: Histomorphological findings (H and E and special stains) of testicular tumor. (A) A tumor infiltrating and replacing the testicular parenchyma (H and E, x 100). (B) A highly cellular neoplasm with pleomorphic vacuolated neoplastic cells and brisk mitosis (H and E, x 400). (C) Photomicrograph shows the tumor involving the testis (lower half) and the uninvolved epididymis, and (upper half) (H and E, x 100). (D) PTAH stain depicting striations (H and E, x400).**

Microscopy revealed a cellular neoplasm comprising pleomorphic cells with round-oval-elongated hyperchromatic nuclei, irregular nuclear membrane, and prominent nucleoli. The cytoplasm was clear and abundant. Atypical mitotic figures, multinucleated tumor giant cells and vascular invasion were seen. However, only occasional strap cell was seen. Few atrophic seminiferous tubules were seen. Intratubular malignant component was not seen. No associated germ-cell tumor

elements were found. The Periodic-acid Schiff stain was negative while Phosphotungstic Acid-hematoxylin stain (PTAH) revealed minimal striations in occasional cells. It was reported as a high-grade spindle cell neoplasm favoring embryonal rhabdomyosarcoma (Figure 2).

Immunohistochemistry supported the diagnosis with positivity for desmin, vimentin and myogenin and negativity for Calretinin, inhibin, Pan-CK, S-100, Placental Alkaline-Phosphatase (PLAP), and smooth muscle actin. MIB-1 index was 50-60%. The case was classified into stage-I and post orchidectomy chemotherapy (vincristine, actinomycin D and cyclophosphamide) was given. The patient is on regular follow-ups (Figure 3).



**Figure 3: Immunohistochemical staining of testicular tumor. Immunohistochemistry showed myogenin (A) and desmin (B) positivity in tumor cells (x 400), while tumor cells were negative for inhibin (only residual normal tubules showed positivity) (C) and smooth muscle actin (D).**

## DISCUSSION

Primary malignant tumors of testis are uncommon in infants and children.<sup>2</sup> Tumors of germ-cell origin are most frequent and account for 60-77% of testicular tumors in children.<sup>3</sup> Intrascrotal tumors arising from non-germ-cell origin are rare.<sup>4</sup> Rhabdomyosarcoma (RMS), though a common malignant tumor in children, accounts for only 6% of all non-germ cell intrascrotal tumors. Intrascrotal sarcomas could be either paratesticular or intratesticular.<sup>1</sup> Paratesticular RMS arises from the mesenchymal elements of the spermatic cord, epididymis or tunica vaginalis.<sup>5</sup> Intratesticular rhabdomyosarcoma is thought to arise either from undifferentiated mesenchyme with a capacity to rhabdomyoblastic differentiation, or from embryonal muscle tissue that has been displaced during the early stages of development.<sup>4</sup> It's also believed to be teratomatous with rhabdomyoblastic overgrowth of

primitive germ cells.<sup>1</sup> Genetic mutations affecting chromosomes 1,3 and 13 have also been found.<sup>6</sup>

Rhabdomyosarcoma has been observed in all age groups, but the majority occurs either in children or young adults supporting a possible hormonal induction.<sup>4</sup> The most common presentation is progressive painless swelling of the testes.<sup>4,7</sup> The tumor has no predilection for the side or any particular race.<sup>4</sup> In present case, the child aged eight years and presented with rapidly-growing, painless, firm right testicular mass. Microscopically, the definitive feature is the presence of rhabdomyoblasts. Cross striations can also be seen. In the International Classification of rhabdomyosarcoma there are five recognized histological variants: embryonal, alveolar, botryoid embryonal, spindle cell embryonal and anaplastic.<sup>7</sup> There is no relationship between histological variant and prognosis.

The primary intratesticular rhabdomyosarcoma needs to be differentiated from germ cell tumor with sarcomatous component, other intratesticular spindle cell sarcomas and paratesticular rhabdomyosarcoma. Diagnosis of primary intratesticular rhabdomyosarcoma should be made only after meticulous examination of any germ cell component due to therapeutic implications.

Immunohistochemistry (IHC) helps to exclude any occult germ-cell as well as sex-cord tumor component. Germ cell tumors show positivity for PLAP, CD-117, LDH, Vimentin, angiotensin I-converting enzyme (seminoma), Alpha-fetoprotein (yolk sac), high-molecular-weight keratin and CD 30 (embryonal). Sex cord stromal tumors show positivity for inhibin, Mart-1, calretinin (leydig cell tumors), vimentin, keratin, alpha 1-antitrypsin, and neuron-specific enolase (sertoli cell tumors).<sup>8</sup> IHC also assists in excluding other intratesticular spindle cell sarcomas like fibrosarcoma and leiomyosarcoma.<sup>1</sup> The RMS shows positivity for desmin, muscle-specific actin, vimentin, and myoglobin. More recently, MyoD1 and myogenin have been found as excellent markers.<sup>9</sup>

Since intratesticular rhabdomyosarcomas is known to have a better prognosis than paratesticular rhabdomyosarcomas, findings of scrotal ultrasound helps to exclude the possibility of more commonly seen paratesticular sarcomas.<sup>1</sup> The tumor was centered within the testis involving nearly the whole of it; no paratesticular pathology was seen in this case. The tumor was not adherent to the scrotal wall or the adjacent tissues. However, it is not possible in each case because these structures are in close proximity to each other and it is difficult to determine the specific site of origin once testis as well as paratesticular structures are involved.

Rhabdomyosarcoma is a highly malignant tumor with frequent recurrence.<sup>1</sup> Apart from tumor size, respectability, age and lymph node involvement are important prognostic factors for children. Since present case had no evidence of metastasis, he was assigned the

IRS stage 1.<sup>7</sup> Though the prognosis of intratesticular rhabdomyosarcoma is generally poor, multidisciplinary treatment approaches have led to improvement in survival. Orchidectomy followed by chemotherapy is the treatment of choice.<sup>1,10</sup> Though post-orchidectomy Retroperitoneal Lymph Node Dissection (RPLND) assists in accurate staging, it can serve a therapeutic purpose especially when combined with chemotherapy.<sup>1</sup> However, RPLND in the absence of positive findings on radiological investigation remains controversial.<sup>7</sup> Radiotherapy is recommended more commonly to control local recurrence, metastasis or for unfavorable histology, such as alveolar rhabdomyosarcoma.<sup>1,7</sup> However because of risk of occult metastasis, the patient was referred for chemotherapy after high orchidectomy. Recurrence is usually known to occur within two years hence patient is kept on regular follow-up.<sup>10</sup>

## CONCLUSION

Intratesticular rhabdomyosarcoma is a rare aggressive tumor, which needs accurate early diagnosis and treatment.

*Funding: No funding sources*

*Conflict of interest: None declared*

*Ethical approval: Not required*

## REFERENCES

1. Nasit JG, Parikh B, Trivedi P, Shah M. Primary intratesticular rhabdomyosarcoma in pediatrics. *Ind J Urol: IJU: J Urol Soci Ind.* 2013 Jan;29(1):77.
2. Green DM. Testicular tumors in infants and children. *Semin Surg Oncol.* 1986;2(3):156-62.
3. Cooper CS, Snyder HM III. Pediatric genitourinary cancer. In: *Nachtsheim D ed. Urological Oncology.* Georgetown, TX: Landes Bioscience; 2005:127.
4. Stewart LH, Lioe TF, Johnston SR. Thirty-year review of intrascrotal rhabdomyosarcoma. *Bri J Urol.* 1991 Oct;68(4):418-20.
5. Ahsaini M, Kassogué A, Tazi MF, Idrissi KS, Moumna K, Chbani L, et al. Early local recurrence of a pure embryonal rhabdomyosarcoma of the testis successfully managed with local resection associated with lymphadenectomy and adjuvant chemotherapy. *J Afri Cancer/African J Cancer.* 2014 May 1;6(2):115-8.
6. Parham DM, Ellison DA. Rhabdomyosarcomas in adults and children: an update. *Archiv Pathol Lab Med.* 2006 Oct;130(10):1454-65.
7. Kelly B, Lunden D, Rowaiye B, Daly P, Walsh K. Embryonal rhabdomyosarcoma of the testis. *Canad Urol Assoc J.* 2011 Feb;5(1):E7.
8. Rosai J. *Male Reproductive system.* Rosai and Ackerman's Surgical Pathology. 9<sup>th</sup> ed. St louis Missouri: Mosby; 2004:1420-1439.
9. Weiss SW, Goldblum JR. *Enzinger and Weiss's Soft Tissue Tumors.* 4<sup>th</sup> ed. Philadelphia: Mosby;2001:818-821.

10. Manasseh AN, Echejoh GO, Silas OA, Tanko MN, Jegede SK, Mandong BM. Testicular embryonal rhabdomyosarcoma: A case Report. *Int J Med Med Sci.* 2009 Nov;1:470-2.

**Cite this article as:** Kumar R, Sethi B, Maletha M. Primary intratesticular rhabdomyosarcoma: a rare aggressive childhood neoplasm. *Int J Res Med Sci* 2020;8:1148-51.