

Case Report

Spontaneous pneumoperitoneum secondary to intestinal pneumatosis: an uncommon cause of acute abdomen

Jonathan Salgado Vives, Enrique Chávez Serna*, Fernando Uraik Hernandez Bustos, Guadalupe Grisel Yañez Herrera

Department of General Surgery, Regional General Hospital No. 1, Mexican Institute of Social Security IMSS, Queretaro, Mexico

Received: 27 May 2021

Accepted: 01 July 2021

*Correspondence:

Dr. Enrique Chávez Serna,

E-mail: Enrique.chavez.serna@gmail.com

Copyright: © the author(s), publisher and licensee Medip Academy. This is an open-access article distributed under the terms of the Creative Commons Attribution Non-Commercial License, which permits unrestricted non-commercial use, distribution, and reproduction in any medium, provided the original work is properly cited.

ABSTRACT

Intestinal pneumatosis is a rare entity characterized by gas accumulation in the submucosa and or subserosa of the intestinal tract wall and is generally associated with other diseases, the primary presentation is rare. Most of the cases are asymptomatic, being infrequent the presentation as an acute abdomen secondary to a spontaneous pneumoperitoneum. We report the case of a patient with systemic sclerosis, who presented to the emergency department with abdominal pain and intestinal obstruction, without improvement to conservative treatment and with progression to acute abdomen, for which surgical treatment was performed showing intestinal pneumatosis that compromised the entire small intestine.

Keywords: Intestinal pneumatosis, Pneumoperitoneum, Acute abdomen, Systemic sclerosis

INTRODUCTION

Intestinal pneumatosis represents a rare clinical entity characterized by accumulation of gas in the submucosa and/or subserosa, forming cystic lesions within the gastrointestinal tract.¹ This pathology was reported for the first time in the year 1730 by Du Vernoi and later subcategorized by Koss in 1952.^{2,3} The incidence of intestinal pneumatosis is still unknown with precision, but it is increasingly reported as a finding, due to the frequent use of the computed tomography in abdominal pathologies.⁴ It can occur in any age group, from neonates to geriatrics³, with a slight predominance of the male gender and with a peak of presentation between 30 and 50 years.^{5,6} A series of autopsies reported an incidence of 0.03% in the general population.³ Intestinal pneumatosis can affect any segment of the digestive system, from the esophagus to the rectum, but it most frequently occurs in the small intestine (42%), (60% in the jejunum, 30% in the duodenum, and 10% in the ileum), followed by the colon

(36%) or both (22%) according to what has been reported in the literature.³⁻⁵ These cysts contain a mix of varying amounts of nitrogen, hydrogen, oxygen, carbon dioxide, butane, propane, methane, ethane, and argon.⁵ In approximately 85% of patients, pneumatosis is associated with chronic lung disease, rheumatologic diseases, immunosuppression, or disease gastrointestinal, classifying as secondary intestinal pneumatosis; the remaining 15% do not present underlying pathology, being its idiopathic etiology, for which it is classified as primary pneumatosis. Most of the cases are asymptomatic, although in up to 30% of the cases it can manifest as an acute abdomen secondary to spontaneous pneumoperitoneum due to rupture of the bullae.⁵

CASE REPORT

The case of a 61-years-old female is presented, who presented to the emergency department with distension, intense and diffuse abdominal pain, without stools, with

nausea and vomiting of intestinal characteristics of one week of evolution with sudden exacerbation on the last day. As an important personal history, she has a diagnosis of systemic sclerosis under treatment with immunomodulators, primary hypothyroidism, and chronic liver disease under study, which required therapeutic paracentesis 1 year ago.

In the physical examination, afebrile, conscious, ballooning abdomen, tympanic on percussion, decreased peristalsis, pain on deep palpation in all four quadrants, but no evidence of peritoneal irritation, no masses or tumors, no evidence of ascites fluid a tension, rectal examination without alterations. Laboratory studies were requested upon admission, without significant alterations, as well as ultrasound without conclusive changes, with little perihepatic fluid of ascites, conservative management was started with fasting, antibiotic therapy with a double scheme (ciprofloxacin plus metronidazole), and tube placement nasogastric, without exit of food and/or fecal material through it, without data of improvement, with diaphoresis and progression of abdominal pain, so it was chosen to carry out a contrasted tomographic study of the abdomen where air and free fluid are visualized in cavity, with high suspicion of intestinal perforation (Figures 1 and 2), adding data suggestive of peritoneal irritation, for which it was decided to perform exploratory transumbilical laparotomy, where the surgical findings were free air in the abdominal cavity with cystic intestinal pneumatosis of origin benign throughout the small intestine, little fluid of ascites, no evidence of associated intestinal perforation (Figure 3).

Given this situation, the diagnosis of intestinal pneumatosis was raised. The evolution was favorable after the intervention with analgesic treatment, antibiotic therapy and fasting for 3 days. After 6 days of adequate post-operative evolution, with bowel movements present, tolerating food, without the presence of complications, the patient was discharged and sent to the general surgery outpatient clinic to continue monitoring.

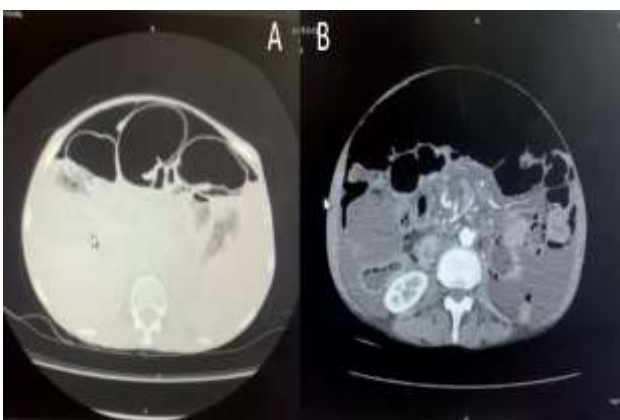


Figure 1: (A) Axial section at the hepatic level where intestinal loops with significant dilation, data of free air and perihepatic fluid are appreciated; (B) axial section at the renal level showing significant free air.

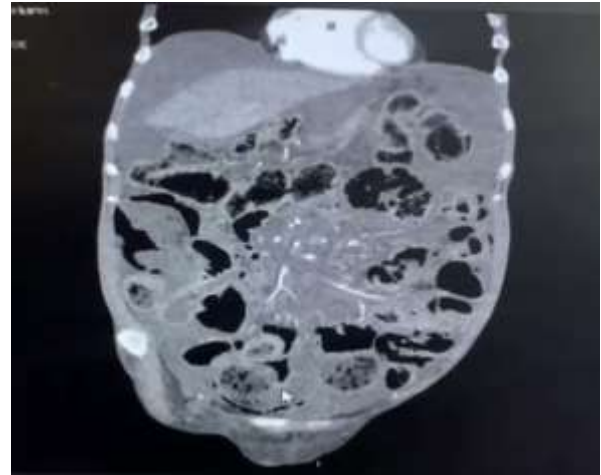

Figure 2: Coronal section of perihepatic and perisplenic fluid and diffuse intestinal involvement in relation to intestinal pneumatosis.

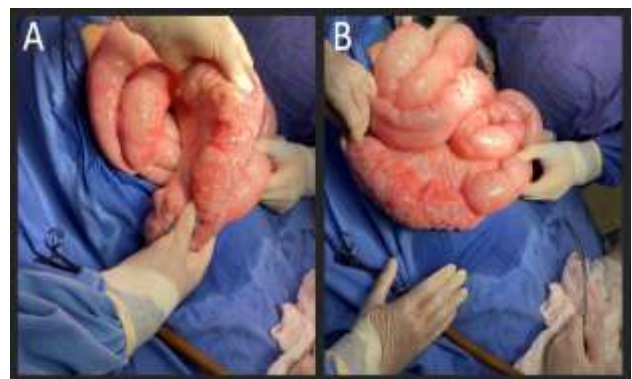


Figure 3: Intraoperative view of intestinal pneumatosis with a greater predisposition in the jejunum and ileum, but with involvement of the entire small intestine.

DISCUSSION

Intestinal pneumatosis is a rare condition in which gas-containing cysts form under the intestinal mucosa and serosa, the exact pathophysiology of this disease is currently unknown, although several theories are raised.⁷ There are multiple pathologies associated with this condition. Among the most common are those related to gastrointestinal, pulmonary, rheumatological, infectious diseases, immunosuppressive treatments, and trauma secondary to endoscopic or laparoscopic processes, in our case the patient presented rheumatological pathology, which could be associated with a secondary cause.^{2,3,5}

To explain the etiopathogenesis, three theories are described: the mechanical theory, which attributes the presence of transmural air to a state of increased intraluminal pressure and damage to the mucosa, which causes the gas to escape into the wall; the bacterial theory, which suggests that air is caused by the presence of gas-producing anaerobic bacteria (*Clostridium difficile* and

Clostridium perfringens), and the pulmonary theory, in which the increase in intrathoracic pressure in patients with pulmonary pathology (asthma, COPD) causes the alveoli to rupture and gas extravasation reaches the mediastinum, the retroperitoneal space, the mesentery and, finally, the intestinal serosa.⁶

Most patients are asymptomatic, but when clinical manifestations occur in intestinal pneumatosis, they are nonspecific, such as abdominal pain (59%), diarrhoea (53%), nausea and vomiting (14%), mucus in the stool (12%) and hematochezia (12%). Complications are usually infrequent, but appear in approximately 30% of patients, spontaneous pneumoperitoneum, volvulus, obstruction and intestinal ischemia are frequent.^{2,3,5,6}

The diagnosis of intestinal pneumatosis is made by exclusion, having ruled out other causes of abdominal pain, in general, by computed tomography or plain abdominal radiography, although computed tomography of the abdomen is the most sensitive and is considered the study of choice, in our study. In this case, the patient presented with a tense abdomen but without clear evidence of an acute abdomen on admission, and due to the history of chronic liver disease, the tomography helped us to rule out other more frequent causes of abdominal pain.⁴ The cysts can be described as linear, circular or with bubbles, without having a direct relationship with the severity of the pathology.⁷ However, it is easily confused with intestinal polyps, cancer, or inflammatory bowel disease, necrotizing enterocolitis.² The differential diagnosis mainly includes visceral perforation when it is debuts with spontaneous pneumoperitoneum, which occurs in 30% of patients with this pathology.⁷

Laboratory abnormalities are usually the result of the underlying disease causing intestinal pneumatosis. The main clinical predictors of intestinal necrosis and/or mortality in patients with intestinal pneumatosis include the following: pH less than 7.3, bicarbonate level less than 20 mEq/l, lactate level greater than 2 mmol/l, amylase level of more than 200 U/l, and laboratory test results are consistent with disseminated intravascular coagulation (prolonged prothrombin time, decreased fibrinogen level, elevated fibrinogen breakdown products, and an elevated D-dimer level.^{3,8,9}

Treatment of intestinal pneumatosis must be individualized according to the clinical conditions of the patient. Asymptomatic patients do not require any specific treatment, to indicate conservative treatment we must have a high diagnostic suspicion that it is this disease, while in patients with mild symptoms, conservative treatment can be started with intravenous antibiotic therapy (metronidazole is considered the antibiotic of choice, it is used for intraluminal bacteria, thus reducing anaerobic gas production), nasogastric decompression, sclerotherapy and intestinal rest (decreases the availability of substrates by bacteria) with a success rate of up to 93%.^{3,6,7,10} In patients with severe symptoms, with suspected related

complications (perforation, obstruction, hemorrhage, intestinal volvulus or portal pneumatosis), and/or if there is the presence of predictors of mortality in the laboratory results, emergency surgical intervention will be indicated, being the successful exploratory laparotomy in most of these cases, in this case we opted for surgical treatment due to the progression of symptoms in the patient, the poor response to conservative treatment in the first hours and the findings obtained by the tomographic study where there was high suspicion of perforation by air and free liquid.^{1,3,6}

High flow oxygen therapy as well as hyperbaric oxygen have long been recognized as an effective therapy for intestinal pneumatosis, leading to regression of the cyst on imaging and resolution of symptoms. It is currently an alternative to conservative treatment that has shown excellent results.³ The accumulation of oxygen in the cysts increases the partial pressure of hydrogen in them, which causes the diffusion of hydrogen out of the cyst into the bloodstream at high pressure. resolution of the cyst follows reabsorption of oxygen for use in cellular metabolism. Increased oxygenation at the tissue level can facilitate phagocytic activity and directly attack gas-producing organisms. Currently, no complications have been reported with the use of this therapy, with an improvement in symptoms in 89% of patients.^{3,11}

CONCLUSION

Intestinal pneumatosis is a rare entity that in most cases is associated with other pathologies, it is generally asymptomatic and is diagnosed as a finding in cabinet studies, however; it can present as an acute abdomen secondary to a spontaneous pneumoperitoneum, where the presence of intestinal perforation should be ruled out as the first option. Intestinal pneumatosis should be considered as a differential diagnosis causing acute abdomen, especially when the patient has associated pathologies, such as rheumatological diseases. Currently there is no standardized regimen in the treatment of this pathology, within conservative management, oxygen therapy seems to be an alternative with promising results that should be taken into account, however, each patient must be individualized in order to avoid complications. Surgical treatment is reserved for those cases with acute abdomen presentation, high suspicion of complications and failure of conservative treatment.

Funding: No funding sources

Conflict of interest: None declared

Ethical approval: Not required

REFERENCES

1. Kaya B, Celik K, Karip AB, Altun H, Ozbay ON, Bat O, Memişoğlu K. Pneumatosis cystoides intestinalis mimicking acute abdomen. Turk J Gastroenterol. 2014;25(4):426-8.

2. Ling F, Guo D, Zhu L. Pneumatosis cystoides intestinalis: a case report and literature review. *BMC Gastroenterol.* 2019;19(1):176.
3. Feuerstein JD, White N, Berzin TM. Pneumatosis intestinalis with a focus on hyperbaric oxygen therapy. *Mayo Clin Proc.* 2014;89(5):697-703.
4. Khalil PN, Huber WS, Ladurner R, Kleespies A, Siebeck M, Mutschler W, et al. Natural history, clinical pattern, and surgical considerations of pneumatosis intestinalis. *Eur J Med Res.* 2009;14(6):231-9.
5. Peraza Casajús JM, Fernández F, Iglesias M, Montoro S, Borobia L. Spontaneous pneumoperitoneum secondary to intestinal cystic pneumatosis. *Cir Esp.* 2009;86(2):113-4.
6. Balciscueta CI, Álvarez MD, Blanco GFJ. Intestinal pneumatosis. An uncommon cause of acute abdomen. *Gastroenterol Hepatol.* 2019;42(9):557-8.
7. Rodríguez JJ, Utrillas MAC, Antón BJS, Moreno OAA, Val JMD. Neumatosis quística intestinal: reporte de un caso. *Cir Cir.* 2018;86(4):370-3.
8. Greenstein AJ, Nguyen SQ, Berlin A, Corona J, Lee J, Wong E, Factor SH, et al. Pneumatosis intestinalis in adults: management, surgical indications, and risk factors for mortality. *J Gastrointest Surg.* 2007;11(10):1268-74.
9. Senosiain C, Crespo L, Maroto M, García-Sánchez MC. Neumatosis intestinal [Pneumatosis intestinalis]. *Med Clin (Barc).* 2014 May 20;142(10):e19.
10. Munive AF, Barreto ZR. Pneumatosis cystoides intestinalis. *Rev Esp Enferm Dig.* 2017;109(1):61.
11. Wayne E, Ough M, Wu A, Liao J, Andresen KJ, Kuehn D, et al. Management algorithm for pneumatosis intestinalis and portal venous gas: treatment and outcome of 88 consecutive cases. *J Gastrointest Surg.* 2010;14(3):437-48.

Cite this article as: Salgado-Vives J, Chávez-Serna E, Hernandez-Bustos FU, Yañez-Herrera GY. Spontaneous pneumoperitoneum secondary to intestinal pneumatosis: an uncommon cause of acute abdomen. *Int J Res Med Sci* 2021;9:2455-8.