

## Case Report

# The anti-synthetase syndrome in a type 1 diabetes

Kshithija Sajjan, Anuj Pahuja, Yadav Ponvijaya\*, Manoj Prakash Jeyaseelan

Department of Medicine, Dr. DY Patil Medical College and Vidyapeeth, Pune, Maharashtra, India

**Received:** 12 August 2020

**Accepted:** 11 September 2020

**\*Correspondence:**

Dr. Yadav Ponvijaya,

E-mail: [ponvijayamuthuswamy@gmail.com](mailto:ponvijayamuthuswamy@gmail.com)

**Copyright:** © the author(s), publisher and licensee Medip Academy. This is an open-access article distributed under the terms of the Creative Commons Attribution Non-Commercial License, which permits unrestricted non-commercial use, distribution, and reproduction in any medium, provided the original work is properly cited.

### ABSTRACT

Anti-synthetase syndrome is an autoimmune disease associated with interstitial lung disease (ILD), dermatomyositis and polymyositis. It has been recognized as an important cause of autoimmune inflammatory myopathy in a subset of patients with dermatomyositis. 37-year-old male, known case of type 1 diabetes mellitus, came with complaints of: generalized anasarca, pain in both knees, ankles, wrist and small joints of fingers. He also had dyspnoea on exertion, chronic non-productive cough, and fever off and on, all for 1 month. Initially all involvement was attributed to diabetes. For joint pain an antinuclear antibodies (ANA) was sent. He turned out to be anti-Jo1, antibody positive. Rash on hands was diagnosed by dermatologist as, mechanic's hand, hence diagnosed as an inflammatory myopathy with dermatomyositis anti-synthetase syndrome. Patient was successfully treated with immunosuppressants and supportive treatment and responded to tablet Prednisolone and Mycophenolate mofetil. The patient had one major and 2 minor criteria-ILD, arthritis and Mechanic's hand and anti-Jo 1 antibody positive. Thus, diagnosed as anti-synthetase syndrome with type 1 diabetes mellitus.

**Keywords:** Anti synthetase syndrome, Anti Jo1 syndrome, Dermatomyositis

### INTRODUCTION

Anti-synthetase syndrome has been recognized as an important cause of autoimmune inflammatory myopathy with polymyositis and dermatomyositis. More prevalent in woman than in men. Anti-synthetase syndrome is a rare inflammatory muscle disease related to dermatomyositis and polymyositis. Prognosis is poor when there is presence of ILD in anti-synthetase syndrome as it is severe and rapidly progressive in nature. Early diagnosis and treatment are necessary to prevent pulmonary complications.

### CASE REPORT

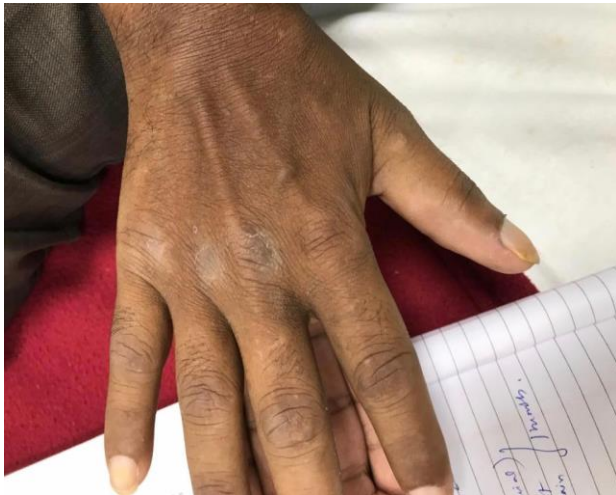
A 37-year-old male presented to medicine OPD with complaints of generalised body swelling, associated with joint pain involving both knees, ankles, wrists and phalanges for 1 month. It was associated with low grade

fever. Patient also complained of intractable non-productive cough along with dyspnoea on exertion. Patient was a known case of type I diabetes mellitus for 8 years on insulin therapy. On examination he was febrile with a temperature of 101<sup>0</sup> F, pulse of 90 bpm, blood pressure of 110/80 mmHg. There were no signs of respiratory distress seen. On physical examination pallor, icterus, clubbing was absent and he had bilateral pitting type of pedal oedema. Wrist, small joints of hand and knee and ankle were painful with restricted movement. Since patient was diabetic, all findings were attributed to diabetic complications with possibility of associated rheumatoid arthritis. However, patient's diabetic status was quickly controlled, and patient was reviewed.

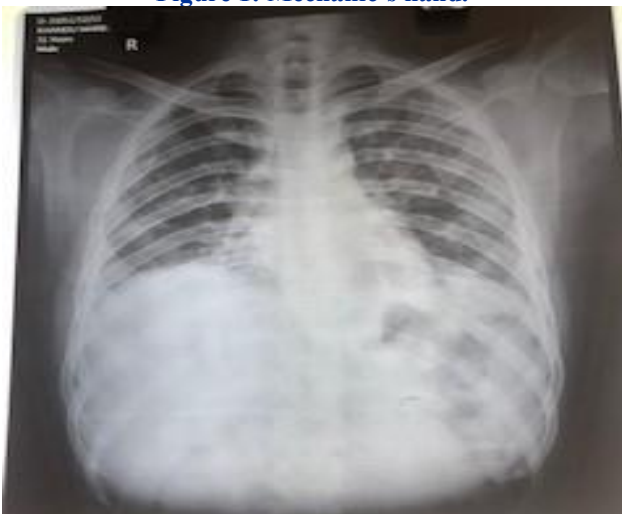Gottron papules over extensor aspect of hands and hyperpigmented scaly plaques were seen on knuckles of right hand were diagnosed by dermatologist as Mechanic's hand.

systemic examinations revealed no abnormality. Routine lab investigations were normal. CRP and RA were positive, Anti-CCP negative, ANA blot was positive for 17 B and anti-Jo1 antibodies, CPK total was raised (384 IU/L). X ray of knee: showed joint effusion. X ray of hand was normal. Chest X ray: Reticulo-nodular opacities in both lung fields. High-resolution computed tomography (HRCT) thorax showed diffuse interstitial septal thickening, honeycomb shadowing and ground glass opacities with cylindrical bronchiectasis in bilateral basal segments suggestive of ILD-diagnosis: UIP pattern in rheumatoid arthritis (RA)- ILD. Pulmonary function test showed restrictive pattern. Electromyography (EMG) was done suggestive of primary inflammatory muscle disease. NCV was suggestive of sensory-motor axonal polyneuropathy involving all 4 limbs. Patient was diagnosed as a case of anti-synthetase syndrome

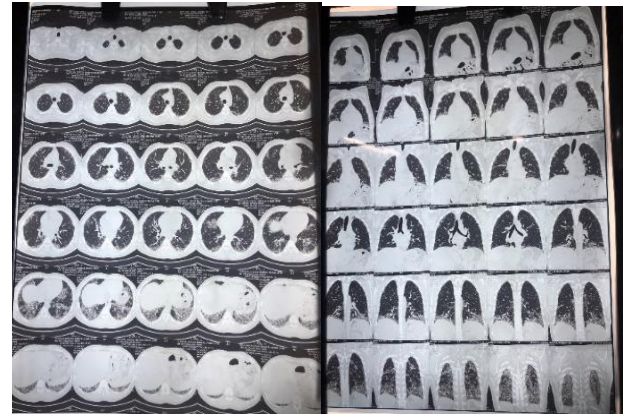
The patient was treated with tablet Prednisolone (20 mg) and Mycophenolate mofetil (500 mg) and was discharged with regular follow up.



**Figure 1: Mechanic's hand.**



**Figure 2: Reticulo-nodular opacities in lung fields.**



**Figure 3: HRCT of thorax.**

## DISCUSSION

Anti-synthetase syndrome is a chronic autoimmune disease. It has six predominant clinical features such as fever, myositis, ILD, mechanic's hand, Raynaud's phenomenon and inflammatory myositis. Anti-synthetase syndrome has been recognized as an important cause of autoimmune inflammatory myopathy in a subset of patients with dermatomyositis.<sup>1,2</sup>

Anti-synthetase syndrome was first described by Marguerite and coworkers in 1990. Anti-synthetase syndrome is a rare inflammatory muscle disease related to dermatomyositis and polymyositis.

Dermatomyositis is a vasculopathic myopathy with perimysial vascular inflammation, myofiber ischemic lesions, and endomysial microangiopathy with complement activation.<sup>2,3</sup>

Relationship with polymyositis is by a cell-mediated autoimmune response directed towards myofibers, as assessed by abnormal ubiquitous MHC class I/HLA-ABC myofiber re-expression and endomysial CD8 T-cells surrounding and invading non-necrotic fibers.<sup>3</sup>

The cohort studies have indicated that 20-25% of patients diagnosed with polymyositis or dermatomyositis have anti-synthetase antibodies.<sup>5</sup> polymyositis or dermatomyositis patients with anti-synthetase antibodies also have ILD, the major determinant of morbidity and mortality in the anti-synthetase syndrome.<sup>4</sup>

Anti-synthetase syndrome is frequently revealed by interstitial lung disease and arthritis.<sup>6</sup> Because inflammatory arthritis mimics RA, Anti-synthetase syndrome should be considered in atypical cases. Most common antibodies detected are anti-Jo1 and anti-histidyl-tRNA synthetase antibody. Others include Anti-PL-7, Anti-PL-12, Anti-EJ, Anti-KS, Anti-OJ. Patients with anti-Jo-1 90% have muscle involvement and 50-70% have ILD, 30% develop mechanic's hand.<sup>3-6</sup> HRCT findings in anti-synthetase syndrome include tractional

bronchiectasis, multiple ground glass opacities, honeycombing and reticulonodular opacities. In the patient HRCT thorax showed bilateral multiple ground glass opacities with cylindrical bronchiectasis and honeycomb shadowing. Maturu and Lakshman in their study from PGI Chandigarh state that anti-synthetase syndrome is a treatable cause of ILD and its true prevalence remains unknown. A younger age at presentation and the presence of NSIP pattern on imaging should raise a clinical suspicion of AS.

Hervier and Lambert et al reported an interesting rare case of overlap syndrome with PL-7 ASS, Sjogren's, systemic lupus erythematosus and RA with evolving symptoms over time.<sup>8,13-15</sup> Anti-synthetase syndrome has often been reported in overlap with polymyositis, dermatomyositis, systemic sclerosis, Sjogren's and RA.

There have also been reports of lower prevalence of mechanics hands and joint symptoms in PL-7 patients compared to Jo-1 patients.<sup>8</sup>

Pulmonary involvement can present as a spectrum from asymptomatic to progressive or acute lung disease. Pericardial disease, intestinal pseudo-obstruction, and malignancy have been reported in ASS as well.<sup>4</sup>

Based on the guidelines, affected individuals must also have two major criteria or one major criterion, or two minor criteria of the disorder.<sup>9,10</sup> The two major criteria are ILD and muscle disease. Minor criteria are arthritis, Raynaud phenomenon, or thickening and cracking of the skin of the hands (Mechanic's hands).

The patient had one major criteria in the form of ILD, and 2 minor criteria: arthritis and Mechanic's hands

Recently Langlois and Gillibert working in France in their study comparing Rituximab and Cyclophosphamide for anti-synthetase syndrome with ILD, concluded that despite similar pulmonary progression-free survival (PFS) at 6 months, RTX was associated with a better 2-year PFS compared to intravenous cyclophosphamide (CYC) in patients with anti-synthetase syndrome-related ILD.<sup>11</sup>

Earlier, Rigby and Plit from Sydney Australia had successfully used Tacrolimus in 2 patients of anti-synthetase syndrome with ILD.<sup>16</sup>

The patient responded to Prednisolone and Mycophenolate Mofetil.

## CONCLUSION

Diagnosed anti-synthetase syndrome in the patient with pre-existing diabetes mellitus on the basis of 1 major and 2 minor criteria of ILD, Arthritis and Mechanics hands and Anti-Jo antibody. Patient responded to

corticosteroids and Mycophenolate mofetil and is on regular follow-up.

Clinical implications included anti-synthetase syndrome has to be specifically looked for in patients with multi-systemic disease like diabetes and other rheumatological diseases where the clinical features may overlap. Though anti-synthetase is a rare autoimmune disorder, delayed diagnosis can lead to pulmonary complications such as pulmonary fibrosis and pulmonary hypertension. The goal of treatment is to prevent further muscle wasting from disuse and prevent contractures.

## ACKNOWLEDGEMENTS

Authors would like to thank Dr. Vijayashree S. Gokhale, Prof. Department of medicine.

*Funding: No funding sources*

*Conflict of interest: None declared*

*Ethical approval: Not required*

## REFERENCES

1. Chatterjee S, Prayson R, Fraver C. Anti-synthetase syndrome: Not just an inflammatory myopathy. *Clev Clin J Med.* 2013;80(10):655-67.
2. Katzap E, Labarca BM-L, Marder G. Antisyntetase Syndrome. *Curr Rheumatol Rep.* 2011;13(3):175-81.
3. Mahler M, Miller FW, Fritzler MJ. Idiopathic inflammatory myopathies and the anti-synthetase syndrome: a comprehensive review. *Autoimmune Rev.* 2014;13:367-71.
4. Maturu VN, Lakshman A, Bal A, Dhir V, Antisyntetase syndrome: An under-recognized cause of interstitial lung disease *Lung India.* 2016;33(1):20-6.
5. Cojocaru M, New Insights into Antisyntetase Syndrome, *Maedica (Buchar).* 2016;11(2):130-5.
6. Witt LJ, Curran JJ and Strek ME. The Diagnosis and Treatment of Antisyntetase Syndrome. *Clin Pulm Med.* 2016;23(5):218-26.
7. Rozelle A, Trieu S, Chung L. Malignancy in the setting of the anti-synthetase syndrome. *J Clin Rheumatol.* 2008;14(5):285-8.
8. Hervier B, Lambert M, Hachulla E, Musset L, Benveniste O, Piette JC. Anti-synthetase syndrome positive for anti-isoleucyl-tRNA synthetase antibodies: an unusual case overlapping with systemic sclerosis and Sjögren's syndrome. *Rheumatol.* 2011;50(6):1175-6.
9. Antisyntetase Syndrome Rare Disease Database NORD.
10. Khan KA, Ahmed WN. Antisyntetase syndrome: A case report and literature review. *Hamdan Med J.* 2018;11(1):87-90.
11. Langlois V, Gillibert A, Uzunhan Y, Chabi ML, Hachulla E, Hachulla E, Cardinal LO. Rituximab and Cyclophosphamide in anti-synthetase syndrome

- (ASyS)-related ILD: an observational retrospective study. *J Rheumatol.* 2020;47:9.
12. Badshah A, Haider I, Pervez S, Humayun M, Antisynthetase syndrome presenting as interstitial lung disease: a case report. *J Medical Case Rep.* 2019;13(241).
  13. Jawaid M, Ross Y, Kamran M. PL-7 Antisynthetase Syndrome in Association with Sjögren's, Systemic Lupus Erythematosus, and Rheumatoid Arthritis. *Case Rep.* 2020;4.
  14. Huang K, Aggarwal R. Antisynthetase syndrome: A distinct disease spectrum February 18, 2020. *J scleroderma related Disorders.* 2020;5(3):178-91.
  15. Kumar RR, Jha S, Dhooria A, G S R S N K Naidu, Minz RW, Kumar S. Anti-Jo-1 Syndrome Often Misdiagnosed as Rheumatoid Arthritis (for Many Years): A Single-Center Experience. *J Clin Rheumatol.* 2019.
  16. Rigby AL, Plit M, Glanville AR. Tacrolimus rescue therapy for severe respiratory failure in the anti-synthetase syndrome. *Respirol Case Rep.* 2014;2(2):70-72.

**Cite this article as:** Sajjan K, Pahuja A, Ponvijaya Y, Jeyaseelan MP. The anti-synthetase syndrome in a type 1 diabetes. *Int J Res Med Sci* 2020;8:3749-52.