

## Review Article

# Current perspective in the treatment of bile duct injuries

Juan José Granados-Romero<sup>1</sup>, Aranza Guadalupe Estrada-Mata<sup>2</sup>, Mariana Espejel-Deloiza<sup>2</sup>,  
Jesús Carlos Ceballos-Villalva<sup>3</sup>, Ericka Hazzel Contreras-Flores<sup>2</sup>, Benjamín León-Mancilla<sup>4</sup>,  
Germán Eduardo Mendoza-Barrera<sup>5</sup>, Carlos Aarón Méndez-Celis<sup>5</sup>,  
Alan Isaac Valderrama-Treviño<sup>5\*</sup>

<sup>1</sup>Cirugía General, Hospital General de México. Secretaría de Salud. Distrito Federal, México

<sup>2</sup>AFINES, Facultad de Medicina, Universidad Nacional Autónoma de México. Distrito Federal, México

<sup>3</sup>Departamento de Anatomía, Facultad de Medicina, Universidad Nacional Autónoma de México. Distrito Federal, México

<sup>4</sup>Laboratorio de Biomateriales, Facultad de Medicina, Universidad Nacional Autónoma de México. Distrito Federal, México

<sup>5</sup>Departamento de Cirugía, Facultad de Medicina, Universidad Nacional Autónoma de México. Distrito Federal, México

**Received:** 13 January 2016

**Accepted:** 08 February 2016

### \*Correspondence:

Dr. Alan Isaac Valderrama Treviño,

E-mail: alan\_valderrama@hotmail.com

**Copyright:** © the author(s), publisher and licensee Medip Academy. This is an open-access article distributed under the terms of the Creative Commons Attribution Non-Commercial License, which permits unrestricted non-commercial use, distribution, and reproduction in any medium, provided the original work is properly cited.

## ABSTRACT

The laparoscopic cholecystectomy is considered the gold standard for the treatment of benign gallbladder disease, which is associated with an increased incidence of biliary injuries. These types of injuries are multicausal, and anatomical variations or anatomical perception errors are the most common risk factors. The objective of this study is to describe the evolution in the management of bile duct injuries and actual, diagnostic tools, incidence, prognosis and treatment. A literature research about diagnosis and treatment of iatrogenic bile duct injuries as well as their impact on the incidence of morbidity and mortality, based on a 30-year period, was performed on Medline, Cochrane, Embase, MedScape and PubMed database, for all studies that met the eligibility criteria. A thorough quality assessment of all included studies was performed. Synthesis of the results was achieved by narrative review. The bile duct injury is a complication that requires a complex therapy and multidisciplinary management. Reconstruction and treatment techniques have been evolving. The selection of adequate treatment will impact on the patient's quality of life. The results of the existing studies reporting on iatrogenic bile duct injuries are useful; because the iatrogenic bile duct injuries are complex alterations and constitute one of the most serious complications of a cholecystectomy and require a comprehensive approach, immediate repair, proper drainage and timely referral to adequate treatment to improve long-term prognosis. According to the literature review, currently there better treatments such as absorbable prosthesis, which improve the prognosis and patient's quality of life, and represent less risk of complications in short/long term.

**Keywords:** Bile duct injuries, Laparoscopic cholecystectomy, Bile duct prosthesis, Diagnosis, Treatment, Mortality

## INTRODUCTION

The iatrogenic injury of bile duct is a serious accident with severe consequences, mainly during laparoscopic

cholecystectomy, which is the gold standard for treating cholelithiasis and the most commonly performed abdominal intervention,<sup>1-3</sup> this type of lesion is defined as damage to the wall the bile duct during cholecystectomy

detected or diagnosed postoperatively as a result of leaking or biliary obstruction not caused by calculus.<sup>4,5</sup> These complications can present in various surgical procedures but in this decade, with the introduction and diffusion of laparoscopic cholecystectomy, the incidence has increased.<sup>5,6</sup>

The diagnostic, treatment and therefore the prognosis has changed nowadays. There are many factors that increase the risk for a bile duct injury during a laparoscopic cholecystectomy, such as age, sex, congenital malformations like partial agenesis of liver, acute cholecystitis, hidden cystic duct syndrome, errors of anatomical perception in laparoscopic surgery and surgeon's experience, principally due to the complex biliovascular anatomy.<sup>3</sup> Because of its impact on the workplace, clinical, and economic sphere, it is imperative to have a clear concept about their clinical presentation, diagnosis, classification, complexity and appropriate treatment.<sup>2,4</sup>

Another issue on the evaluation of this injuries is the damage of the bile duct, which in sometimes is radical or irreversible, and the impact on the quality of life of a patient if not properly treated, as the consequences can be serious.<sup>5</sup> It is important to study the progress of diagnostic methods like treatment options, which will reduce the incidence of morbidity and mortality in patients.<sup>3,6</sup> The treatment must be carefully chosen, because an improper treatment can trigger disastrous results both in short and long term. It is important to consider, the mechanisms of injury, previous attempts of repair, surgical risk, and the general condition of the patient, which are important and influential for making diagnostic and therapeutic decisions, and therefore a multidisciplinary approach.<sup>4</sup>

Technical innovation within surgery is laudable and the progress that results is generally a consequence of the

quest to achieve optimum outcomes for patients. The aim of this study is to demonstrate the evolution of management of bile duct injury in the past 30 years and currently the diagnosis, clinical manifestations and treatment performed essentially as well as its survival.

## METHODS

A search was performed in various databases; Medline, Cochrane, PubMed, to find relevant articles of the issue and online clinical evidence, focusing on systematic reviews, meta-analyzes, controlled trials, review articles, based on studies of the past 40 years (1970-2015), using keywords in Spanish and English: bile duct injury, laparoscopic cholecystectomy, bile duct prosthesis, diagnosis, treatment, morbidity, and mortality in bile duct injury.

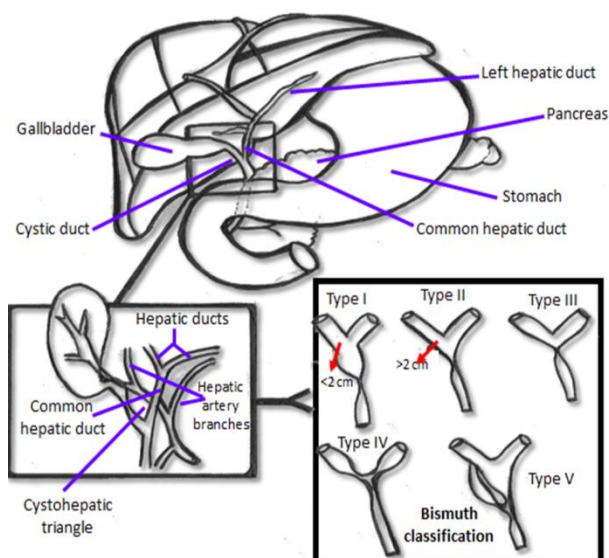
### Epidemiology

In 1990, the incidence of iatrogenic bile duct injuries by laparoscopic cholecystectomy was approximately 0.3 to 1.3%, today the average is 0.6%, being twice as common during an open surgical procedure (0.6% laparoscopic surgery vs 0.3% open surgery).<sup>5,8-10</sup> The bile duct injuries associated with laparoscopic cholecystectomy remains a clinical problem with high morbidity related to the learning curve.<sup>6,9</sup> The location of lesion is important due to the consequences that may occur. When the lesion has a proximal location to the biliary tree, it is associated more to a vascular injury. It has been observed that the most affected age range is 16 to 83; today the average is 49 years.<sup>7,10</sup>

From initial classification published by Bismuth, there have been many classification of common bile duct injury, however, the classification more used in bile duct injuries is Bismuth classification (Table 1), groups the bile duct injury grades I to V (Figure 1).

**Table 1: Bismuth classification.**

		% Injuries	Global mortality
Type I	Injury >2 cm distal to the biliary confluence	18-36% <sup>8</sup>	0.1- 0.17% <sup>8</sup>
Type II	Injury <2 from the biliary confluence	27-38% <sup>7</sup>	
Type III	Injury of the entire common hepatic duct without involvement of the biliary confluence.	20-33% <sup>6</sup>	
Type IV	Complete or partial destruction of the biliary confluence	16- 39% Joseph F. and Cols., 2005, Arch Surg	
Type V	Injure-aberrant right hepatic duct or common hepatic duct.	7% <sup>7</sup>	



**Figure 1: Liver biliary tract anatomy and Bismuth classification.**

The bile duct injury type IV is the most common, with a percent of 58.5% in laparoscopic cholecystectomy compared to open surgery with 41.5%, featuring variable and survival. As for the more predominant clinical manifestations is the pain.<sup>5-8</sup>

#### **Risk factors**

There are many factors can predispose to a surgical accident. Among risk factors for iatrogenic bile duct injuries, are older age and male sex, anatomic anomalies of bile duct, as well as congenital anomalies such as partial hepatic agenesis.<sup>9,11</sup> One of the major risk factors is when laparoscopic surgery is for acute cholecystitis compared with chronic cholecystitis, with an incidence of approximately. 77 to 5.0% and is one of the major risk factors.<sup>10,12</sup> Also anatomical perception errors in laparoscopic surgery, are one of the most frequent cause for iatrogenic bile duct injury. Bile duct injuries in laparoscopic surgery are more serious and complex due to the proximal location and it is often associated with vascular injury.<sup>11</sup>

#### **Diagnosis**

The biliary injuries are generally recognized intraoperatively or immediately postoperatively.<sup>12,14</sup> Among the characteristic symptoms are diffuse abdominal pain, nausea, fever, impaired intestinal motility, bile collections, peritonitis, leucocytosis, and mixed hyperbilirubinemia. Therefore an obstructive pattern and jaundice are frequent.<sup>13,15</sup> If this type of injury is not properly treated, may produce severe consequences. A late clinical evolution leads to disastrous consequences.<sup>9-14</sup>

These lesions can range from injuries of the accessory pathway to complicated biliary lesions; consequently significant morbidity can accompany this type of injury (Table 2). Late complications such as bile duct strictures or secondary biliary cirrhosis may result in a change in the quality of life of patients, so these patients require surgical, radiological special care, and endoscopy collaboration.<sup>15</sup> Approximately 15 to 30 % of lesions are diagnosed during surgery, with an average of 23%, and of this, approximately 21% is realized with procedures as intraoperative cholangiography abnormal and the rest by clinical diagnosis can detect bile leakage.<sup>16</sup>

Different methods can help the diagnosis of bile duct injuries, however, according to literature review and medical experience, the magnetic resonance cholangiopancreatography is a very reliable method of diagnosis for X-ray examination of the bile duct with suspected of iatrogenic injury. And it is essential for the early diagnosis of bile duct injury. Using cholangiography is essential for accurate image of biliary tree.<sup>17</sup> In cases where the bile duct has been severed, this method is good for correctly predicting the anatomic location of the lesion in about 85% of patients.<sup>13</sup> This method can further decrease the risk of identifying lesions in the bile duct. It has been shown that early detection of biliary tract injury during the primary operation, improves survival. Using intraoperative cholangiography reduced the mortality after cholecystectomy by 62%.<sup>15,18</sup>

Also, there are various methods for postoperative diagnosis, including the most used in previous years the transabdominal ultrasonography, and endoscopic retrograde cholangiopancreatography with or without percutaneous trans hepatic cholangiography. In later years are began using tomography and magnetic resonance computerized as a diagnosis methods.<sup>19</sup> Other diagnosis methods are the ultrasound of the abdominal cavity that allows imaging of intrahepatic and extra hepatic biliary track to get the diameter measurement of common hepatic duct bile.<sup>20</sup> Other diagnostic methods are laboratory and radiologic studies. Moreover among the laboratory tests that are indicators of cholestasis and liver function: bilirubin, alkaline phosphatase, alanina.<sup>19,21</sup> In patients with iatrogenic injury without complications or liver damage, do not rise aminotransferases. Generally these increases in cases of serious complications of unrecognized biliary lesions or incorrect treatment, such as secondary biliary cirrhosis.<sup>22</sup> Despite the different methods used to diagnose injuries bile duct, percutaneous transluminal coronary angioplasty (PTCA) is the most useful method for imaging damaged bile ducts and allows proper repair of small injuries by inserting a prosthesis<sup>15,23</sup> and the magnetic resonance cholangiopancreatography is the most sensitive method (approximately 85 to 100%) and less invasive, being the gold standard for diagnosis.<sup>18,19,24</sup>

**Table 2: Evolution in mortality, survival, diagnosis and treatment of bile duct injuries.**

Year	% Of injuries		Mortality	Survival	Diagnosis	Treatment
	Open surgery	Laparoscopic surgery				
1970's	0.17% Boroyi EM. and Cols. 1979, Sov Med.	0.74-2.8% Boroyi EM. 1979, Sov Med	89-100% Joseph M, and Cols. 2012. Ann Surg.	10% Joseph M, and Cols. 2012. Ann Surg.	Intraoperative and percutaneous cholangioscopy. Joseph M, and Cols. 2012. Ann Surg	Hivet- Warren technic Percutaneous biliary drainage Cutaneous stoma jejunal limb Roux-en-Y Schmidt SC, y Cols. 2004, Zentralbl Chir.
1980's	0.15-0.17% Richardson M. and Cols. 1996, Br J Surg.	0.3-0.6 % Richardson M. and Cols. 1996, Br J Surg.	65% Boroyi EM. 1979, Sov Med.	30- 50% Boroyi EM. 1979, Sov Med.	Intraoperative cholangiography. CPRE Stewart L. and Cols. 2014, Surg Clin North Am.	Prosthesis Percutaneous biliary drainage. Transanastomotic stent. Law R. and Cols. 2015, Gastrointest Endosc.
1990's	0.1% Attila Scendes y Cols. 1995. Rev. Chil. Cir	0.3-1.3 % Attila Scendes y Cols. 1995. Rev. Chil. Cir	4-20% Chaudhary A. y Cols. 2002. Dig. Surg.	80% Richardson M. and Cols. 1996, Br J Surg.	Intraoperative cholangiography. Gurusamy Ks. and Cols.2015, Cochrane Database Syst Rev.	Surgical biliary drainage Roux- en – Y Hepaticojejunostomy Transanastomotic stent Kehr's T tube suture Abellán Morcillo y Cols. 2014, Cir Esp.
2000	0.1-0.15% Ferrain A. and Cols. 1999, PROACI.	0.3-0.6 % Joseph M. y Cols. 2015. Ann Surg.	6% Bourricaudy Norkis y Cols. 2008. Rev. Cub. Med. Mil	80-95% Bourricaudy Norkis y Cols. 2008. Rev. Cub. Med. Mil	Intraoperative cholangiography Magnetic resonance CPRE Gurusamy Ks. and Cols.2015, Cochrane Database Syst Rev.	Open access endoscopy to anastomosis Stents Voelcker drainage at hepaticojejunostomy Y drainage –oblique channell type Witzel Kehr's T tube suture Abellán Morcillo y Cols. 2014, Cir Esp.
2015	0.15 % Tsalis P, 2003. Surg Endosc.	0.16-0.6% Joseph M. y Cols. 2015. Ann Surg.	1-3% Felekouras E. y Cols. 2015. Gastroenterol Res Pract.	80-97% Felekouras E. y Cols. 2015. Gastroenterol Res Pract.	Cholangiography RM CPRE Gurusamy Ks. and Cols.2015, Cochrane Database Syst Rev.	Collections drainage Lateral hepaticojejunostomy Roux –en. Y with or with out limb (Houston / Chen). Bleeding control and external drainage Abdel Rafee A. and Cols 2015, Int J Surg.

### Treatment

Only about 10 to 27% of these lesions are recognized during surgery, so it is essential to act quickly and always following the principle of beneficence for the patient and his best prognosis.<sup>28</sup> Between the available treatments for these lesions is the hepaticojejunostomy, which is generally used when there is total common bile duct section. Among other options is the primary suture, but this should be done only when there is absolute certainty that has not been compromised blood supply to the common bile duct. When facing small partial injuries, an appropriate treatment may be placing a probe in T, with open or laparoscopic repair, also recommended an endoscopic retrograde cholangiopancreatography to decompression and drainage.

Treatment of iatrogenic bile duct injury is complex and requires a multidisciplinary approach, moreover it requires knowledge of the type of injury, the patient's clinical status, identify whether there are associated vascular lesions, among other local factors; treatment can be surgical or non-surgical. Among other modalities of treatment for such injuries are endoscopic and interventional radiology treatment.<sup>29,32</sup> There are other options, as the percutaneous radiological techniques, however it require bilioenteric continuity, on the other hand is important mention that this method is less invasive, therefore is generally used in patients who are not good candidates for surgical procedures. Treatment can be laparoscopic or conventional according to the surgeon's experience, for total injuries bile duct are recommended biliodigestive derivations.<sup>29,30</sup>



**Table 3: Comparison between sensitivity and Specificity in image studies to diagnosis of bile duct injuries.**

Method	Sensitivity	Specificity	Comment
Ultrasonography	20-90 % Joseph M, and Cols. 2012. Ann Surg	62-100% Joseph M, and Cols. 2012. Ann Surg	Less accurate to determine etiology and level of injury. Rauws EA and Cols. 2006, Ned Tijdschr Geneesk.
Magnetic resonance cholangiopancreatography	91-95% Stewart L. and Cols. 2014, Surg Clin North Am.	98% Stewart L. and Cols. 2014, Surg Clin North Am.	+ Sensitive and less invasive Gold standard. Identify the need or not of an ERCP. Allows visualization of bile duct injury without contrast and ionization energy Stewart L. and Cols. 2014, Surg Clin North Am.
Tomography	78% Mercado MA, y Cols. 2005, ETM.	86% Mercado MA, y Cols. 2005, ETM.	Allows differentiation of the level injury, vascular injury and hepatic hypertrophy. Ruiz Francisco y Cols. 2010, Cir Esp.
Percutaneous transhepatic cholangiography	95.8% Joseph M, and Cols. 2012. Ann Surg	81.2% Joseph M, and Cols. 2012. Ann Surg	Allows visualization of intrahepatic bile duct. Excelent choose for biliary tree, postoperative drainage, catheter placement or both. Used in preoperative setting as routine to elective derivation. Stewart L. and Cols. 2014, Surg Clin North Am.
ERCP	80- 93 % Gurusamy Ks. and Cols.2015, Cochrane Database Syst Rev.	100% Gurusamy Ks. and Cols.2015, Cochrane Database Syst Rev.	Clearly delineates the anatomy, it allows to locate and evaluate the injury. It facilitates reintervention. Minimally invasive technique. No known complications. Gurusamy Ks. and Cols.2015, Cochrane Database Syst Rev.

### **Stents, prostheses and autografts**

Technical innovation in surgery is very important on the quest to achieve optimum outcomes for patients, therefore is essential to introduce new treatments and therapeutic methods. Within new methods to treat a bile duct injury, is a biliary stent, which is a metal or plastic tube inserted into the bile duct as a therapeutic method to injury (stenosis) used to treat bile duct obstruction. Between the methods used to place a biliary stent are endoscopic retrograde cholangiopancreatography and percutaneous transhepatic cholangiography; the endoscopic retrograde cholangiopancreatography besides being a technic of diagnostic imaging has the advantage of being used as a therapeutic device. The percutaneous transhepatic cholangiogram is similar to endoscopic retrograde cholangiopancreatography as both are used to diagnosis and treatment of biliary lesions. It is usually when there is no success with endoscopic retrograde cholangiopancreatography. In over 90% of patients, the biliary stent placement is an excellent treatment of the injury. The rate of severe complications of endoscopic retrograde cholangiopancreatography is approximately 11%, and 10.5% with the percutaneous transhepatic cholangiography.<sup>31</sup>

### **Absorbable prosthesis**

Other method in the management of bile duct injury is the absorbable prosthesis, which is recent in the management of the bile duct, and has had many benefits in iatrogenic benign lesions. They have the advantage of not having to be extracted, or the need to be impregnated with medication, also they show excellent permeability and with this a better prognosis of the injury. Their placement is short; this is useful to avoid chronic inflammatory processes and reduces complications that arise in traditional techniques. They are formed with bioabsorbable materials; some of these are degraded by hydrolysis in the human body and remain intact for at least three months with evidence of total disintegration the following weeks. They are performed with a suture term-terminal of which is dependent on a number of factors such as the presence of the intact proximal and distal ends, diameter similarity between the extremes, a minor injury, and absence of excessive tension. One of the advantages of some prosthesis is the preservation of the length of bile duct.<sup>32</sup> They are placed to achieve the expansion and remodeling of the stenosis.

The disintegration of the prosthesis is produced in approximately 12-16 weeks, which may prevent a recurrence that represents a major risk to the patient.

### **Primary repair**

When the injury is more complex to repair and is proximal, the probability of adjacent vascular injury is higher. In acute injuries, the immediate repair is the best option. When reconstruction and repair is performed at a higher level in a facility with surgical experts, there is greater success rate, shorter hospital stay, morbidity and mortality.

The best time to repair an injury of primary biliary duct is during the initial intervention due to the absence of local inflammation, but the main problem is the size of the bile ducts, which are often thin and not dilated. This requires a specific primary repair. In the case of that exist a section of common bile duct without local inflammation, and is difficult to suture in a first intervention, the elective method is proximal biliary occlusion or temporary ligation clip, wait a few days for a biliary dilatation occurs and reoperation to primary repair. To learn the technique of primary repair to be carried out is necessary an accurate understanding of the mechanism of injury; in some biliary injuries of the wall at the level of primary bile duct, the best way to repair is the primary suture, either vertically for fine vertical or transverse to bile duct injury. In minor injuries, biliary drainage can be omitted. Sutures term-terminal recommended when biliary section without significant loss of substance, where the injury site is in the common bile duct, gall when wall is well vascularized and when there is possibility of a tension-free anastomosis; In this type of suture it is recommended to protect the redress through drainage Kehr. For protection with an external biliary drainage, the use of plastic stent is recommended, which serves as internal biliary drainage. Another alternative is the bilioenteric anastomosis which is used when there is significant loss of gall tissue.<sup>33</sup>

There are situations in which a primary biliary repair is not possible to repair the injury, for example, when there is excessive coagulation it is difficult to ascertain the extension of the lesion, where local conditions of excessive inflammation does not allow a suture without tension, it is permissible in such cases to choose a therapeutic solution that does not merit primary biliary repair, in order to obtain a stenosis of the bile duct and therefore intrahepatic biliary dilatation, making it more suitable a delayed biliary quality repair. This, by placing a suture or a clip, but not before verified by cholangiography, that the drained biliary sector is limited by this channel.

In cases of arterial injury, ischemic liver injury, biliary repair is not recommended because only liver transplantation will solve the problem.

### **DISCUSSION**

Although the incidence of such injuries is low, they are considered important surgical complications, therefore it

is important to find and compare different diagnostic methods and treatment, and get what have been the best choice and impact on progress of patients with bile duct injury, due to it considered a serious accident involving devastating consequences for the patient, an early diagnosis and proper treatment choice improves the prognosis of these surgery accidents.<sup>34</sup>

Among the things of vital importance for the prevention of iatrogenic injury is the detailed knowledge of the anatomy of the bile duct.<sup>35</sup>

The biliary injury is a serious event in laparoscopic surgery, and the prognosis will depend on the type of injury and the complexity of repair. Various techniques have been described for reconstruction and repair, grounded in the type of injury and surgical experience, therefore successful management depends on several factors, including early diagnosis and personalized service, and multidisciplinary management.<sup>33,34</sup>

The bile duct injury lesions are associated with a 20-50% of postoperative morbidity, therefore represents a dangerous condition for the patient, with a significant impact on quality of life and long term psychologically, in the quality of life of patients. Not to mention the possibility of a stenosis, which occurs between 20-40%, leading to a postoperative thorough check.<sup>34</sup>

The biliary-enteric anastomosis that provides the best results is the Roux-Y hepaticojejunostomy, especially when biliary injury occurs with significant tissue loss. It has proven to be a useful technique in the therapeutic treatment of iatrogenic injuries bile duct, and has fewer postoperative complications. It is considered an excellent technique of choice when facing this type of injury, in addition to obtaining good results in approximately 80% of patients.<sup>36</sup>

### **CONCLUSIONS**

Performing an intraoperative cholangiography when injury has been suspected or unknown anatomic location is vital to reduce the incidence of injuries, as well as a good technical mastery to repair injuries. As for how to proceed to improve the prognosis and affect as little as possible the quality of life of a patient with bile duct injury, it must be performed a multidisciplinary management.

Recently the use of absorbable bioprosthesis in experimental animal models seems to be a promising therapeutic alternative to this type of injury, with periodic follow without showing immunological rejection or stenosis.

As doctors and scientists, we are required to develop research and design possible therapeutic strategies for better quality of life in our patients.

*Funding: No funding sources*

*Conflict of interest: None declared*

*Ethical approval: Not required*

## REFERENCES

- Viste A, Ovrebo K, Christensen J, Angelsen H, Hoem D. Bile duct injuries following laparoscopic Cholecystectomy. *SJC.* 2015;103(4):1-5.
- McPartland KJ, Pomposelli JJ. Iatrogenic biliary injuries: classification, identification, and management. *Surg Clin North Am.* 2008;88:1329-31.
- Olariu S. The evolution of concepts in laparoscopic cholecystectomy in a general surgical from Timisoara. *Ann Ital Chir.* 2015;86:126-31.
- González L, Guerra A, Leonher K, Hermosillo J, Jiménez J, Schadegg D. Manejo endoscópico de la lesión de vía biliar. Siete años de experiencia. *Rev Lat Cir.* 2014;4(1):21-5.
- Karnoven J, Gronroos JM, Makitalo L, Koivisto M, Salminen P. Quality of life after iatrogenic bile duct injury. *Minim Invasive Ther Allied Technol.* 2013;22(3):177-80.
- Kohne SN, Lasnier C, Paineau J. Bile duct injuries at laparoscopic cholecystectomy: early repair results. *Ann Chir.* 2005;130(4):218-23.
- Santibañes ED, Ardiles V, Pekolj J. Complex bile duct injuries: management. *HPB.* 2008;10(1):4-12.
- Law WY, Lai EC. Classification of iatrogenic bile duct injury. *Hepatobiliary Pancreat Dis Int.* 2007;6(5):459-63.
- Kwangsik C, Korean J. Recent classifications of the common bile duct injury. *Hepatobiliary Pancreat Surg.* 2014;18:69-72.
- Ramin K, Boetto J, Harnish J, Urbach R. Risk factors for bile duct injury during laparoscopic cholecystectomy: a case-control study. *SURG INNOV.* 2008;2:114-9.
- örnqvist B, Strömberg C, Akre O, Enochsson L, Nilsson M. Selective intraoperative cholangiography and risk of bile duct injury during cholecystectomy. *Br J Surg.* 2015;102(8):952-8.
- Arnaud A, Olivier F, Jerome N, Thierry W, Alain S, Jacques B. Incidence and consequences of an hepatic artery injury in patients with post cholecystectomy bile duct strictures. *Ann Surg.* 2003;238(1):93-6.
- André F, Joao K, Diogo P, Marcus A, Marco B. Comparative analysis of iatrogenic injury of biliary tract in laparotomic and laparoscopic cholecystectomy. *Arq Bras Cir Dig.* 2014;27(4):272-4.
- Connor S, Garden J. Bile duct injury in the era of laparoscopic cholecystectomy. *British J Surg.* 2006;93(2):158-68.
- Parmeggiani D, Cimmino G, Cerbone C, Avenia N, Ruggero R, Gubitosi A. Biliary tract injuries during laparoscopic cholecystectomy: three case reports and literature review. *G Chir.* 2010;31(1-2):16-9.
- Mercado MD. Classification and management of bile duct injuries. *WJGS.* 2011;3(4):43-8.
- Yaghoobian A, Saltmarsh G, Rosing DK, Lewis RJ, Stabile B. Decreased bile duct injury rate during laparoscopic cholecystectomy in the era of the 80-hour resident workweek. *Arch Surg.* 2008;143(9):847-51.
- Tapping RC, Byass RO, Cast JJ. Percutaneous transhepatic biliary drainage (PTBD) with or without stenting complications. *European Radiol.* 2011;21(9):1948-55.
- Flum RD, Patchen D, Cheadle A, Chan L, Koepsell T. Intraoperative cholangiography and risk of common bile duct injury during cholecystectomy. *JAMA.* 2003;289(13):1639-44.
- Kristin M, Sheffield, Taylor SR, Yimei Han, Yongfang Kuo, Courtney M et al. association between cholecystectomy with vs without intraoperative cholangiography and risk of common duct Injury. *JAMA.* 2013;310(8):812-20.
- Vachhani, Copelan, Remer, Kapoor. Iatrogenic hepatopancreatobiliary injuries: a review *Semin Intervent Radiol.* 2015;32(2):182-94.
- Morris G, Mbarushimana S. CT diagnosis of an iatrogenic bile duct injury. *BMJ.* 2014;29:1-2.
- Wael EA, Saad MJ, Wallace JC, Wojak SK. Quality improvement guidelines for percutaneous transhepatic cholangiography, biliary drainage, and percutaneous cholecystostomy. *J Vasc Interv Radiol.* 2010;21(6):789-95.
- Björn T, Stromberg C, Persson G, Magnus N. Effect of intended intraoperative cholangiography and early detection of bile duct injury on survival after cholecystectomy: population based cohort study. *BMJ.* 2012;345:1-10.
- Cozzi G, Severini A, Civelli E. Percutaneous transhepatic biliary drainage in the management of postsurgical biliary leaks in patients with nondilated intrahepatic bile ducts. *Cardiovasc Intervent Radiol.* 2006;29:380-2.
- Jabłońska B, Lampe P. Iatrogenic bile duct injuries: etiology, diagnosis and management. *WJG.* 2009;15(33):4097-104.
- Kaman L, Behera A, Singh R, Katariya R. Management of major bile duct injuries after laparoscopic cholecystectomy. *Surg Endosc.* 2004;18(8):1196-9.
- Hyodo T, Kumano S, Kushihata F, Okada M, Mirata M, Tsuda T et al. CT and MR cholangiography: advantages and pitfalls in perioperative evaluation of biliary tree. *Br J Radiol.* 2012;85(1015):887-96.
- Ríos D, Cruz J, Ureña V, Galindo P. Fast track surgery for biliodigestive derivation: Initial experience. *Int J Hepatobiliary Pancreat Dis.* 2015;5:9-16.
- Jason K, Sicklick M, Melissa S, Keith D, Lillemoe D, Genevieve B et al. Surgical management of bile duct injuries sustained during laparoscopic cholecystectomy. *Ann Surg.* 2005;241(5):786-95.

31. Tashiro H, Ogawa T, Itamoto T, Ushitora Y, Tanimoto Y, Oshita A. Synthetic bio absorbable stent material for duct to duct biliary reconstruction. *Surg Res.* 2009;151(1):85-8.
32. Norkys M, Bourricaudy L, Osvaldo G. Iatrogenic lesions of the biliary tract in laparoscopic surgery. A 10-year experience. *Rev Cub Med.* 2008;37(4):1561-5.
33. Theodoros M, Vasileios K, Konstantinos P, Nikolaos G, Ioannis P. anatomic variations of the right hepatic duct: results and surgical implications from a cadaveric study. *Anatomy Research I.* 2012;2012:1-2.
34. Nuzzo G, Giulante F, Giovannini I, Murazio M, D'Acapito F, Ardito M et al. Advantages of multidisciplinary management of bile duct injuries occurring during cholecystectomy. *J Surg.* 2008;195(6):763-9.
35. Losada H, Muñoz C, Burgos L, Silva J. Reconstrucción de lesiones de vía biliar principal. La evolución hacia la técnica de Hepp – Couinaud. *Rev Chil Cir.* 2011;63(1):48-51.
36. Zamorano JV. Hepatoyeyuno anastomosis en Y de Roux laparoscópica para la reconstrucción de una lesión de la vía biliar. Reporte de un caso y revisión de la literatura. *Cir Gen.* 2014;36(1):39-43.

**Cite this article as:** Granados-Romero JJ, Estrada-Mata AG, Espejel-Deloiza M, Ceballos-Villalva JC, Contreras-Flores EH, León-Mancilla B, et al. Current perspective in the treatment of bile duct injuries. *Int J Res Med Sci* 2016;4:677-84.