

## Case Report

# Disseminated cysticercosis with neurocysticercosis: a rare presentation diagnosed by fine needle aspiration cytology

Shipra Singhal, Shweta Shushmita\*, Preeti Sharma

Department of pathology, VMMC and Safdarjung Hospital, New Delhi, India

**Received:** 00 May 2019

**Accepted:** 00 June 2019

### \*Correspondence:

Dr. Shweta Shushmita,

E-mail: [shweta.sushmita@yahoo.in](mailto:shweta.sushmita@yahoo.in)

**Copyright:** © the author(s), publisher and licensee Medip Academy. This is an open-access article distributed under the terms of the Creative Commons Attribution Non-Commercial License, which permits unrestricted non-commercial use, distribution, and reproduction in any medium, provided the original work is properly cited.

## ABSTRACT

Disseminated cysticercosis is a rare presentation of human *T. Solium* infection in which the parasite disseminates via the blood stream throughout the human body. The various clinical manifestations depend upon the location of the parasitic cyst inside the body. Neurocysticercosis is the most common parasite disease of the central nervous system. Disseminated cysticercosis with neurocysticercosis is a very rare presentation of human cysticercus infection. Here we present such a rare case in which a young man presented with multiple swellings all over the body and a history of seizures. Fine needle aspiration cytology was done and the diagnosis was established.

**Keywords:** Disseminated cysticercosis, FNAC, Neurocysticercosis, Seizures

## INTRODUCTION

Human cysticercosis is a deadly infestation which occurs due to the ingestion of eggs of the parasite *Taenia solium*.<sup>1</sup> It is endemic in Asia, Mexico, Central and South America, and parts of Africa.<sup>2,3</sup>

The life cycle of the pork tapeworm, *Taenia solium*, begins at the larval stage in pigs. Humans are infected when *Taenia solium* cysts are ingested along with the ingestion of undercooked pork. The larvae attach to the human gut and grow into adult tapeworms. The adult tapeworm then sheds proglottids into human faeces which can contaminate the environment. Pigs acquire infection by eating vegetation contaminated by eggs and proglottids of *T. solium*. Eggs ingested by pigs develop into the larval stage. The larvae travel through the intestinal wall and enter the bloodstream. They lodge in various tissues, and develop into cysts.<sup>4,5</sup>

When humans ingest undercooked pork, the cysts are also ingested along with the undercooked meat. Humans become the dead-end hosts of the larval stage of the parasite and develop cysticercosis like pigs.<sup>6,7,8</sup> Fecal-oral contamination can also occur in farm workers who do not wash their hands properly before eating or in people who ingest fruit and vegetables which are contaminated with infected human waste. Autoinfection involves the retrograde transmission of proglottids from the intestines into the stomach with subsequent release of *T. solium* eggs into the human gut.

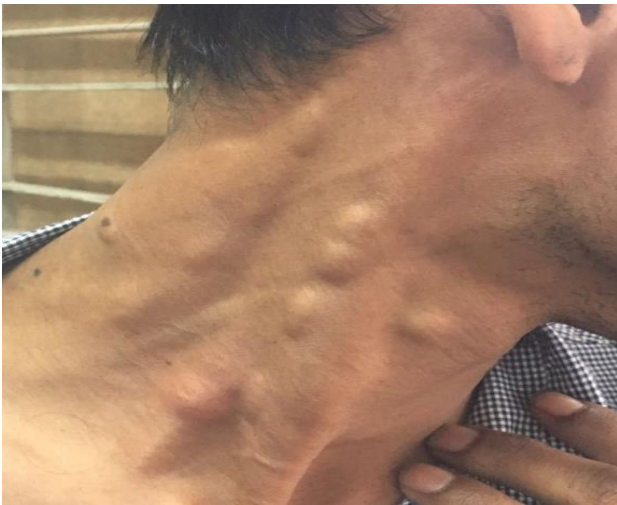The clinical features depend on the location where the cysts lodge inside the body. Cysts can lodge in the brain and spinal column, eyes, skeletal muscle, and subcutaneous tissues.<sup>8,9</sup>

Central nervous system involvement is seen in 60-90% of patients with cysticercosis while 50-70% have epilepsy.<sup>10-12</sup> However, association of neurocysticercosis with disseminated cysticercosis is not very common and

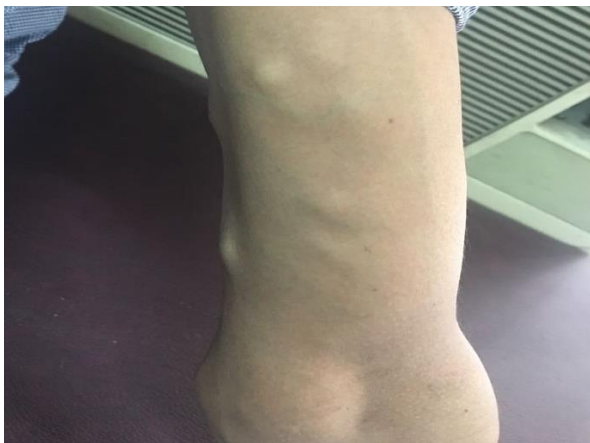fewer than 50 cases of disseminated cysticercosis have been reported in the world.<sup>13</sup>

### CASE REPORT

A 26 year old male came to surgery OPD with a complaint of multiple swellings all over the body including the tongue, neck, arms, legs, back and the abdomen (Figure 1,2). He also had a history of seizures for 2 years. He was a non-vegetarian and consumed pork and meat regularly. There was no history of chronic cough, chronic diarrhoea, weight loss, decreased appetite or any past history suggestive of diabetes, hypertension and tuberculosis.



**Figure 1: Patient with swellings seen on the side of neck.**

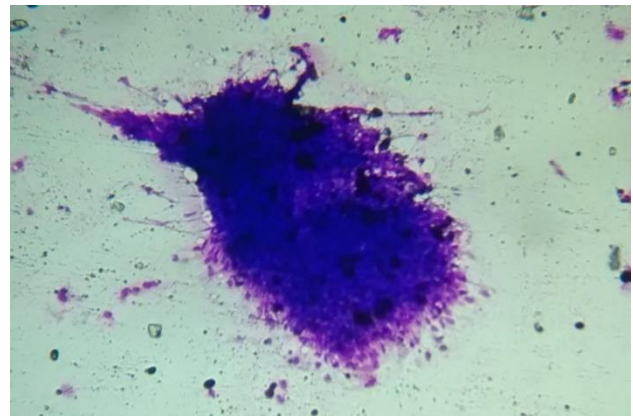


**Figure 2: Multiple swellings seen on forearm.**

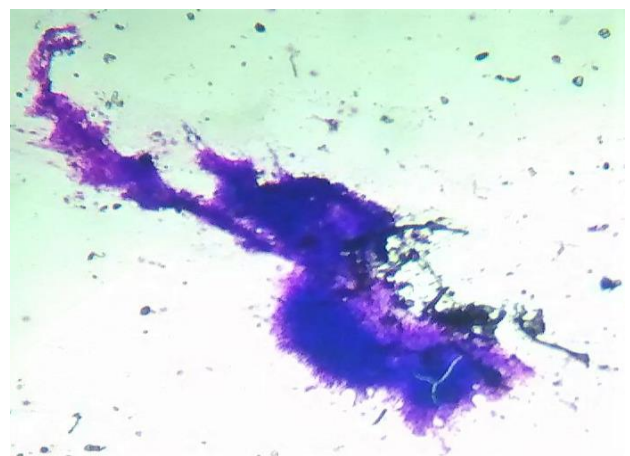
On examination multiple swellings were seen all over the body, largest measuring 2x2 cm and smallest measuring 0.5x0.5 cm in size. They were soft in consistency and were well circumscribed. Systemic examination was within normal limits. There was no apparent deficit in attention, orientation, memory, and judgment. Routine hemogram showed normal haemoglobin and normal

TLC. Differential leucocyte count showed mild eosinophilia. All other investigations were within normal limits. Computerized tomography (CT) scan of the brain showed multiple cystic lesions in the parenchyma of the brain. Magnetic resonance imaging (MRI) scan was done and it showed multiple cysts in the brain, scalp tissue, orbit and neck muscles.

The patient was advised fine needle aspiration cytology (FNAC) from the subcutaneous skin nodules. During aspiration, clear looking fluid was aspirated and the swellings reduced in size after aspiration of the fluid. The smears were air dried and were stained with Giemsa stain. Smears showed fragments of fibrillary bluish material with interspersed small nuclei. The background comprised of mixed inflammatory cells infiltrate consisting of neutrophils, eosinophils, lymphocytes, and histiocytes surrounding the fibrillary material (Figure 3,4). A final diagnosis of disseminated cysticercosis was made.



**Figure 3: Fragments of fibrillary bluish material with interspersed small nuclei (Giemsa 40X).**



**Figure 4: Larger parasitic fragment (Giemsa 40X).**

The patient was treated with a tapering dose of prednisolone started a week earlier to albendazole at a dose of 1 mg/kg body weight and albendazole 15 mg/kg body weight. The condition of the patient showed marked

improvement after 10 days. There was no development of new swellings and the older swellings showed reduction in size. There was no deterioration in neurological or intellectual status. The patient was discharged after observation in the hospital. No side effects were observed. On follow-up, after six months, there was significant improvement in the patient.

## DISCUSSION

Widespread dissemination of cysticerci throughout the body can take place when the embryos of cysticerci migrate through the intestinal wall and enter the blood stream and then to the rest of the body. The organs most commonly affected are subcutaneous tissues, skeletal muscles, the lungs, the brain, eyes, the liver and occasionally the heart. Widespread dissemination of the cysticerci can result in the involvement of almost any organ of the body. The diagnosis of disseminated cysticercosis can be considered to be confirmed if there are multiple vesicular cystic lesions present in the brain and cysts are demonstrated in at least two other body parts.<sup>14</sup>

The clinical presentation depends on the location of the cysts inside the body. The main features include intractable epilepsy, dementia, enlargement of muscles, subcutaneous and lingual nodules and a relative absence of focal neurological signs or obviously raised intracranial pressure, at least until late in the disease.<sup>15,16</sup>

Computed tomography scans and magnetic resonance imaging (MRI) are useful in anatomical localization of the cysts. An MRI is more sensitive than a CT, as it identifies scolex and live cysts in cisternal spaces and ventricles and identifies the response to treatment. Unenhanced CT scans of the muscles can show innumerable cysts standing out against the background of the muscle mass in which they are embedded. CT image appears like a honeycomb or leopard spots. The radiological findings of cysticercosis – a cystic lesion with a central nodule that represents the scolex – are very similar in all affected organs. On MRI, cysticercosis lesions appear hyperintense with well-defined edges, which show a hypointense eccentric nodule within, representing the dead parasite's head, which is called the scolex. The presence of a scolex in a cystic lesion usually suggests the diagnosis of cysticercosis.<sup>17</sup>

FNAC is an extremely useful modality in the diagnosis of parasitic infections. The pork tapeworm *T. solium* can cause two distinct forms of infection. The form which develops depends on whether humans are infected with tapeworms in the intestine or with larval forms in the tissues (cysticerci). Scolex of cysticercus is large, almost 1 mm in size. It has a rostellum and four suckers. Finding an entire scolex in a fine-needle aspirate is a rare event.<sup>18</sup> The rostellum has two rings of alternating large and small hooklets. The growing parasite may provoke a series of inflammatory reactions including infiltration by

polymorphs, eosinophils, lymphocytes, plasma cells, giant cells, and macrophages followed by fibrosis and necrosis of capsule with eventual death and calcification of the larva.

Essential for the cytodagnosis of cysticercosis on FNAC is the identification of the parasitic fragments including its wall and hooklets. Parasitic fragments may comprise bluish, fibrillary structures, sometimes with honeycombing, calcospherules, tegument thrown into rounded wavy folds, scolex with hooklets and hyaline membrane surrounding it. The inflammatory reaction consists of eosinophils, neutrophils, lymphocytes, histiocytes, epithelioid cells, and giant cells in varying proportions.<sup>19,20,21</sup> A careful search for parasitic fragments should be carried out in the presence of polymorphous inflammatory infiltrate composed predominantly of eosinophils and histiocytes.

Kapila et al, studied aspirates from 182 cases of subcutaneous cysticercosis and semiquantitated the type and degree of inflammatory response and the amount and preservation of the parasite. They concluded that the tissue response is variable with 88-92% being eosinophils, 50-70% palisading histiocytes, 68-80% epithelioid cell granulomas, and 46-74% giant cells.<sup>22</sup> The tissue response to cysticercus has been divided into five stages.<sup>23</sup> The initial response comprises macrophages and lymphocytes followed by a well-formed layer of palisaded histiocytes. As the inflammatory response becomes chronic, eosinophils appear. Later, polymorphs invade the necrotizing parasite. Finding the parasite bladder wall, hooklets, and intact larva on FNAC obviates the need for histopathological examination. Hence, FNAC is a rapid, cost-effective, and safe procedure to diagnose cysticercosis and prevent fatal neurological complications.

Management of disseminated cysticercosis include symptomatic treatment of the central nervous system lesions using steroids and antiepileptics. In patients with raised intracranial tension, surgical removal of cysts and ventriculoperitoneal shunting can alleviate the symptoms. Pharmacological management include cysticidal drugs like Praziquantel (10-15 mg/kg/day for 6-21 days) and Albendazole (15 mg/kg/day for 30 days). Pharmacological treatment may be associated with severe reactions which may cause enlargement and rupture of the cysts leading to massive release of antigens causing local tissue swelling, and a generalized anaphylactic reaction. Priming with corticosteroids before starting the cysticidal drug, decreases the incidence of such complications.<sup>24,25</sup>

## CONCLUSION

FNAC is a widely acceptable method for the diagnosis of parasitic lesions. Aspiration of clear fluid is a strong indicator of a parasitic infection in a palpable subcutaneous or intramuscular nodule, which provides a

clue for the diagnosis of cysticercosis. The possibility of cysticercosis should be kept in during assessment of all inflammatory and cystic swellings.

*Funding: No funding sources*

*Conflict of interest: None declared*

*Ethical approval: Not required*

## REFERENCES

1. Arora PN, Sanchette PC, Ramakrishnan KR, Venkataram S. Cutaneous, mucocutaneous and neurocutaneous cysticercosis. *Ind J Dermatol, Venereol, Leprol.* 1990;56(2):115.
2. Garcia HH, Del Brutto OH. Taenia solium cysticercosis. *Infectious dis clin North Am.* 2000;14(1):97-119.
3. Sawhney IM, Singh G, Lekhra OP, Mathuriya SN, Parihar PS, Prabhakar S. Uncommon presentations of neurocysticercosis. *J neurol sci.* 1998;154(1):94-100.
4. García HH, Gonzalez AE, Evans CA, Gilman RH, Cysticercosis Working Group in Peru. Taenia solium cysticercosis. *The lancet.* 2003;362(9383):547-56.
5. Nash TE, Del Brutto OH, Butman JA, Corona T, Delgado-Escueta A, Duron RM, Evans CA, Gilman RH, Gonzalez AE, Loeb JA, Medina MT. Calcific neurocyst epileptogen. *Neurol.* 2004;62(11):1934-8.
6. Castillo M. Imaging of neurocysticercosis. *Semin Roentgenol* 2004;39:465-73.
7. Hawk MW, Shahlaie K, Kim KD, et al. Neurocysticercosis: a review. *Surg Neurol.* 2005;63:123-32.
8. Sharma T, Sinha S, Shah N, Gopal L, Shanmugam MP, Bhende P, et al. Intraocular cysticercosis: clinical characteristics and visual outcome after vitreoretinal surgery. *Ophthalmol.* 2003;110(5):996-1004.
9. Singhi P, Singhi S. Neurocysticercosis in children. *J Child Neurol* 2004;19:482-92.
10. King DT, Gilbert DJ, Gurevitch AW, et al. Subcutaneous cysticercosis. *Arch Dermatol.* 1979;115:236.
11. García HH, Del Brutto OH. Imaging findings in neurocysticercosis. *Acta tropica.* 2003;87(1):71-8.
12. Schmidt DK, Francois Jordaan H, Schneider JW, Cilliers J. Cerebral and subcutaneous cysticercosis treated with albendazole. *International J dermatol.* 1995;34(8):574-9.
13. Garg S, Kathuria H, Sachdeva S, et al. Disseminated Cysticercosis - A Case Report. *Ann. Int. Med. Den. Res.* 2017; 3(1):ME01-ME03.
14. Garg RK. Diagnostic criteria for neurocysticercosis: some modifications are needed for Indian patients. *Neurol Ind.* 2004;52(2):171.
15. Baily GG. Cysticercosis. *Manson's Tropical Disease.* Saunders. 2003;21:1584-95.
16. Krishnaswami CS. Case of Cysticercus cellulose. *Ind Med Gaz.* 1912;27: 43-44.
17. Bothale KA, Mahore SD, Maimoon SA. A rare case of disseminated cysticercosis. *Trop parasitol.* 2012;2(2):138.
18. Singh N, Arora VK, Bhatia A. Are all subcutaneous parasitic cysts cysticercosis?. *Acta Cytologica.* 2006;50(1):114.
19. Nigam S, Singh T, Mishra A, Chaturvedi KU. Oral cysticercosis-report of six cases. *Head & neck.* 2001;23(6):497-9.
20. Kamal MM, Grover SV. Cytomorphology of subcutaneous cysticercosis. A report of 10 cases. *Acta cytologica.* 1995;39(4):809-12.
21. Arora VK, Gupta K, Singh N, Bhatia A. Cytomorphologic panorama of cysticercosis on fine needle aspiration. A review of 298 cases. *Acta cytolog.* 1994;38(3):377-80.
22. Kapila K, Sahai K, Verma K. Semi-quantitative analysis of soft-tissue reactions in fine needle aspirates from tissue cysticercosis. *Cytopathol.* 2003;14(4):208-11.
23. Mahmood SA, Thomas JA. Host-parasite relationship in human cysticercosis. *Ind J Med Res.* 1984;80:532.
24. Bhalla A, Sood A, Sachdev A, Varma V. Disseminated cysticercosis: a case report and review of the literature. *J Med case Rep.* 2008;2(1):137.
25. Banu A, Veena N. A rare case of disseminated cysticercosis: Case report and literature review. *Ind J Med microbiol.* 2011;29(2):180.

**Cite this article as:** Singhal S, Shushmita S, Sharma P. Disseminated cysticercosis with neurocysticercosis: a rare presentation diagnosed by fine needle aspiration cytology. *Int J Res Med Sci* 2019;7:3595-8.