

Original Research Article

Histomorphological spectrum of prostatic lesions: a retrospective analysis of transurethral resection of prostate specimens

Anuja Sharma, Mahima Sharma*, Shivani Gandhi,
Arvind Khajuria, K. C. Goswami

Department of Pathology, Acharya Shri Chander College of Medical Sciences and Hospital, Sidhra, Jammu, J&K, India

Received: 21 April 2017

Revised: 01 May 2017

Accepted: 06 May 2017

*Correspondence:

Dr. Mahima Sharma,

E-mail: mahimasarup@yahoo.co.in

Copyright: © the author(s), publisher and licensee Medip Academy. This is an open-access article distributed under the terms of the Creative Commons Attribution Non-Commercial License, which permits unrestricted non-commercial use, distribution, and reproduction in any medium, provided the original work is properly cited.

ABSTRACT

Background: Prostatic diseases like inflammation, benign prostatic hyperplasia and tumors are important causes of mortality and morbidity in males. The incidence of these lesions increases with advancing age. The second most common cancer among males is prostate cancer, next to lung cancer worldwide. Transurethral resection of prostate (TURP) is most frequently performed surgical procedure in the clinical practice. The purpose of the study is to evaluate histomorphological spectrum of prostate lesions in TURP specimen with focus on premalignant lesions and incidental carcinomas.

Methods: The present study includes 245 cases of TURP specimen from January 2015 to December 2016 received in the post graduate department of pathology, ASCOMS and Hospital. H and E stained sections were examined. The relevant clinical details pertaining to age, clinical complaints and microscopic details were analysed and compared with other similar studies.

Results: Of the total 245 TURP specimen, 223 (91.02%) were of nodular hyperplasia, 14 (5.71%) were of prostatic intraepithelial neoplasia and 8 (3.26%) cases were malignant. Benign hyperplasia of prostate (BHP) alone accounted for 91.02% of TURP specimen. Less frequent findings were granulomatous prostatitis in 3.70% and atypical adenomatous hyperplasia (1.22%). All the 8 cases of prostate cancer were incidental carcinoma, 5 of which were poorly differentiated and 3 were moderately differentiated adenocarcinoma.

Conclusions: The present study showed that non-neoplastic lesions of prostate are more common than neoplastic ones. The most frequently encountered prostatic lesion was BHP, commonly seen in the age group of 61-70 years. The malignant lesions were common among the males of more than 60 years. TURP can be helpful in early identification of premalignant lesions and incidental prostate cancer which can improve the treatment outcome of patients.

Keywords: Incidental prostate carcinoma, Nodular hyperplasia, Prostatitis, PIN, TURP

INTRODUCTION

Prostate is one of the most commonly affected organs in males with increasing age, accounting for significant morbidity and mortality. The most important categories

of prostatic diseases are inflammatory lesions (prostatitis), nodular hyperplasia (benign prostatic hyperplasia), and carcinoma. Transurethral resection of prostate (TURP) specimens form a significant percentage of diagnostically challenging cases in surgical pathology.¹

TURP is a common urological procedure primarily used for the surgical management of benign prostatic hyperplasia (BPH).²

BPH represents nodular enlargement of the prostate caused by proliferation of both glandular and stromal components. The incidence of BPH increases with age, being only 8% during the fourth decade, 50% in the fifth decade and upto 75% in the eighth decade.³ Prostatitis occurs in approximately 10% to 15% of men.⁴ It may be classified as acute, chronic and granulomatous and is a common finding associated with BPH.

The understanding of biology of premalignant lesions has become increasingly important. These precursor lesions have recently been attributed to the concept of the multistep carcinogenesis of prostate cancer. Two premalignant lesions have been recognized: prostatic intraepithelial neoplasia (PIN) and atypical adenomatous hyperplasia (AAH). Orteil gave the first description of premalignant changes in prostate. The term prostatic intraepithelial neoplasia was endorsed. It is defined as a cytological alteration in architecturally normal glands and is further categorized into low grade (LGPIN) and high grade (HGPN). AAH was first described by McNeal and it represents an architectural alteration in cytologically unremarkable glands.^{3,5,6} Carcinoma of prostate is ranked the second most common cause of cancer related deaths in men older than 50 years, the incidence of which increases with increasing age.⁷ The presence of tumor in TURP specimen may be due to extensive spread by conventional carcinoma of the peripheral zone of the gland or may be a manifestation of the uncommon carcinoma of transitional zone.³ Clinically in apparent prostate tumors that are incidentally diagnosed in TURP specimens are referred to as incidental carcinoma of the prostate.^{8,9}

The present study was conducted with an aim to enumerate histomorphological spectrum of prostatic lesions in TURP specimens.

METHODS

The study was conducted in the Post Graduate Department of Pathology, ASCOMS and Hospital, after obtaining due clearance from Institutional Ethics Committee. The study consisted of retrospective analysis of all the TURP specimens received in the department from January 2015 to December 2016. All histopathological data, pertaining to TURP specimens maintained in the histopathology section of the department of pathology were retrieved and reviewed. haematoxylin and eosin (H and E) stained microscopic sections were re-examined. New H and E stained paraffin sections were made wherever required such as in case of faded slides. All relevant clinical details were obtained from the respective requisition forms submitted in the pathology department. Each case was analyzed with respect to age, clinical presentation and microscopic

examination. The various lesions of prostate were listed and the focus was on histological types of hyperplasia, inflammation, pre-malignant and malignant lesions. Incidentally detected prostate cancers were classified using Gleason's score. Prostatectomy specimens and prostatic biopsies were excluded from our study.

RESULTS

Our analysis included 245 cases of TURP specimens received in our department, during a 2-year period from January 2015 to December 2016. Out of these 245 cases, 223 (91.02%) were of nodular hyperplasia (BPH), 14 cases (5.71%) were of PIN and 8 cases (3.26%) were malignant (Table 1).

Table 1: Histomorphological spectrum in TURP specimens.

| Histopathological diagnosis | No. of cases | Percentage |
|-----------------------------|--------------|------------|
| Nodular hyperplasia | | |
| Without prostatitis | 139 | 56.73% |
| With prostatitis | 81 | 33.06% |
| AAH | 03 | 1.20% |
| PIN | | |
| LGPIN | 09 | 3.6% |
| HGPN | 05 | 2.04% |
| Incidental carcinoma | 08 | 3.26% |
| Total | 245 | 100 |

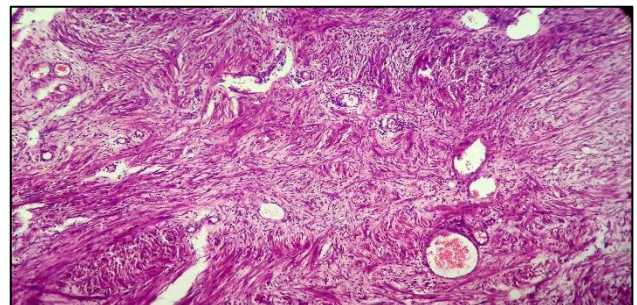


Figure 1: Nodular hyperplasia with stromal predominance (H and E stain, x100).

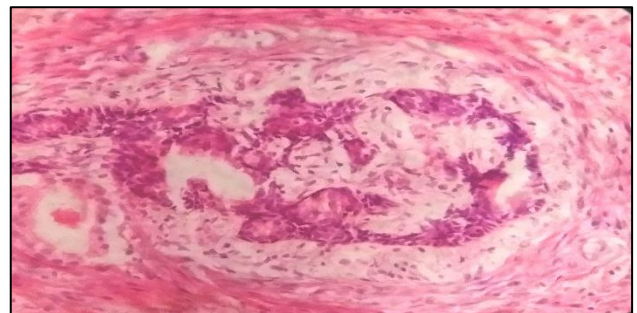


Figure 2: Basal cell hyperplasia showing glands with small darkly stained basal cells with peripheral palisading (H and E stain, x400).

Most (83 cases) of the TURP specimens were obtained from the patients in the age group of 61-70 years accounting for 33.87% followed by 80 cases in 71-80 years of age constituting 32.65%. The most common age group presenting with benign prostatic hyperplasia was 61-70 years with 76 cases (31.02%) followed by 71-80 years with 72 cases (29.38%). Maximum number of cases

of LGPIN were seen in the age group of 61-70 years i.e., 4 cases which constituted 1.63%. 2 cases each of HGPIN were observed in ages between 71-80 years and 81-90 years. The youngest patient in our study was of 39 years and the oldest was 92 years of age. Age distribution of cases is depicted in Table 2.

Table 2: Age wise distribution of prostatic lesions.

| Age group (in years) | Nodular hyperplasia | | AAH | PIN | | Incidental carcinoma | Total |
|----------------------|---------------------|------------------|-----|-------|-------|----------------------|-------|
| | Without prostatitis | With prostatitis | | LGPIN | HGPIN | | |
| <40 | 00 | 01 | 00 | 00 | 00 | 00 | 01 |
| 41-50 | 08 | 08 | 00 | 00 | 00 | 00 | 16 |
| 51-60 | 18 | 19 | 00 | 02 | 00 | 00 | 39 |
| 61-70 | 50 | 25 | 01 | 04 | 01 | 02 | 83 |
| 71-80 | 48 | 22 | 02 | 02 | 02 | 04 | 80 |
| 81-90 | 14 | 06 | 00 | 01 | 02 | 02 | 25 |
| >90 | 01 | 00 | 00 | 00 | 00 | 00 | 01 |
| Total | 139 | 81 | 03 | 09 | 05 | 08 | 245 |

Table 3: Distribution of cases of prostatitis.

| Types of prostatitis | Number of cases | Percentage (%) |
|---------------------------|-----------------|----------------|
| Chronic prostatitis | 70 | 86.42 |
| Acute prostatitis | 08 | 9.88 |
| Granulomatous prostatitis | 03 | 3.70 |
| Total | 81 | 100 |

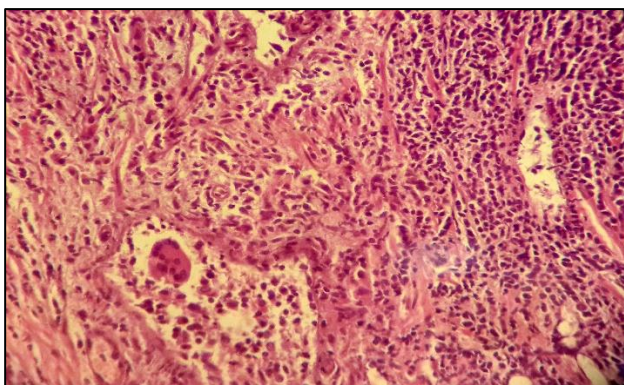


Figure 3: Non-specific granulomatous prostatitis showing multinucleated giant cell and histiocytes (H and E stain, x400).

BPH was the most frequent histological finding observed constituting a total of 223 (91.02%) cases. Microscopic features associated with BPH were observed and changes found included mixed hyperplasia, predominant stromal or glandular component, cystic dilatation of glands, corpora amylacea, squamous metaplasia, basal cell

hyperplasia, AAH and inflammation (Figure 1 and Figure 2).

Prostatitis was categorized into acute, chronic and granulomatous (Table 3). Nodular hyperplasia alone was seen in 139 cases (56.73%) followed by nodular hyperplasia with prostatitis which was observed in 81 cases (33.06%). Chronic prostatitis was most commonly seen to be associated with nodular hyperplasia i.e., in 70 of 81 cases (86.42%) of BPH with prostatitis. These cases showed diffuse infiltration of glands and stroma by mononuclear infiltrate of lymphocytes, plasma cells and histiocytes. Acute prostatitis was observed in 8 cases (9.88%) of BPH which showed neutrophilic infiltrate involving the glands as well as stroma. 3 cases (3.70%) were associated with granulomatous prostatitis which showed presence of granulomas and multinucleated giant cells (Figure 3). Only 3 cases (1.22%) showed changes of AAH.

In the present study, 14 cases (5.71%) showed PIN. These were further classified using current concept of low grade and high grade PIN. Nine cases (3.67%) were of LGPIN and 5 cases (2.04%) were of HGPIN (Figure 4).

Prostatic carcinoma was diagnosed in 8 patients (3.26%). All these were histologically adenocarcinomas. These cases were previously not suspected of malignancy and were detected incidentally on TURP specimens. Five of these cases had poorly differentiated adenocarcinoma with Gleason's score of more than 7 while 3 cases had moderately differentiated adenocarcinoma with Gleason's

score of 7 (Figure 5). All the cases were above the age of 60 years.

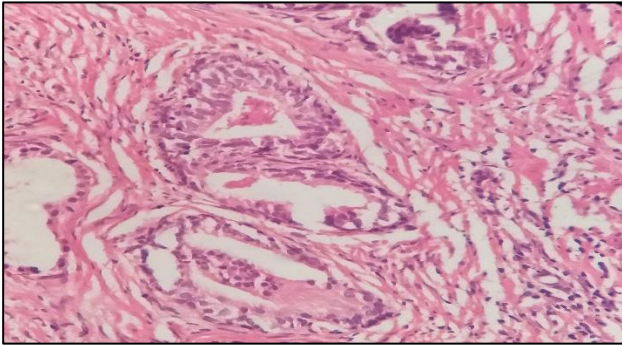


Figure 4: High grade PIN (H and E stain, x400).

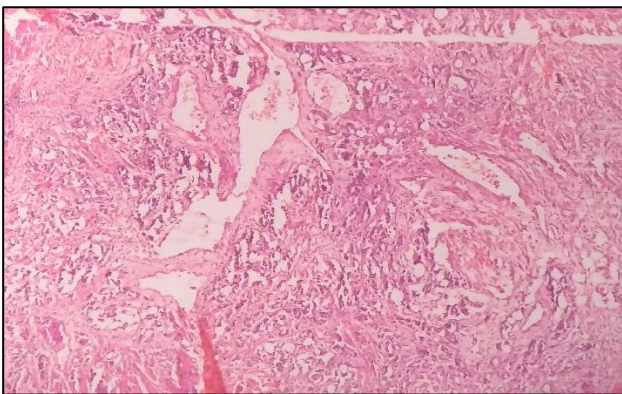


Figure 5: Adenocarcinoma Prostate, Gleason's grade 7 (H and E stain, x400).

DISCUSSION

Prostate is a fibromuscular organ and have three major glandular regions- peripheral zone, central zone and transitional zone. Prostatic hyperplastic lesions are common in transition zone and peripheral zone is the main site for carcinomas.⁷ Important diseases associated with prostate includes benign nodular hyperplasia, inflammation and tumors. Incidence of prostatic diseases increases with increasing age.

In the present study, 245 TURP specimens were analysed. Benign lesions were more common compared to malignancies which is similar to most other Indian studies.^{1,10,11} We observed 223 (91.02%) cases of BPH, 14 cases (5.71%) of PIN and 8 cases (3.26%) of prostate adenocarcinoma. Thapa N et al and Begum Z et al also evaluated only TURP specimens in their respective studies.^{12,13}

Thapa N et al in their study found 92.2% cases were of BPH, 4.8% were prostatic cancers and these observations were comparable with our findings.¹² Begum Z et al also observed almost similar percentage of BPH and adenocarcinoma cases constituting 96% and 4% respectively.¹³

The age of the patients in our study ranged from 39 years to 92 years. Majority of the cases were encountered in the age group of 61-70 years followed by 71-80 years. This corroborates with findings of Shirish C et al, Thapa N et al and Josephine A.^{1,12,14} BPH cases were maximum in the seventh decade in our study which was similar to observations made by Kasliwal N et al, Arya RC et al, Kumar M et al.¹⁵⁻¹⁷ PIN was noted in our study, between 61-80 years with maximum number of HGPIN cases in 71-80 years age group and LGPIN cases in 61-70 years age group. This correlates with the study of Khatib W et al.¹⁸ We observed that the commonly affected age group by malignancy was 71-80 years which was similar to findings of Kasliwal N et al and Deshmukh BD et al.^{15,19}

BPH represents nodular enlargement of the prostate caused by hyperplasia of glandular and stromal components.³ The most predominant lesion of prostate in our study was BPH, noted in 91.02% of the cases. Majority of the cases of BPH showed a mixed pattern of hyperplasia involving both adenomatous and fibromuscular component which was comparable with Deshmukh BD et al and Mittal BV et al.^{19,20} Corpora amylacea was present in most of the cases of BPH. Metaplastic changes comprising of squamous or transitional epithelium were noted in 20 cases. One case showed predominantly stromal hyperplasia with scant glandular elements. One case of basal cell hyperplasia was also seen. Similar changes were found in other studies.^{1,19-21}

Prostatitis with BPH was seen in 81 cases (33.06%). Chronic non-specific inflammation was seen in majority of the cases of BPH with prostatitis (86.42%). Acute inflammation was seen in 9.88% cases. Non-specific granulomatous prostatitis was noted in 3 cases (3.70%). These findings are similar to the studies of Kasliwal N, Mathi A et al and Puttaswamy K et al.^{15,21,22}

AAH (also known as adenosis) is a common mimicker of adenocarcinoma prostate.^{3,23} It is usually an incidental histological finding, mostly localized in the transition zone and thereby seen more often in TURP specimens.²³ AAH, at low magnification appears as complex and disorderly cluster of glands with an expansile margin having minimal infiltration at perimeter but no cytological atypia.^{3,24} The incidence of AAH in our research was noted to be 1.22% which correlates with the findings reported by Puttaswamy K et al (2%) and Garg et al (1.65%).^{21,25}

PIN is defined as a cytological alteration in architecturally normal glands. Currently, it is grouped into two categories: LGPIN and HGPIN. The most important feature in distinguishing HGPIN from LGPIN is nuclear (especially nucleolar) appearance, regardless of architecture.³ In present study, 14 cases (5.71%) showed PIN out of which nine cases (3.67%) were of LGPIN and 5 cases (2.04%) were of HGPIN. Gaudin PB et al reported the incidence of HGPIN to be 2.3% in all TURP

specimens which correlates with our findings.²⁶ A wide variation in the incidence and prevalence of PIN in nodular hyperplasia has been reported in the world literature, ranging from 12.8% to 43% in different studies.⁵ However, number of PIN cases noted in our study was low which could be due to the fact that we analysed only TURP specimens. The occurrence of PIN in TURP specimens as such is reported to be relatively low (2-4%).⁶ It is suggested that in cases of PIN, especially higher-grade, patients need close follow-up observations and investigations to rule out existence of carcinoma, especially in the peripheral zone.

Carcinoma of prostate is the second most common malignancy in males. Incidental detection of prostate cancer during TURP has decreased significantly in the era of PSA screening. Prior to the introduction of prostate specific antigen (PSA), detection rate of incidental carcinoma has been reported upto 27% in literature. However, in PSA era, the rate of detection of incidental prostate cancer on TURP has been reported to be 4.1-16.7%.^{9,12,27} Most prostatic cancers arise from peripheral zone and tumors detected exclusively in transitional zone account only for 2-7%. In the present study, prostatic carcinoma was diagnosed in 8 patients (3.26%). These cases were previously not suspected of malignancy and were detected incidentally on TURP specimens. Five of these cases had poorly differentiated adenocarcinoma with Gleason's score of more than 7 while 3 cases had moderately differentiated adenocarcinoma with Gleason's score of 7. Comparable results were reported by Thapa N et al and Begum Z et al.^{12,13}

CONCLUSION

The present study focused on non-malignant as well as premalignant lesions of prostate and incidentally detected carcinomas in TURP specimens. BPH was the commonest benign lesion encountered in TURP chips. PIN is relatively uncommon in TURP specimens as was also observed in this study. It is suggested that the presence of high-grade PIN in the adenomatous zone in cases of nodular hyperplasia requires a follow-up for concurrent or subsequent invasive carcinoma. Prostatic tissue removed for clinically diagnosed BPH when on histopathological examination reveals carcinoma, it is termed as incidental carcinoma. All prostate carcinomas in this study were incidental. To increase the probability of detection of incidental carcinoma, more TURP chips should be sampled for histopathological examination. In such cases, needle biopsy should be done to look for additional cancer in the peripheral zone. Identification of premalignant lesions and incidental prostate cancer can improve the treatment outcome of patients.

Funding: No funding sources

Conflict of interest: None declared

Ethical approval: The study was approved by the Institutional Ethics Committee

REFERENCES

1. Shirish C, Jadhav PS, Anwekar SC, Kumar H, Buch AC, Chaudhari US. Clinico-pathological study of benign and malignant lesions of prostate. *IJPBS*. 2013;3:162-78.
2. Trpkov K, Thompson J, Kulga A, Yilmaz A. How much tissue sampling is required when unsuspected minimal prostate carcinoma is identified on transurethral resection? *Arch Pathol Lab Med*. 2008;132:1313-6.
3. Rosai J. Male reproductive system. In: Rosai J, editor. *Rosai and Ackerman's Surgical Pathology*. 10th ed. New Delhi: Elsevier; 2011:1287-1333.
4. Harik LR, O'Toole KM. Nonneoplastic lesions of the prostate and bladder. *Arch Pathol Lab Med*. 2012;136:721-34.
5. Rekhi B, Jaswal TS, Arora B. Premalignant lesions of prostate and their association with nodular hyperplasia and carcinoma prostate. *Ind J Cancer*. 2004;41:60-5.
6. Silverio FD, Gentile V, Matteis AD, Mariotti G, Giuseppe V, Luigi PA, et al. Distribution of inflammation, pre-malignant lesions, incidental carcinoma in histologically confirmed benign prostatic hyperplasia: a retrospective analysis. *Eu Urol*. 2003;43:164-75.
7. Epstein JI, Lotan TL. The lower urinary tract and male genital system. In: Kumar V, Abbas AK, Aster JC, editors. *Robbins and Cotran Pathologic Basis of Disease*. 9th ed. New Delhi: Elsevier; 2014:980-990.
8. Pethiyagoda AUB, Pethiyagoda K. Incidental prostate cancer experience of a tertiary unit in Sri Lanka. *IJSRP*. 2016;6:246-8.
9. Otto B, Barbieri C, Lee R, Te AE, Kaplan SA, Robinson B, et al. Incidental prostate cancer in transurethral resection of prostate specimens in the modern era. *Adv Urol*. 2014:1-4.
10. Joshee A, Sharma KCL. The histomorphological study of prostate lesions. *IOSR-JDMS*. 2015;14:85-9.
11. Burdak P, Joshi N, Nag BP, Jaiswal RM. Prostate biopsies: a five year study at a tertiary care centre. *IJSR*. 2015;4:420-3.
12. Thapa N, Shris S, Pokharel N, Tambay YG, Kher YR, Acharya S. Incidence of carcinoma prostate in transurethral resection specimen in a teaching hospital of Nepal. *J Lumbini Med Coll*. 2016;4:77-9.
13. Begum Z, Attar AH, Tengli MB, Ahmed MM. Study of various histopathological patterns in Turp specimens and incidental detection of carcinoma prostate. *IJPO*. 2015;2:303-8.
14. Josephine A. Clinicopathological study of prostatic biopsies. *JCDR*. 2014;8:4-6.
15. Kasliwal N. Pattern of prostatic disease- a histopathological study with clinical correlation. *EJPMR*. 2016;3:589-97.

16. Arya RC, Minj MK, Tiwari AK, Bhardwaj A, Singh D, Deshkar AM. Pattern of prostatic lesions in Chhattisgarh Institute of Medical Sciences, Bilaspur: a retrospective tertiary hospital based study. *Int J Sci Stud.* 2015;3:179-82.
17. Kumar M, Khatri SL, Saxena V, Vijay S. Clinicopathological study of prostate lesions. *IJBAMR.* 2016;6:695-704.
18. Khatib W, Jagtap S, Demde R, Shukla DB, Bisht T. Clinicopathological study of prostate lesions- a one year study. *Int J Med Res Health Sci.* 2016;5:183-6.
19. Deshmukh BD, Ramteerthakar NA, Sulhyan KR. Histopathological study of lesions of prostate-a five year study. *Int J Health Sci Res.* 2014;4:1-9.
20. Mittal BV, Amin MB, Kinare SG. Spectrum of histological lesions in 185 consecutive prostatic specimens. *J Postgrad Med.* 1989;35:157.
21. Puttaswamy K, Parthiban R, Shariff S. Histopathological study of prostatic biopsies in men with prostatism. *J Med Sci Health.* 2016;2:11-7.
22. Mathi A, Krishna R, Devi SI. Histological spectrum of non-malignant lesions of prostate. *IJSR.* 2015;4:192-6.
23. Hameed O, Humphrey PA. Pseudoneoplastic mimics of prostate and bladder carcinomas. *Arch Pathol Lab Med.* 2010;134:427-43.
24. Epstein JI, Netto GJ. Prostate and seminal vesicles. In: Mills SE., editor. *Sternberg's Diagnostic Surgical Pathology.* 6th ed. Philadelphia: Wolters Kluwer; 2015:2097-2142.
25. Garg M, Kaur G, Malhotra V, Garg R. Histopathological spectrum of 364 prostatic specimens including immunohistochemistry with special reference to grey zone lesions. *Prostate Int.* 2013;1:146-51.
26. Gaudin PB, Sesterhenn IA, Wojno KJ, Mostofi FK, Epstein JI. Incidence and clinical significance of high-grade prostatic intraepithelial neoplasia in TURP specimens. *Urol.* 1997;49:558-63.
27. Perera M, Nathan L, Perera N, Bolton D, Clouston D. Incidental prostate cancer in transurethral resection of prostate specimens in men aged up to 65 years. *Prostate Int.* 2016;4:11-4.

Cite this article as: Sharma A, Sharma M, Gandhi S, Khajuria A, Goswami KC. Histomorphological spectrum of prostatic lesions: a retrospective analysis of transurethral resection of prostate specimens. *Int J Res Med Sci* 2017;5:2373-8.