

Case Report

Communication between musculocutaneous and median nerves: a case report

Prakash Billakanti Babu*, Anjali P. Roy, Hemalatha Bangera

Department of Anatomy, Kasturba Medical College, Manipal University, Manipal-576104, Karnataka, India

Received: 28 May 2014

Accepted: 10 June 2014

*Correspondence:

Dr. Prakash Billakanti Babu,

E-mail: billakantibabu@yahoo.co.in

© 2014 Babu PB et al. This is an open-access article distributed under the terms of the Creative Commons Attribution Non-Commercial License, which permits unrestricted non-commercial use, distribution, and reproduction in any medium, provided the original work is properly cited.

ABSTRACT

Musculocutaneous nerve is a branch of lateral cord of brachial plexus. It innervates muscles of flexor compartment of arm and continuous as the lateral cutaneous nerve of forearm without any communication with median or any other nerves.¹ The present report describes a case of variation in musculocutaneous nerve observed in adult male cadaver during routine dissection on the right side. The musculocutaneous nerve did not pierce coracobrachialis muscle and gave a communicating branch to median nerve in the middle of the arm. It is important to be aware of this variation while planning a surgery in the region of axilla or arm, as these nerves are more liable to be injured during operations.

Keywords: Communication, Musculocutaneous nerve, Median nerve

INTRODUCTION

Variations in the formation, branching and communication between the branches of the brachial plexus is a common phenomenon and it has several clinical and surgical implications.²⁻⁶ The musculocutaneous, median and ulnar nerves after arising from the brachial plexus, pass through the flexor compartment of arm without receiving any communicating branch from neighbouring nerves.⁷ Although communications between the nerves in the arm are rare, the communication between the Median Nerve (MN) and Musculocutaneous Nerve (MCN) have been documented earlier. When the lateral root of the median nerve carries the fibers of the MCN it leaves as a communicating branch from the median nerve and joins the MN in the lower third of arm.⁶ Normally MCN passes through the Coracobrachialis Muscle (CBM) and innervates it as well as the brachialis and the biceps brachii muscles and later continues as the lateral cutaneous nerve of the forearm without exhibiting any

communication with the MN or other nerves.^{8,9} MCN may run behind the CBM or adhere for some distance to the MN and pass behind the biceps brachii muscle. The aim of this paper is to report a rare finding where MCN did not pierce CBM and gave communicating branch to MN in the middle of the arm on the right side. This would enable the surgeons to have better knowledge of the field during surgery to avoid neurological damages.

CASE REPORT

During routine dissection of right upper limb in an adult male cadaver, it was observed that MCN was originating normally from lateral cord of brachial plexus but did not pierce the coracobrachialis muscle and was medial to it. MCN gave a branch to coracobrachialis, biceps brachii. Before giving a muscular branch to brachialis MCN gave a communicating branch to MN in the middle of the arm (Figure 1). The communicating branch had an oblique course between the two nerves. Further course and branches of two nerves in arm, forearm and hand was

normal. The course and branches of two nerves were normal on left side.

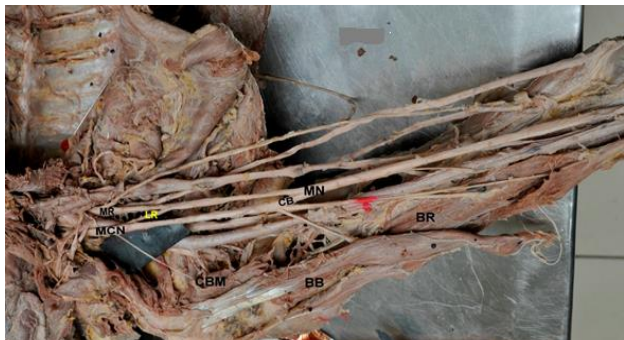


Figure 1: Photograph showing musculocutaneous nerve not piercing coracobrachialis muscle and giving communicating branch to median nerve. MN: Median nerve; MR: Medial root of median nerve; LR: Lateral root of median nerve; MCN: Musculocutaneous nerve; CB: Coracobrachialis; BB: Biceps brachii; BR: Brachialis.

DISCUSSION

In the earlier studies done on communications between MCN and MN, a maximum of two communications have been reported.^{4,10} In the present case only one communication is seen, which is a rare case finding. Le Minor² has classified the variations of MCN and MN into five types. In type I, there are no communication between the MCN and MN. In type II, the fibers of medial root of MN pass through MCN and join the median nerve in the middle of the arm. In type III, the lateral root of the MN from the lateral cord runs in the MCN and leaves it after a distance to join the main trunk of MN. In type IV, the fibers of the MCN unite with the lateral root of the MN. After some distance, the MCN arises from the MN. In type V, the MCN is absent. The fibers of the MCN run within the MN along its course. In this type the MCN does not pierce the CBM. Veinerratos and Anagnostopolou³ studied 79 cadavers and found communications between MCN and MN in 22 cadavers.³ They reported the following three types of communications between MCN and MN, in relation to CBM. In type I: the communication was proximal to the entrance of the MCN into the CBM (9/22); in type II: the communication was distal to the CBM (10/22) and in type III: the nerve as well as the communicating branch did not pierce the muscle (3/22). In a recent study by Choi et al., communications between MCN and MN have been broadly classified into three types.⁴ In type I: the MCN and MN were fused; in type II: there was one connecting branch between the MCN and MN and in type III: two connecting branches were present between MCN and MN. So, the present case coincides with type II category of Choi D classification. Studies by Nakatani et al., revealed three variations in which the musculocutaneous nerve did not pierce the coracobrachialis.¹⁰ Tsikaras et al. revealed that MCN

arise from the MN unilaterally in a male cadaver.¹¹ Chaitra R¹² also reported one case on right side; MCN descended without piercing the coracobrachialis muscle and supplied muscles of the flexor compartment of arm.

In the context that ontogeny recapitulates phylogeny; it is possible that the variation seen in the present study is the result of developmental anomaly. In human being forelimb muscles develops from mesenchyme of paraxial mesoderm in the fifth week of intrauterine life.¹³ Regional expression of five Hox D (Hox D 1 to Hox D 5) genes is responsible for upper limb development.¹⁴ The motor axons arrive at the base of limb bud; they mix to form brachial plexus in upper limb. The growth cones of axons continue in the limb bud.¹³ As the guidance of the developing axons is regulated by the expression of chemo-attractants and chemo-repulsants in a highly coordinated site specific fashion any alterations in signaling between mesenchymal cells and neuronal growth cones can lead to significant variations.¹⁵ Studies of comparative anatomy have observed the existence of such connections in monkeys and in some apes; the connections may represent the primitive nerve supply of the anterior arm muscles.⁵

These variations also have clinical importance especially in post-traumatic evaluations and exploratory innervations of the arm for peripheral nerve repair. The knowledge of the variations of this communication between the MCN and MN in the middle of the arm is important in the anterior approach for the fracture of the humerus. Clinical implication of this could be that injury of MCN proximal to the anastomotic branch between musculocutaneous and median nerve may lead to unexpected presentation of weakness of flexors of forearm and thenar muscles.¹⁶

Significant variations in nerve patterns may also occur circulatory factors at the time of fusion of brachial plexus cords.¹⁵ The presence of such nerve communications are not just confined to man, studies on comparative anatomy have reported the existence of such connections in monkeys and in some apes. Thus suggesting that communications may represent the primitive nerve supply of anterior arm muscles.⁵

CONCLUSION

Communication branches between musculocutaneous nerve and median nerve or between median nerve and ulnar nerve have been reported.¹⁷ In diagnostic clinical neurophysiology, variations in connections between musculocutaneous nerve and median nerve may have significance. These variations have clinical importance in post-traumatic evaluations and exploratory interventions of the arm for peripheral repair. The knowledge of the possible communications is also important in the anterior approach for the fracture of the humerus and regional nerve blocks. It is important to be aware of this variation while planning the surgery in the region of the arm, as

these nerves are more liable to be injured during the operation. Any compression on the communicating branch may give rise to varying pattern of weakness that may impede difficulty in diagnosis for neurologists.

Funding: No funding sources

Conflict of interest: None declared

Ethical approval: Not required

REFERENCES

1. Standring S. Musculocutaneous nerve. In: Standring S, eds. Gray's Anatomy. 40th ed. Spain: Elsevier Ltd; 2008: 821-829.
2. Le Minor JM. A rare variation of the median and musculocutaneous nerves in man. Arch Anat Histol Embryol. 1990;73:33-42.
3. Venieratos D, Anagnostopoulou S. Classification of communications between the musculocutaneous and median nerves. Clin Anat. 1998;11:327-31.
4. Choi D, Rodriguez-Niedenfuhr M, Vazquez T, Parkin I, Sanudo JR. Patterns of connections between the musculocutaneous and median nerves in the axilla and arm. Clin Anat. 2002;15:11-7.
5. Miller RA. Comparative studies upon the morphology and distribution of the brachial plexus. Am J Anat. 1934;54:143-75.
6. Bergmann RA, Thomson SA, Saadeh FA. Spinal nerves and ganglia. In: Bergmann RA, Thomson SA, Saadeh FA, eds. Compendium of Human Anatomic Variation. Munich: Urban & Schwarzeberg; 1988: 139-143.
7. Hollinshead WH. Flexor forearm. In: David B. Jenkins, eds. Functional Anatomy of the Limbs and Back. 4th ed. Philadelphia: W. B. Saunders; 1976: 134-140.
8. Testut. Nerves and muscles. In: Testut, eds. Trait: d' Anatomie. 4th ed. Kolkata, India: Saraswati Press; 1899: 176.
9. Williams PL. Nerves with muscles. In: Williams PL, eds. Gray's Anatomy (The Anatomical Basis of Medicine and Surgery). 38th ed. Edinburgh: Churchill Livingstone; 1995: 843-849.
10. Nakatani T, Mizukami S, Tanaka S. Three cases of musculocutaneous nerve not perforating the coracobrachialis muscle. Kaibogaku Zasshi. 1997;72:191-4.
11. Tsikaras PD, Agiabasis AS, Hytiroglou PM. A variation in the formation of brachial plexus characterized by the absence of C8 and T1 fibers in the trunk of the median nerve. Bull Assoc Anat (Nancy). 1983;67:501-5.
12. Chaitra R. Multiple bilateral neuroanatomical variations of the nerves of the arm. Neuroanat. 2007;8:43-5.
13. Moore KL, Persaud TVN. The muscular system. In: Moore KL, Persaud TVN, eds. The Development Human Clinically Oriented Embryology. 7th ed. Philadelphia: Elsevier Sciences; 2003: 410-424.
14. Morgan BA, Tabin C. Hox genes and growth: early and late roles in limb bud morphogenesis. Dev Suppl. 1994:181-6.
15. Sannes HD, Reh TA, Harris WA. Axon growth and guidance. In: Sannes HD, Reh TA, Harris WA, eds. Development of the Nervous System. 1st ed. New York: Academic Press; 2000: 189-197.
16. Sunderland S. The median nerve: anatomical and physiological features. In: Sunderland S, eds. Nerves and Nerve Injury. 2nd ed. Edinburgh: Churchill Livingstone; 1978: 672-677, 691-727.
17. Kosugi K, S. Shibata, H. Yamashita. Supernumerary head of Biceps brachii and branching pattern of the musculocutaneous nerve in Japanese. Surge Radiol Anat. 1992;14:175-85.

DOI: 10.5455/2320-6012.ijrms20140861

Cite this article as: Babu PB, Roy AP, Bangera H. Communication between musculocutaneous and median nerves: a case report. Int J Res Med Sci 2014;2:1211-3.