

DOI: <https://dx.doi.org/10.18203/2320-1770.ijrcog20212982>

Case Series

## Clinicopathological profile of patients with brain secondaries from Ca cervix: a case series of five patients from tertiary cancer centre in North India

Jyoti Sharma\*, Mrinalini Upadhyay, Manish Gupta, Vikas Fotedar

Department of Radiation Therapy and Oncology, IGMC, Shimla, Himachal Pradesh, India

**Received:** 02 June 2021

**Accepted:** 02 July 2021

**\*Correspondence:**

Dr. Jyoti Sharma,

E-mail: [jyotisharma217@gmail.com](mailto:jyotisharma217@gmail.com)

**Copyright:** © the author(s), publisher and licensee Medip Academy. This is an open-access article distributed under the terms of the Creative Commons Attribution Non-Commercial License, which permits unrestricted non-commercial use, distribution, and reproduction in any medium, provided the original work is properly cited.

### ABSTRACT

Ca cervix is a common gynaecological cancer in daily practice but secondaries in brain after ca cervix as primary is a rare occurrence. As the survival of ca cervix patients has improved, we are able to encounter secondaries in unusual sites like brain. Prognosis is usually dismal due to presence of extra cranial mets along with brain secondaries which limits the use of new radiotherapy techniques like Stereotactic radiosurgery. We present a case series of five patients who presented to us post radical treatment of cancer cervix and treated with whole brain radiation therapy and best supportive care.

**Keywords:** Metastatic Ca cervix, Whole brain radiotherapy, Concurrent-chemo-radiation, Brain metastasis, Unusual site, Metastasis

### INTRODUCTION

Brain metastasis is very debilitating complication of cancer with very less survival rate. Lung cancer, breast cancer, colon cancers contributes to majority of the intracranial mets. Ca cervix is a rare contributor to brain secondaries with less reports available in literature and incidence of 0.5% to 1.2% in various clinical studies.<sup>1</sup>

The incidence of cervical cancer metastasis to the brain has been reported as ranging from 0.4% to 2.3% by Fetcko et al. However due to improved radiation therapy techniques and recent advances we have encountered increased survival in cervical cancer patients, and we are able to encounter metastasis to unusual locations like brain.

Henriksen et al in their study of 420 necropsies of carcinoma cervix revealed that the lymphatic spread, from ca cervix follows a constant course i.e. the parametrium, the nodes of the primary group, and finally the secondary group nodes, before extension beyond the pelvis.<sup>2</sup> They reported the existence of brain mets for the first time in ca

cervix. In gynaecological cancers choriocarcinoma most frequently metastasizes to the brain.

In India according to population-based cancer registry ca cervix is third most common cancer in females and the projected incidence of patients with cancer in India among females is 712,758 (103.6 per 100,000) for the year 2020. The projected 5 most common cancers in 2020 for females (breast, cervix uteri, ovary, corpus uteri, and lung) constitute 53% of all cancers.

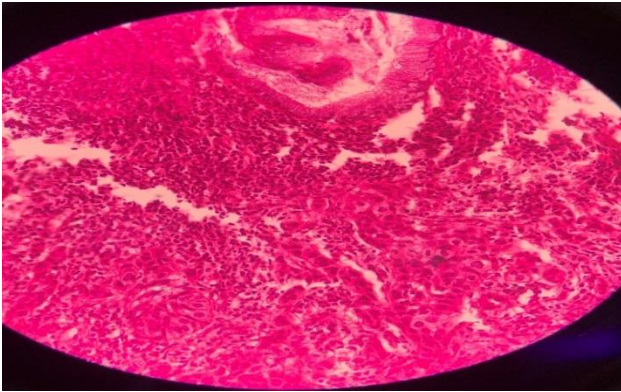
Presently, breast cancer and cervix uteri are the leading sites of cancer among women in India. Ca breast has increasing incidence in metropolitan cities while ca cervix is showing a decline.

### CASE SERIES

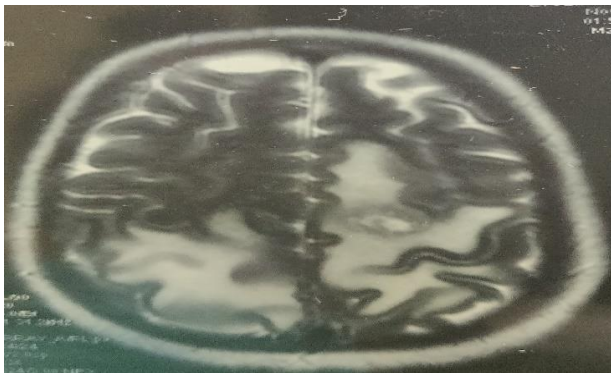#### Case 1

50-year-old female presented history of foul-smelling discharge per vaginum and low backache for last 2 months.

She was post-menopausal for 2 years, non-smoker and had no comorbidities. Her general physical examination and systemic examination were within normal limits. She reported in the department post op after undergoing type II modified radical hysterectomy for poorly differentiated squamous cell carcinoma (Figure 1) Ca cervix FIGO IB2. Contrast enhanced computed tomography (CECT) abdomen pelvis was s/o T2 hyperintense bulky cervix without parametrial extension.



**Figure 1: Poorly differentiated squamous cell carcinoma from cervical biopsy in patient of Ca cervix IB2 in 50-year-old female patient.**



**Figure 2: MRI brain of 50-year-old patient of ca cervix suggested of multifocal thick walled well defined T2/FLAIR hyperintense lesion largest 20×17 mm and 16×14 mm in right parietal and left frontal lobe. Patient was on follow up post treatment of ca cervix and presented 2.5 years later with c/o right sided upper and lower limb weakness.**

Chest-X-ray and routine blood investigations were within normal limits. Detailed histopathological examination (HPE) revealed bulky tumor (4.8×4 cm) deep stromal invasion and patient was given chemoradiotherapy (CRT) 50 Gy/25#/5 weeks along with weekly cisplatin followed by two sessions of intra vaginal brachytherapy 7 Gy mucosal dose at 0.5 cm in two sessions one week apart and was kept on F/u. She was asymptomatic on follow up for 2.5 years and then presented with c/o right sided upper and lower limb weakness, gradually progressive. Magnetic resonance imaging (MRI) brain was suggested of

multifocal thick walled well defined T2/FLAIR hyperintense lesion largest 20×17 mm and 16×14 mm in right parietal and left frontal lobe. It showed peripheral diffusion restriction appearing hyperintense on diffusion-weighted imaging (DWI) with corresponding signal drop appearing hypointense on apparent diffusion coefficient (ADC) sequence with moderate perilesional edema (Figure 2).

Patient was managed with corticosteroids and whole brain radiation therapy. At present patient is on oral procarbazine based chemotherapy and has good performance status, tolerating the treatment well with occasional headache.

### Case 2

A 36-year-old female patient presented with c/o bleeding per vaginum for last 2 months. There was h/o foul smelling discharge. She was non-smoker and did not consume alcohol. She was known case of rheumatic heart disease (RHD). Her general physical examination and systemic examination were within normal limits. P/S/V findings suggested hypertrophied cervix protruding into vagina. Per rectal examination revealed hard mass in midline measuring 3×3 cm. B/L parametrium were free. MRI-pelvis revealed enhancing mass in the cervix with parametrial fat stranding and with sub-centimetric pelvic lymphadenopathy. Biopsy revealed small cell undifferentiated carcinoma and immunohistochemistry (IHC) revealed immunoreactivity to chromogranin A and synaptophysin in neoplastic cells. Final diagnosis was poorly differentiated squamous cell carcinoma with neuroendocrine differentiation. She was staged as Ca cervix FIGO IB2. Patient was planned on CRT 50 Gy/25#/5 weeks along with cisplatin and etoposide D<sub>1 to 3</sub> in first and last week followed by intra cavitary brachytherapy 9 Gy two sessions one week apart and was put on F/U. On her first F/u on P/S/V examination there was residual disease.

Patient sought consultation for salvage surgery in department of gynaecology and underwent salvage type II modified radical hysterectomy with pelvic lymphadenectomy.

Detailed HPE revealed microscopic foci of residual tumor in cervix. On P/S/V examination there were no abnormal findings, hence patient was put on F/u. During F/u post one year she reported early with c/o low backache. P/S/V revealed irregularity in vault and stony hard B/L parametrium. Routine investigations revealed raised total leucocyte count (TLC), deranged kidney function tests (KFTs) and urine proteins++. CECT abdomen and pelvis revealed residual disease on vault and retroperitoneal lymph node mass compressing left ureter resulting in left sided hydronephrosis and liver mets. The recurrence was not pathologically confirmed in cervix. When patient reported on F/U after one year she had e/o metastasis in liver (multiple peripherally enhancing

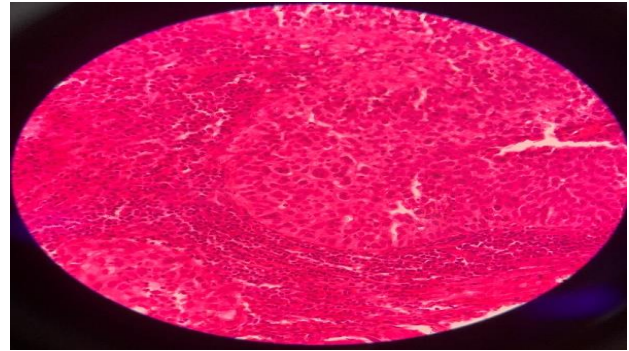
hypodense lesions of variable sizes largest 2.4×2.4 cm in segment VI) and lung had multiple soft tissue nodules.

However, she also developed left sided post auricular swelling from which fine needle aspiration cytology (FNAC) revealed metastatic carcinomatous deposits.

CECT brain was within normal limits. Patient received palliative chemotherapy. She received multiple lines of chemotherapy and despite that the disease progressed and she reported with c/o headache and vomiting. CECT brain revealed brain mets and multiple vertebral and calvarial lytic lesions. She was given WBRT 30 Gy/10 #/2 weeks but 2 months after treatment she reported with poor general condition. Prognosis was explained and she was sent home for best supportive care. Brain metastasis developed one and half year after initial treatment completion for Ca cervix.

### Case 3

42-year-old female patient presented with chief complaint of bleeding P/V for past three months. There was h/o foul smelling discharge p/v. She was P<sub>3+0</sub> and h/o irregular menstruation. She was non-smoker and did not consume alcohol. In general physical examination pallor was present and rest within normal limits. Her systemic examination was within normal limits. P/S/V examination revealed hard ulcero-proliferative growth of size 4×3 cm protruding into the vagina with obliteration of left fornices. P/R examination revealed hard midline mass 3×3 cm. Right para 2/3<sup>rd</sup> involved. Left para involved up to lateral pelvic wall. Biopsy from cervical mass was s/o moderately differentiated squamous cell carcinoma (Figure 3). Her routine investigations revealed haemoglobin (Hb)-6.4gm% and reactivity for hepatitis C virus with rest within the normal limits. She was staged as Ca cervix FIGO IIIB. CECT abdomen and pelvis revealed bulky cervix with e/o heterogeneously enhancing mass lesion present with central hypodense component with extension into lower uterine segment and inferiorly into vagina. Anteriorly and posteriorly fat planes were indistinct with urinary bladder and rectum at places. Patient was planned on CRT 50 Gy/25#/5 weeks and two sessions of intracavitary brachytherapy 9 Gy each two weeks apart and was put on F/u. After one year she reported with c/o weakness B/L lower limbs, headache, cough, fever and expectoration and painful mass nape of the neck. Metastatic workup revealed multiple pulmonary metastasis on CECT thorax and MRI brain revealed ring enhancing lesions in right occipital lobe and B/L cerebellar hemisphere with haemorrhagic metastasis. Metastatic soft tissue deposits in nape of the neck. She was given palliative WBRT 30 Gy/10 #/2 weeks and SFRT to neck mass by direct posterior field. She reported with poor general condition and could not survive. After diagnosis of brain mets survival was 1 month. Overall survival from diagnosis of ca cervix was approximately one and half year.



**Figure 3: Moderately differentiated squamous cell carcinoma in 42-year-old patient of Ca cervix.**

### Case 4

39-year-old female patient presented with chief c/o foul smelling discharge P/V. She was P<sub>3+0</sub>, regular menstrual cycle with no comorbidities. She was non-smoker and not consume alcohol. Her general physical examination and systemic examination were within normal limits. P/S/V examination revealed cervix replaced by ulceroproliferative growth with involvement of upper 1/3<sup>rd</sup> of vagina. Growth bled on touch. P/R revealed midline mass 4×5 cm. Left para up to lateral pelvic wall and right para medial 1/3<sup>rd</sup> involved. Biopsy revealed non keratinizing squamous cell carcinoma and staged Ca cervix IIIB. She was planned on CRT 50 Gy/25#/5 weeks with intracavitary brachytherapy 7 Gy three sessions one week apart and was put on two monthly F/U. During 3<sup>rd</sup> f/u there was presence of induration over cervix and biopsy revealed squamous cell carcinoma. CECT abdomen revealed bulky cervix 5×2.2 cm with left parametrial mass 2×2.5 cm along with para-aortic lymphadenopathy. Patient was planned on chemotherapy based on TPF four cycles. CECT abdomen and Thorax for response assessment revealed disease progression in form of lung metastasis and supra clavicular lymphadenopathy. Due to COVID-19 there were logistic issues and she defaulted for three months and then presented with c/o seizures. MRI brain revealed cystic metastasis in right frontal lobe. WBRT was planned for palliation 30 Gy/10#/2 weeks followed by adjuvant chemotherapy. Due to further deterioration prognosis was explained and advised best supportive care at home.

### Case 5

65-year-old female came with the chief complaint of pain abdomen and bleeding P/V. She was post-menopausal, non-smoker, did not consume alcohol. Her general physical examination and systemic examination were within normal limits. She had h/o DVT and on treatment. P/S/V examination revealed growth on cervix 4×4 cm and involvement of upper 1/3<sup>rd</sup> of vagina. P/R examination revealed a midline mass 3×3 cm and involvement of right para less than 1/3<sup>rd</sup>, left para free. Biopsy from cervix was s/o moderately differentiated squamous cell carcinoma. She was staged FIGO ca cervix IIB. Her routine



investigations were within normal limits. CECT abdomen and pelvis s/o heterogeneously enhancing mass lesion in cervical region and lower uterine segment and involving upper half of the vagina and subcentrimetric paraaortic lymphadenopathy. CRT was planned 50 Gy/25#/5 weeks with cisplatin weekly followed by 4 sessions of Intracavitary brachytherapy 5 Gy each. Patient was on F/u for five months. She reported early with c/o headache and dizziness. MRI brain revealed multiple ill-defined peripherally enhancing altered signal intensity lesions in B/L cerebellar hemisphere with perilesional Edema s/o brain metastasis. She was given WBRT 30 Gy/10#/2 weeks. After treatment she defaulted.

## DISCUSSION

Brain metastasis is a common complication of systemic cancer. Treatment modalities are aimed mainly at palliation of the symptoms in multiple brain lesions. WBRT is the standard of care in more than 5 brain lesions. Stereotactic radiosurgery (SRS) has proved to be an effective modality in gynaecologic malignancies as quoted by Matsunaga et al who reported a control rate of 96.4% and response rate of 93%, 6 months after SRS treatment.<sup>3</sup> Whether to use SRS instead of the conventional surgical excision along with adjuvant WBRT for the treatment of intracranial cervical cancer metastases should be determined on an individual basis with consideration of tumor size (<3 cm), number, and location, along with clinical status and available technology.

In these patients two patients had early stage but adverse pathology like poorly differentiated and rare and aggressive small cell undifferentiated tumor. Other two had higher stage and common histology like moderately differentiated squamous cell carcinoma and non-keratinizing squamous cell carcinoma. One patient early stage but subcentrimetric paraaortic lymphadenopathy along with co morbidities like DVT. Unfortunately, all of these patients developed brain metastasis leading to dismal prognosis. Bi and Li et al have also reported case report of two patients, one of which had poorly differentiated stage IIB cervical cancer with neuroendocrine differentiation and another one with poorly differentiated carcinoma.<sup>4</sup> Both the patients died after 9 and 14 months respectively despite multimodality treatment like surgery, chemotherapy and stereotactic radiosurgery.

Fetcko et al treated a patient of ca cervix with brain mets using surgery and subsequent stereotactic radiosurgery (SRS) to the resection cavity. Patient had a second solitary right lesion for which she again underwent surgery and SRS to the resection cavity with no signs of recurrence 6 months later.<sup>5</sup>

Brown et al reported rapid manifestation of CNS metastatic disease with symptoms like in a cervical

carcinoma patient like dysmetria and homonymous hemianopsia just two weeks after radical surgery for ca cervix 1B2.<sup>6</sup>

## CONCLUSION

Survival in ca cervix patients has shown increase by virtue of improved treatment modalities. This has shown rise in unusual sites of metastasis like brain. This warrants extra efforts in future to analyse the natural history of this disease through large prospective randomized trials so that more effective treatment plans can be made for successful salvage in at least favourable set of patients. Unfortunately, in resource limited centres like ours WBRT is the only treatment available limiting the chance to provide a best available treatment in form of surgical resection/SRS (especially in solitary lesions) to our patients.

## ACKNOWLEDGMENTS

Authors would like to thank to the department of pathology for providing photomicrographs on request.

*Funding: No funding sources*

*Conflict of interest: None declared*

*Ethical approval: Not required*

## REFERENCES

1. Cormio G, Pellegrino A, Landoni F, Regallo M, Zanetta G, Colombo A. Brain metastases from cervical carcinoma. *Tumori*. 1996;82:394-6.
2. Henriksen E. The lymphatic spread of carcinoma of the cervix and of the body of the uterus. *Am J Obstet Gynecol*. 1949;58:924-42.
3. Matsunaga S, Shuto T, Sato M. Gamma knife surgery for metastatic brain tumors from gynecologic cancer. *World Neurosurg*. 2016;89:455-63.
4. Bi Y, Li L. Pathologically confirmed brain metastases from primary uterine cervical tumors: two cases and a literature review. *World J Surg Oncol*. 2019;17(1):174.
5. Fetcko K, Gondim DD, Bonnin JM, Dey M. Cervical cancer metastasis to the brain: A case report and review of literature. *Surg Neurol Int*. 2017;8:181.
6. Brown JV, Epstein HD, Kim R, Micha JP, Rettenmaier MA, Mattison JA, Goldstein BH. Rapid manifestation of CNS metastatic disease in a cervical carcinoma patient: a case report. *Oncology*. 2007;73(3-4):273-6.

**Cite this article as:** Sharma J, Upadhyay M, Gupta M, Fotedar V. Clinicopathological profile of patients with brain secondaries from Ca cervix: a case series of five patients from tertiary cancer centre in North India. *Int J Reprod Contracept Obstet Gynecol* 2021;10:3208-11.