

Case Report

Cerebral infarction: an unusual manifestation of viper snake bite

Jyotirmoy Pal, Sumantra Mondal*, Debanjali Sinha, Tony Ete,
Atanu Chakraborty, Arijit Nag, Gouranga Sarkar, Bikram Saha

Department of Medicine, Institute of Post Graduate Medical Education and Research, Kolkata, West Bengal, India

Received: 7 May 2014

Accepted: 23 May 2014

***Correspondence:**

Dr. Sumantra Mondal,

E-mail: drmsumantra@gmail.com

© 2014 Pal J et al. This is an open-access article distributed under the terms of the Creative Commons Attribution Non-Commercial License, which permits unrestricted non-commercial use, distribution, and reproduction in any medium, provided the original work is properly cited.

ABSTRACT

Snake envenomation causes significant mortality and morbidity. Viper bite usually present with local cellulites, renal failure and bleeding disorders. Thrombotic manifestation of snake bite is rarely reported and early administration of Anti-Snake Venom Serum (ASV) also reduces the risk of thrombotic complications. Cerebral infarction in case of viper bite may be due to hypotension, hypercoagulability or direct action of venom on vessel wall. We report a rare case of viper bite, presented with renal failure and cerebral infarction in spite of early ASV institution. The thrombotic manifestation in this case was possibly due to disseminated intravascular coagulation.

Keywords: Viper bite, DIC, Cerebral infarction

INTRODUCTION

Snake envenomation is an important public health hazard throughout the world particularly in third world countries. Viper bite is quite common in South East Asia. Several species of snakes of viperidae family produce venoms that have a wide range of activities affecting hemostasis. Snake envenomation is a complex phenomenon manifest as hematological, renal, cardiac and neurological abnormalities. However ischemic manifestations like, acute myocardial or cerebral infarction is quite uncommon.^{1,2} Such cases are rarely reported in literature.

CASE REPORT

A twenty one year male admitted in our hospital with history of viper snake bite on dorsum of right hand while he was working in the field. He received total twenty vials (10 vials each, at an interval of 6 hours, intravenously) of lyophilized polyvalent anti-snake venom serum, started within three hours of bite in a local

hospital. Later on, he was transferred to IPGME&R as he developed acute renal failure.

On the day of admission, he was drowsy (Glasgow coma scale 11/15); two bite marks were present on the dorsum of right hand with local swelling involving forearm and ecchymoses (Figure 1). Puffiness of face with pedal edema was present. There was no bleeding manifestation, no ptosis, mildly dilated pupils with normal light reaction. Ophthalmoscopy was normal. He passed only 100 ml of urine in last twenty four hours. He was hemodynamically stable with a respiratory rate of 20/min, Mild anemia was present. Apart from drowsiness, neurological examination was unremarkable without any evidence of cranial nerve palsy. Other systems were normal. Investigation revealed, hemoglobin 11 gm%, TLC 10500/cumm, platelet 80000/cumm. Blood urea - 196 mg/dl, serum creatinine - 9.1 mg/dl, random blood sugar - 124 mg/dl. Sodium - 137 mmol/dl, Potassium - 5.4 mmol/dl, hepatic function was normal and whole blood clotting time was fifteen minutes. Patient was put on hemodialysis.

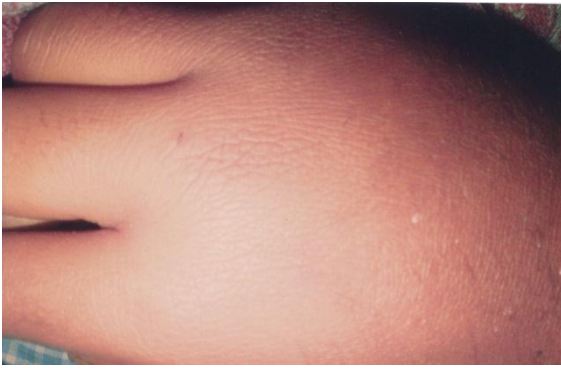

Figure 1: Local swelling and ecchymosis at the site of viper bite.

In the very next day the patient developed left sided hemiparesis with upper motor neuron type of facial palsy. Power in the left upper and lower limbs was 3/5 and 4/5 respectively. CT scan revealed large infarct involving right middle cerebral artery territory (Figure 2). Hematological parameters revealed features of Disseminated Intravascular Coagulation (DIC), Platelet-60000/dl, prothombin time - 30 sec (Normal - 12 seconds), APTT -60 seconds (Normal 25-35 seconds). Fibrin degradation product value was >40 µg/dl (Normal <5µg/ml). Echocardiogram was normal. Patient was shifted to critical care unit, managed conservatively and hemodialysis continued until improvement of renal function. At the time of discharge there was mild residual weakness in his left half of body (power of left upper and lower limb 4/5), normal coagulation profile and negative lupus anticoagulant test. Doppler study of carotid and vertebral system, MR angiogram of extra and intra cranial arterial system (performed after normalization of renal function) turned out to be normal. In the absence of other possible precipitants of DIC, snake bite was considered as the culprit event and thrombotic manifestation of DIC dominated the clinical spectrum.

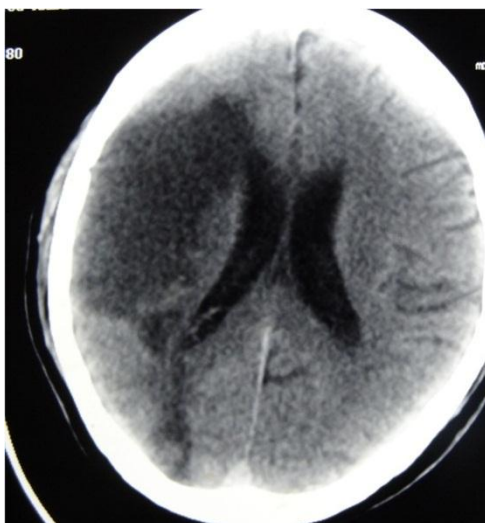


Figure 2: CT scan of brain showing large infarct involving right middle cerebral artery territory.

DISCUSSION

Neurodeficit following viper bite is not uncommon. Usually it manifests as intracerebral or subarachnoid hemorrhage.³

Cerebral infarction is rare and there are only few case reports all over world.

Snake venom is a complex fluid. Main components of snake venom are protease, collagenase and phospholipases, which are responsible for local swelling, tissue destruction, vascular damage, alteration of coagulation profile and neurotoxicity. Most of the viper venom exhibit both anticoagulant and coagulant effects. As a pro coagulant it has thrombin like activity, can activate prothrombin even in the absence of calcium ion, activate factor x and v and endothelial cells.⁴

Features of viper bite depend on severity of envenomation and bleeding manifestations are commonly encountered in the clinical practice. Thrombotic manifestations are uncommon. Large doses of venom can produce massive intravascular clotting with ischemic sequelae of major organs.⁴

In a prospective study in Sri Lanka on 500 victims of *D. russelii* bites, 9 patients (1.8%) have CT evidence of ischemic strokes involving medium to large vessel territories of the brain. According to this study, pro thrombotic property of the viper venom was the putative mechanism.⁵

In another study on 309 snake bite patients, ischemic stroke was present in only one patient.⁶

There are several mechanisms by which cerebral infarction can occur in viper bite. 1) Hypotension, which can cause watershed infraction. Hypotension can be due to excessive sweating, vomiting, and increased vascular permeability due to release of vasogenic agents or adrenal hemorrhage. 2) Endothelial injury by direct action of components of viper venom on vessel wall may produce vasculitis and local thrombosis. 3) Hypercoagulability - it can be due to procoagulants in the venom such as arginine, esterase, hydrolase, hyper viscosity due to hypotension, 4) Vascular - hemorrhaging are complement mediated toxic components of viperidae that causes severe vascular spasms followed by vasodilatation, while at capillaries they causes increased vascular permeability, resulting in hemorrhagic infarct.^{3,7}

Reports of thrombotic phenomenon following viper bite are small in number.

The details of case reports of post viper bite cerebral infarction are given below in a tabular form.

Table 1: The details of case reports of post viper bite cerebral infraction.

Author	Age (Years)	Sex	Year of report	Country of report	ASV given/not	Location of stroke	Explanation
Bashir et al. ⁷	13	Female	1985	Saudi Arabia	Given	Left parietal	Vessel damage by toxin. Low grade, DIC.
Panicker JN et al. ⁸	21	Male	2000	India	Given	Left frontal	Hypotension, endothelial injury, hypercoagulability
Hoskote SS. et al. ⁹	24	Male	2009	India	Given	Bilateral anterior cerebral artery	DIC, hemoconcentration, procoagulant state, hemorrhagins.
Narang SK. et al. ¹⁰	18	Male	2009	India	Given	Left MCA	DIC, hemorrhagin, Toxic vacuities, hyper viscosity.
Gouda S. et al. ¹¹	40	Female	2011	India	Given	Cerebellar hemisphere, occipital lobe	DIC, Multifactorial.
Ittyachen AM. et al. ¹²	55	Male	2012	India	Given	Bilateral thalamic infract.	DIC, Toxic vasculitis, vasospasm, hemoconcentration.
Thaigo cardaso vale et al. ¹³	16	Male	2013	Brazil	Given	Left temporo occipital infarct, ischemia in pons and cerebellum.	Toxic vasculitis, toxin induced vasospasm and endothelial damage.

Previously it has been showed that, in Bothrops lanceolatus snake bite, early institution of AVS decreases the rate of thrombotic manifestations.¹⁴ In our patient early administration of AVS failed to prevent thrombotic sequelae. The cause may be due to variation in snake species or development of DIC.

Our patient never presented with hypotension and there was no imaging feature of water shed infarction. Hematological investigations were suggestive DIC. Overt thromboembolic manifestation can occur in 10-40% cases of DIC. DIC may trigger different hemostatic and cellular pathways for thrombin and plasmin generation, resulting in clinico-pathological process that favours thrombosis or consumption with bleeding.

More common differentials of stroke in a young patient like, cardio embolisation, cerebral arterio venous malformation, carotid artery dissection, anti-phospholipid antibody syndrome were reasonably excluded in our patient and there was no history of any drug abuse.

Most of the cases of viper bite occur in third world countries. It is believed that complications may be more common than is reported in the literature, which may be due to inefficient reporting system and lack of infrastructure. A physician must consider the rare possibility of cerebral infarction in institution viper bite even after neutralization of toxin by early of AVS.

Funding: No funding sources

Conflict of interest: None declared

Ethical approval: Not required

REFERENCES

1. Hsaini Y, Satte A, Balkhi H, Karouache A, Bourezza A. Stroke following a viper bite. Ann Fr Anesth Reanim. 2010 Apr;29(4):315-6.
2. Aravanis C, Ioannidis PJ, Ktenas J. Acute myocardial infarction and cerebrovascular accident in a young girl after a viper bite. Br Heart J. 1982 May;47(5):500-3.
3. Murthy JM, Kishore LT, Naidu KS. Cerebral infarction after envenomation by viper. J Compt Assist Tomogra. 1997 Jan-Feb;21(3):35-7.
4. Chugh KS. Snake bite induced acute renal failure in India. Kidney Int.1989 Mar;35(3):891-907.
5. Gawarammana I, Mendis S, Jeganathan K. Acute ischemic strokes due to bites by Daboia russelii in Sri Lanka: first authenticated case series. Toxicon. 2009;54(4):421-8.
6. Mosquera A, Idrovo LA, Tafur A, Brutto LH. Stroke following Bothrops spp. snake bite. Neurol. 2003 May;60(10):1577-80.
7. Bashir R, Jinkins J. Cerebral infarction in a young female following snake bite. Stroke. 1985 Mar-Apr;16(2):328-30.
8. Panicker JN, Madhusudanan S. Cerebral infarction in a young male following viper envenomation. J Assoc Physicians India. 2000 Jul;48(7):744-5.

9. Hoskote SS, Iyer VR, Kothari VM, Sanghvi DA. Bilateral anterior cerebral artery infarction following viper bite. *J Assoc Physicians India.* 2009 Jan;57:67-9.
10. Narang SK, Paleti S, Azeez Asad MA, Samina T. Acute ischemic infarct in the middle cerebral artery territory following a Russell's viper bite. *Neurol India.* 2009 Jul-Aug;57(4):479-80.
11. Gouda S, Pandit V, Seshadri S, Valsalan R, Vikas M. Posterior circulation ischemic stroke following Russell's viper envenomation. *Ann Indian Acad Neurol.* 2011 Oct;14(4):301-3.
12. Ittyachen AM, Jose MB. Thalamic infarction following a Russell's viper bite. *Southeast Asian J Trop Med Pub Health.* 2012 Sep;43(5):1201-4.
13. Vale TC, Leite AF, da Hora PR, Coury MI, da Silva RC, Teixeira AL. Bilateral posterior circulation stroke secondary to a crotalid envenomation: case report. *Rev Soc Bras Med Trop.* 2013 Mar-Apr;46(2):255-6.
14. Thomas L, Tyburn B, Bucher B, Pecout F, Ketterle J, Rieux D, et al. Prevention of thromboses in human patients with *Bothrops lanceolatus* envenoming in Martinique: failure of anticoagulants and efficacy of a monospecific antivenom. Research group on snake bites in Martinique. *Am J Trop Med Hyg.* 1995 May;52(5):419-26.

DOI: 10.5455/2320-6012.ijrms20140836

Cite this article as: Pal J, Mondal S, Sinha D, Ete T, Chakraborty A, Nag A, Sarkar G, Saha B. Cerebral infarction: an unusual manifestation of viper snake bite. *Int J Res Med Sci* 2014;2:1180-3.