

## Original Research Article

# A study of mediastinal tumours in a tertiary care centre: a retrospective study

Kaladhar Bomma, Amaresh R. Malempati\*

Department of Cardiothoracic Surgery, Nizams Institute of Medical Sciences, Hyderabad, Andhra Pradesh, India

**Received:** 02 February 2021

**Revised:** 17 February 2021

**Accepted:** 18 February 2021

### \*Correspondence:

Dr. Amaresh R. Malempati,

E-mail: amareshrao malempati@gmail.com

**Copyright:** © the author(s), publisher and licensee Medip Academy. This is an open-access article distributed under the terms of the Creative Commons Attribution Non-Commercial License, which permits unrestricted non-commercial use, distribution, and reproduction in any medium, provided the original work is properly cited.

## ABSTRACT

**Background:** Recent advances in diagnostic and surgical techniques have brought major changes in the clinical presentation, diagnosis and the surgical management of mediastinal masses. Indian literature in this scenario is deficient, which our retrospective descriptive study aims to address.

**Methods:** Details of patients operated for mediastinal masses from January 2007 to November 2013 in two units at NIMS were collected. Clinical presentation, symptomatology, radiological/pathological findings, surgical approaches, intraoperative/immediate/intermediate post-operative results were evaluated and analysed.

**Results:** Of the 75 patients, (48 males, range 10 years to 65 years) 2 deaths were due to complications following exacerbation of myasthenia gravis, and two patients died due to post-operative bleeding. Thymic neoplasms were the most common, followed by neurogenic tumours. Most common presentation was myasthenia gravis, followed by nonspecific back pain. 4% of patients had symptoms due to local compressive effects. Tumour was in the anterior mediastinum, middle and posterior mediastinum in 53, 16 and 6 cases respectively. Surgery done with a curative intent was through sternotomy (59), posterolateral thoracotomy (14), and combined sternotomy and cervical route (2). Residual tumour was present in 5 cases due to nerve involvement. Follow up was 98% (2 months to 6 years). 3 patients died of unrelated causes and one developed multiple lung metastases. 2 patients with neurogenic tumours developed recurrence.

**Conclusions:** Inadequately optimized myasthenia patients and superior vena cava obstruction are poor prognostic factors. Complete excision may not be possible in neurogenic extension to spine even with concomitant neurosurgery. Neurological infiltration has a poorer prognosis.

**Keywords:** Mediastinal masses, Thymic neoplasms, Neurogenic tumours, Thoracotomy

## INTRODUCTION

Medical world has evolved rapidly over the past few years. There have been several advances in the diagnostic and surgical procedures over the past few decades.<sup>1</sup>

The incidence of non-symptomatic mediastinal masses may have gone up, as well as greater number of tumours once considered inoperable or offered only palliative resection may now be treated more aggressively

surgically. The improvement in pathological diagnosis and the biological nature of the disease also means more precise prognostic assessment which potentially could offer better neo adjuvant treatment or better surgical planning.<sup>1-4</sup>

Data on mediastinal masses in the Indian scenario is sadly, missing and inadequate. We present our data as a descriptive study with a view to throw light on the spectrum in the Indian scenario.

## METHODS

We analysed retrospectively the data of patients operated for mediastinal masses in two surgical units in Nizams Institute of Medical Sciences, Panjagutta, Hyderabad from January 2007 to November 2013.

We excluded from this study, those patients who were operated for oesophageal masses, pulmonary masses and metastatic masses. The location of the tumour was classified into anterosuperior, middle and posterior mediastinum, based on the radiological and surgical reports. Preoperative work up of the patients included chest radiographs (Figure 2), computerized tomography scan (CT) scans, magnetic resonance imaging scans (MRI scans), and if necessary, PET scans. Wherever there was a diagnostic dilemma preoperatively regarding the nature of the tumour, preoperative fine needle aspiration cytology (FNAC) or Tru Cut biopsy done and the specimen sent for evaluation. All the specimens retrieved after surgeries were sent for histopathological evaluation (Figure 1a and b).

Complete excision was based on operative notes as well as post op radiological imaging reports wherever done. Medical records were reviewed after ethical clearance for clinical presentation, symptomatology, radiological and pathological diagnosis, surgical approaches, and completeness of excision and post-operative recurrence or complications.

### Statically analysis

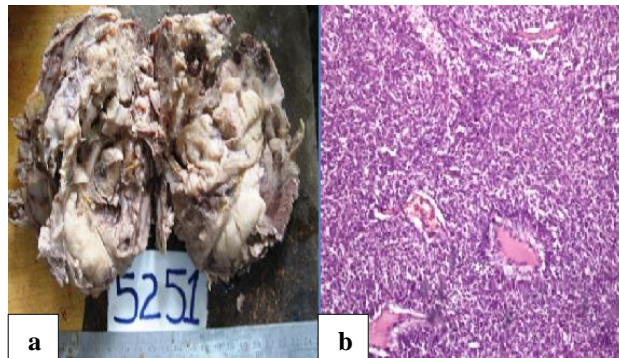
Statistical analysis was performed using the graphpad quick calculation software. Patient demographics were compared with analysis of variance (ANOVA). The study data were analyzed using statistical methods of mean, standard deviation, paired students “*t*” test (for values within the group at different time stations) and independent unpaired “*t*” test (for comparison of intergroup values).

## RESULTS

75 patients were operated, of whom 48 were males (64%), and 27 females (36%). Age of patients ranged from 10 years to 75 years. Mean age was 37 years, and majority of the patients (n=31) were between age group 21 to 40 years, as compared to age groups 10 to 20 years (n=13), 41 to 60 years (n=21) more than 60, (n=10). Anatomical location of the tumours revealed the majority to be in the anterior mediastinum (n=53 or 70.66%), followed by the posterior mediastinum (n=16 or 21.66%) and the middle mediastinum (n=6 or 8%).

Majority of the patients were diagnosed with a mediastinal mass on being evaluated for myasthenia symptoms (n=22 or 29.33%) or for low back ache, cough or atypical chest pain (n=12 or 16%). Other symptoms included dysphagia, paraparesis in 1 patient and an asymptomatic patient on

evaluation for trauma. The symptom list of patients is given in Figure 1.



**Figure 1: (a) Gross specimen of thymoma and (b) histopathological specimen of thymoma.**

The histological subtypes of each tumour is given in Table 2. Thymic masses were most common in the anterior mediastinum, with benign thymoma the commonest. There were 5 malignant thymomas and 3 lymphomas, as well as 4 malignant posterior mediastinal masses. Benign neurogenic masses were however the most common posterior mediastinal masses. Benign cystic masses were the commonest middle mediastinal masses.

Surgery was done with a curative intent in all the patients. Midline sternotomy was done in 59 patients, whereas posterolateral thoracotomy was done in 14 patients and combined approach midline sternotomy and cervical approach in 2 patients. Two patients had tumour infiltration into the major vessels SVC and innominate vein and hence could not be resected completely. Two patients had residual tumour left due to involvement of nerves. Complete excision was possible in all the other patients. Two patients with thymomas died due to exacerbation of myasthenic symptoms and infective complications following prolonged ventilation.

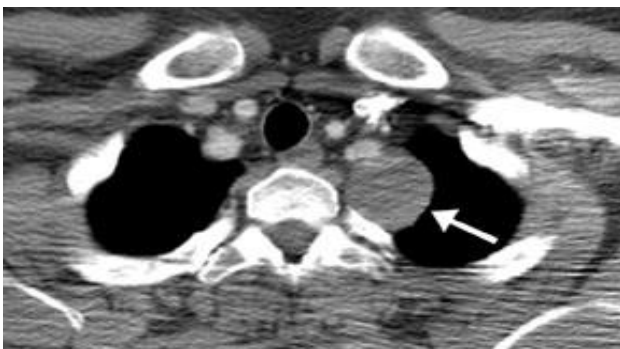
Three patients had prolonged recovery due to increased ventilator support and plasmapheresis due to exacerbation of myasthenic symptoms. One patient with a posterior mediastinal neurogenic mass required re exploration due to increased bleeding following surgery.



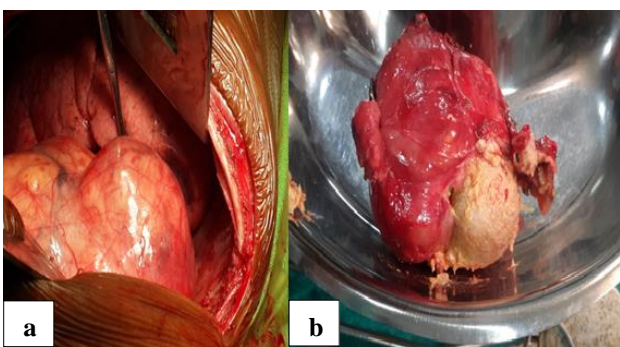
**Figure 2: Chest radiograph of mediastinal mass.**

**Table 1: Histopathology diagnosis and location of the tumour.**

Anterior mediastinum	Number of patients=74	Posterior mediastinum	Number of patients=30	Middle mediastinum	Number of patients=8
<b>Thymic</b>		Benign		Pericardial cysts	03
<b>Benign</b>		Neurofibroma	09	Mature cystic teratoma	01
<b>Thymoma</b>	33	Ganglioneuroma	07	Bronchogenic cyst	04
<b>Thymic cyst</b>	06	Schwanoma	04		
<b>Thymic hyperplasia</b>	06	Leiomyoma	02		
<b>Malignant</b>		Malignant			
<b>Thymic carcinoma</b>	3	Malignant peripheral nerve sheath tumors	06		
<b>Germ cell tumours</b>		Neuroblastoma	02		
<b>Benign</b>					
<b>Teratoma</b>	5				
<b>Seminoma</b>	3				
<b>Malignant</b>					
<b>Teratoma</b>	1				
<b>Embryonal cell carcinoma</b>	2				
<b>Mesenchymal</b>					
<b>Benign</b>	4				
<b>Malignant</b>	4				
<b>Lymphoma</b>	6				
<b>Endocrine carcinoma</b>	1				



**Figure 3: CT scan picture showing posterior mediastinal mass.**



**Figure 4: a) Intra operative picture showing anterior mediastinal done through thoracotomy approach and b) excised specimen of anterior mediastinal germcell tumour.**

Follow up after surgery was for at least three visits for all except 2 patients. Duration of follow up ranged from 2 weeks to 6 years. During the follow up, two patients died due to complications following exacerbation of myasthenia gravis. Three patients died of unrelated causes. one patient developed multiple lung metastases, and two patients, though having vague atypical symptoms, due to a high index of suspicion, on evaluation by CT scan, were found to have recurrence of posterior mediastinal masses.

**DISCUSSION**

We present our series of mediastinal masses in the Indian scenario. In a study conducted by Aroor *et al* mediastinal masses were most commonly found in the anterior mediastinum (42.86%) followed by middle mediastinum (11.43%), posterior mediastinum (8.57%), and multiple compartments (37.14%).<sup>5</sup> The incidence of benign mediastinal tumors has been reported to exceed that of malignant tumors by Adegboye *et al*.<sup>6</sup> However Vaziri *et al* reported 60% incidence of malignant mediastinal tumors in their series, which probably could be attributed to the fact that they included metastatic tumors in their study.<sup>7</sup> In this study, the majority of lesions were found in the anterior mediastinum. Benign tumors exceeded malignant ones in this series. The incidence of lymphomas are also less compared to other series, this may be because of improvements in the pre-operative diagnostic tools and improvements in molecular cytology.<sup>3,8</sup> The patients with lymphomas thus diagnosed early are avoided diagnostic



surgery. Similarly, it might have been expected that being a developing country with a low socio economic status patients being the bulk of the patients, tuberculosis might have been a common finding, however, the pre-operative CT guided aspiration cytology and biopsy has made surgery a remote choice for the diagnosis of unexplained significant lymph node enlargement (Table 1).

The surgery can be planned astutely with very few patients requiring multiple approaches through sternotomy and thoracotomy, however, some patients may require a combined approach to access supra clavicular extensions.<sup>4</sup> Encasement of large veins like the innominate veins and the superior vena cava makes the tumour non amenable for surgical excision and the resection palliative. Similarly, neurogenic involvement of the nerves in posterior mediastinal masses make the tumours non resectable. In our experience, prior excision by neurosurgeon followed by excision by thoracic surgeon, rather than prior excision by thoracic surgeon followed by excision by neurosurgeon results in more complete excision of the tumour, and can thus be the preferred approach.

Recurrence of the tumour may not necessarily be associated with symptoms, and a high incidence of suspicion may pick up recurrences before major structure involvement. Adequate control of symptoms of myasthenia gravis prior to surgery is very important for good surgical result. Early institution of plasmapheresis may result in better outcome in case of myasthenic crisis or exacerbation of the disease.<sup>9,10</sup>

Arvind Kumar et al study showed that presence of myasthenia with thymoma is associated with more adjacent structure resection, higher postoperative complications and more conversions.<sup>11</sup> The use of robotic surgery for thymoma resection in patients with myasthenia could not overcome the early postoperative problems related to myasthenia gravis.

Mediastinal lesions are rare entities and data regarding their clinical and pathological features are limited. Further studies with larger sample size are required to enrich our knowledge regarding the enigmatic mediastinal masses. The limitations of this study include that it is a single centre and single unit retrospective study, with all the limitations that come with such investigations.

## CONCLUSION

We describe our series in the Indian scenario. Inadequately optimized myasthenia patients and superior vena cava obstruction are poor prognostic factors. Complete excision may not be possible in neurogenic extension to spine even with concomitant neurosurgery. Neurological infiltration has a poorer prognosis.

*Funding: No funding sources*

*Conflict of interest: None declared*

*Ethical approval: The study was approved by the Institutional Ethics Committee*

## REFERENCES

1. Karki S, Chalise S. Analysis of mediastinal lesions: A study of 27 cases. J Pathol Nepal. 2011;1:114-7.
2. Dubasi B, Cyriac S, Tenali SG. Clinicopathological analysis and outcome of primary mediastinal malignancies-a report of 91 cases from a single institute. Ann Thorac Med. 2009;4:140-2.
3. Fishman A, Elias J, Fishman J. Fishman's pulmonary diseases and disorders. 4 edition. McGraw Hill Professional. 2008.
4. Ryu, Jay H. Mediastinal and Other Neoplasms. ACCP Pulmonary Medicine Board Review: 26th Edition. 2012.
5. Aroor AR, Prakasha SR, Seshadri S, Teerthanath S, Raghuraj U. A study of clinical characteristics of mediastinal mass. J Clin Diagn Res. 2014;8:77-80.
6. Adegboye VO, Ogunseyinde AO, Obajimi MO, Ogunbiyi O, Brimmo AI, Adebo OA. Presentation of primary mediastinal masses in Ibadan. East Afr Med J. 2003;80:484-7.
7. Vaziri M, Pazooki A, Zahedi-Shoolami L. Mediastinal masses: Review of 105 cases. Acta Med Iran. 2009;47:297-300.
8. Tomiyama N, Honda O, Tsubamoto M, Inoue A, Sumikawa H, Kuriyama K, et al. Anterior mediastinal tumors: Diagnostic accuracy of CT and MRI. Eur J Radiol. 2009;69:280-8.
9. Dasgupta S, Bose D, Bhattacharyya NK, Saha M, Biswas K, Biswas PK. A clinicopathological study of mediastinal masses operated in a tertiary care hospital in Eastern India in 3 years with special reference to thymoma. Indian J Pathol Microbiol. 2016;59(1):20-4.
10. de Perrot M, Liu J, Bril V, McRae K, Bezjak A, Keshavjee SH. Prognostic significance of thymomas in patients with myasthenia gravis. Ann Thorac Surg. 2002;74:1658-62.
11. Kumar A, Asaf BB, Pulle MV, Puri HV, Sethi N, Bishnoi S. Myasthenia is a poor prognosticator for perioperative outcomes after robotic thymectomy for thymoma. Eur J Cardiothorac Surg. 2020;5:406.

**Cite this article as:** Bomma K, Malempati AR. A study of mediastinal tumours in a tertiary care centre - a retrospective study. Int J Res Med Sci 2021;9:862-5.