

## Original Research Article

# A clinical audit of thoracotomy done in a tertiary care center

**Zeeshanuddin Ahmad, Deepak Agrawal\*, Sanjay M. Desai, Amar Jain**

Department of Surgical Oncology, Sri Aurobindo Medical College and Post Graduate Institute, Indore Ujjain Highway, Bhawrasla, Indore, Madhya Pradesh, India-452001

**Received:** 17 March 2018

**Accepted:** 25 April 2018

**\*Correspondence:**

Dr. Deepak Agrawal,

E-mail: [zee\\_kmc03@rediffmail.com](mailto:zee_kmc03@rediffmail.com)

**Copyright:** © the author(s), publisher and licensee Medip Academy. This is an open-access article distributed under the terms of the Creative Commons Attribution Non-Commercial License, which permits unrestricted non-commercial use, distribution, and reproduction in any medium, provided the original work is properly cited.

### ABSTRACT

**Background:** Sri Aurobindo Medical College and Post Graduate Institute is a tertiary care center in Indore. The surgical oncology department is performing various oncological surgeries. One subspeciality is thoracic surgery, where surgeries for benign as well as malignant cases are being done. Thoracotomy is done for various lung, pleural and mediastinal pathology. Open and VATS are two main modalities with each having their pros and cons.

**Methods:** All thoracotomies done from 2016 to January 2018 were included in the study. Decortications, wide local excision, lobectomies, pneumonectomies, hilar lymph node dissections were done.

**Results:** Total 30 cases were done in a span of 2 years. Of these 9 cases were done for a malignant origin, 4 for benign tumor, 3 for benign non-infective disease and rest 14 for infective origin. Posterolateral thoracotomies were done most often. Average duration of the procedure was 157 minutes. Average blood loss was approximately 340 ml. Mean duration of stay was 10.9 days.

**Conclusions:** Thoracic oncologic procedures are less often done due to paucity of the cases. However, surgical oncologist being well versed with the anatomy, relations and oncologic concepts can perform both neoplastic as well as infected cases. With increasing number of cases, the standard of care is increasing, operating time is lessened, complications are brought down, and the results are better.

**Keywords:** Decortication, Lobectomy, Pneumonectomy, Thoracotomy

### INTRODUCTION

The history of surgery is characterized as a reduction of surgical intervention. The current surgical treatment principle aims at curability with maximal functional preservation.

The surgical management of empyema reduces the duration of treatment and increases functional outcome. Pulmonary complications are a major cause of morbidity and mortality in the immediate post-operative period after thoracic surgery.<sup>1</sup> For best outcomes in malignancy, the case selection should be befitting, pre-op preparation be adequate and surgery should be done in accordance to the oncologic principles.

**Objective:** This is a clinical audit of different types of open thoracotomies for oncologic and infective causes in tertiary care center in central India. We performed an institutional review of patients undergoing thoracotomy for various lung/ mediastinal pathology to increase our efficiency and limit the proportion of complications.

### METHODS

Sri Aurobindo Medical College and Post-Graduate Institute is a tertiary care center in the city of Indore, MP, India. Patients come to this hospital from all over the state. This is an observational prospective study. Patient

who were operated with thoracotomy between 2016 to january-2018 were included in the study. The information obtained from the patients included age, sex, habits, morbidity, etiology, imaging studies, signs/symptoms and their duration, procedure performed, length of operation, blood loss, duration of chest tube insertion, post-operative stay in hospital, morbidity, mortality were noted.

Surgical protocol included insertion of a double lumen endotracheal tube. Level of thoracotomy was decided in accordance to the pathology. Most often posterolateral thoracotomy was performed. However, sternotomy and cervical thoracotomy were also done occasionally.

A thoracic epidural catheter was used for continuous intraoperative and postoperative analgesia; after induction of anesthesia, a double-lumen endotracheal tube was inserted for selective lung ventilation. Patients were positioned in lateral decubitus ensuring that the upper arm is rotated slightly cephalad and extended anteriorly. This rotates the scapula forward, providing access to the paraspinal region. The lower leg is flexed and the upper leg is straight, which permits the weight of the upper leg to widen the intercostal spaces if the patient is placed in mild reverse Trendelenberg position. The head is supported so that the cervical spine is in a neutral position. The chest was lifted with a triangular blanket (bolster) rolled under the lower side of the chest. The skin was prepared from the upper sternum to the xiphoid appendix and laterally upto the spine. Access to the fifth intercostal space was prepared by an appropriate incision (10 to 15cm) from below the nipple toward the anterior axillary line. Its posterior extent is just posterior and inferior to the tip of the scapula, and it extends parallel to the underlying intercostal spaces to a point that is just anterior to the anterior border of the latissimus dorsi. Care was taken to ligate or cauterize the neurovascular bundles, which are identified as thick white bundles that lie across the incision in the muscle. The latissimus dorsi and pectoralis major muscles were left intact, whereas the serratus anterior muscle was split anteriorly along the direction of its fibers. The intercostal muscle was separated from the upper border of the fifth rib with the use of the electrocautery. After unilateral lung deflation and pleural incision, splitting of the intercostal muscle was extended anteriorly and posteriorly (up to 10cm). The ribs were spread with a retractor to allow access to all sites of the lung.

Postoperative medical management primarily involved the restricted use of intravenous fluid (1mL/kg/hr), chest tube drainage, physiotherapy, early mobilization and nutrition, and psychological reassurance. Continuous epidural analgesia was used for the first 48 hours. An anti-inflammatory medication was also given in each case (diclofenac 75mg/12hr).

For decortication: All fibropurulent material was removed and formal decortication was done. The

diaphragm was routinely separated from the lung and from adhesions released to promote largest possible pulmonary expansion. Using a combination of blunt and sharp dissection, the rind was separated from the parietal pleura across the entire chest wall to the point where the mediastinum and diaphragm were reached. When the parietal peel had been dissected from the chest wall, the empyema cavity was opened. The fibrinous contents of the empyema cavity were evacuated by suctioning or, more commonly, were removed piecemeal by hand or with ring forceps.

For benign lesions: wide excision was done.

For malignancy: surgery was done according to the oncologic principles.

Intercostal drainage tubes were inserted at the end of surgery routinely. Patients were extubated in operation theater. Patients were managed in intensive care unit only in cases where mechanical ventilation or vasopressors were needed. Intensive chest physiotherapy was initiated. ICD was removed when the column movement was less than 6cm, absence of air leak and drainage was less than 50-100ml per day. Skin sutures were removed after atleast 10 days according to the wound healing.

## RESULTS

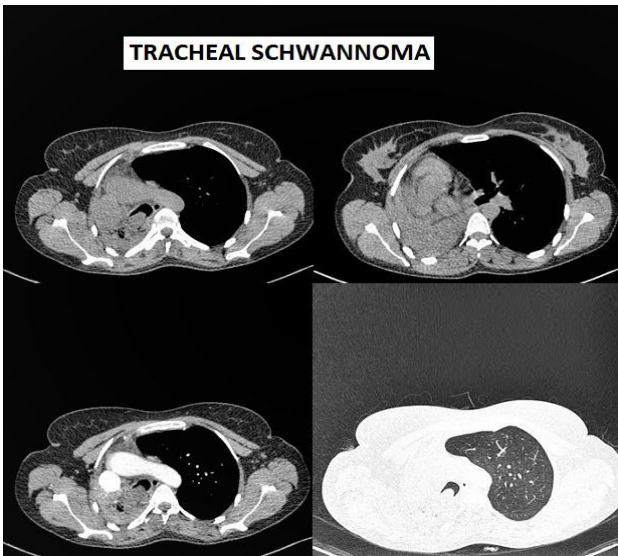
Total 30 cases were done in a span of 2 years. 2/3rd of all patients were male. Of these 9 cases were done for a malignant origin, 4 for benign tumor, 3 for benign non-infective disease and rest 14 for infective origin. Average age of patients operated for neoplasm was 42.15 years (range 20-80 years). Average age of patients operated for benign diseases was 37.8 years (18-60 years).

All surgeries were done by thoracic oncologic surgeon. 28 thoracotomies were done in posterolateral muscle sparing fashion. One was cervical thoracotomy and one with midline sternotomy. Average duration of the procedure was 157 minutes. Average blood loss was approximately 340ml. Mean duration of stay was 10.9 days. It was 12.4 for malignancy group. And 9.8 days for benign diseases. Mean duration of surgery for infected cases was 163 minutes. 157 for malignancy i.e. not significant difference.

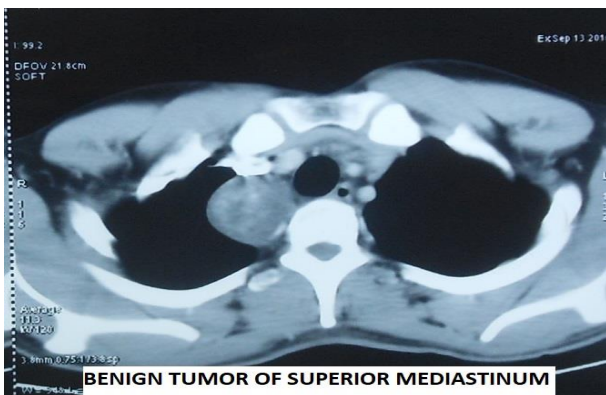
### **Decortication**

All nine patients except one who underwent decortication were harbouring mycobacterium tuberculosis bacteria. This was confirmed by histopathology, AFB culture and CBNAAT (Cartridge Based Nucleic Acid Amplification Test). Most patients (7/9) were having infective disease on the right side, owing to the broader, shorter and more vertical right bronchus. 8 patients had fibroexudative stage of empyema and only one had fibrous empyema. None of the patients had rib resection. Intercostal drainage tube was removed between 2-4 days. Average

duration of stay was 9 days. Duration of stay in our study was inversely proportional to Body Mass Index (BMI) owing to poor nutrition in tuberculosis patients.



**Figure 1: CECT thorax showing right endobronchial, endotracheal mass with collapse consolidation of right lung. cardiome-diastinum and trachea is shifted towards right side. right diaphragm is pulled up. left lung is hyperinflated. multiple enlarged pretracheal, right paratracheal and right hilar lymph nodes.**



**Figure 2: Well defined partially enhancing mass lesion at right thoracic inlet with few calcifications.**

**Lobectomy**

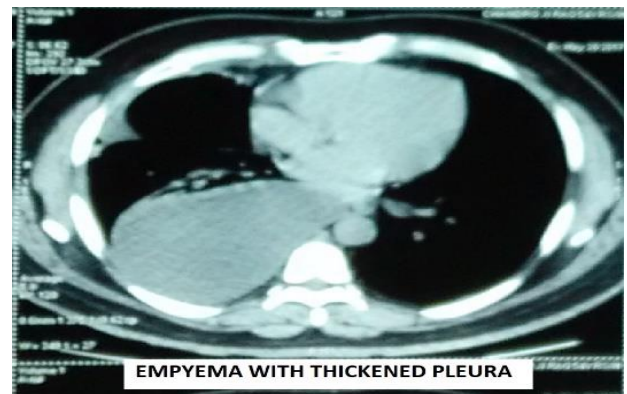
Nine patients had lobectomy. Aspergillosis lead to lobectomy in 3 cases. Two patients had disease on left. All had upper lobes removed. All three were elderly in their 60s. However, none of them were immunocompromised and their post-operative period of ≈ 10 days. Lobectomy was also done for one case each of chronic emphysema superimposed on bronchiectasis, tuberculous empyema and fibrocavitary tuberculosis. Three lobectomies were performed for squamous cell carcinoma of upper lobe of lung.

**Pneumonectomy**

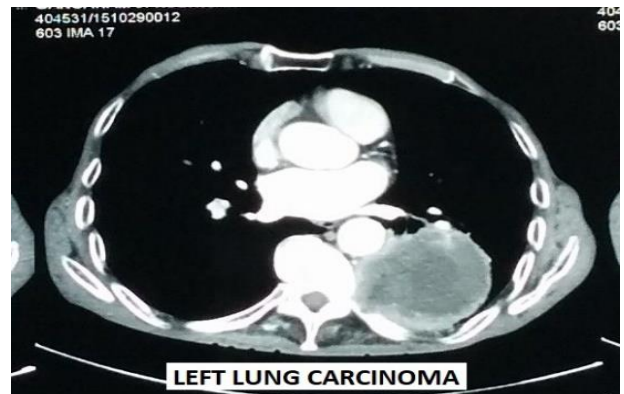
5 patients underwent pneumonectomy. All these patients were intensely prepared for surgery with spirometry, staircase exercises and graded time exercise and proper nutrition. First patient had endobronchial schwannoma of right main bronchus extending upto carina. Pre-operative biopsy on multiple occasions were taken but they revealed misleading and inadequate pathology. Although various papers suggest just excision of this tumor and reanastomosis of tracheobronchial tree, but in our cases due to long standing complete obstruction, there was total destruction of lung. Thus, pneumonectomy was done.

Similar was our second case of bronchial carcinoid. Third case was that of right lower lobe squamous cell carcinoma extending to upper lobe.

Next case was malignant mesothelioma for which extra pleural pneumonectomy was done. Of all the cases presented here, this was the case with maximum morbidity. She had continuous tube drainage, surgical site infection, and a lot of pain probably due to rib resection. However, she recuperated well and was discharged on 26<sup>th</sup> day. Last pneumonectomy was done for diffuse emphysematous lung.



**Figure 3: Large loculated pleural effusion on right side with thickened pleura.**



**Figure 4: Peripherally enhancing mass lesion in left lung with central cystic degeneration.**

### **Tumor excision**

Left thoracotomy was done for well encapsulated tumor of the posterior mediastinum, partially entering the spinal canal. The tumor was removed in toto without breaching the dura. Post op histopathology confirmed ganglioneuroma. Patient did not have any paresis.

Metastectomy was done for primary in testis in two occasions. Repeat thoracotomy was done in another case for ligation of thoracic duct for chylothorax which occurred after tumor was excised from cervical thoracotomy.

### **DISCUSSION**

Until the 1960s, thoracic surgery was done mainly for pulmonary tuberculosis. By 1995, the incidence of histopathologically proven small adenocarcinoma and of peripheral squamous cell carcinoma had increased.

Thus, thoracic surgeons had refined surgical skills with procedures like limited pulmonary resection, and minimally invasive approach to the thorax. Graham published the first left pneumonectomy for primary lung cancer in 1933. In 1960 Cahan recommended anatomical lobectomy with systemic mediastinal lymphadenectomy as “radical lobectomy” to achieve the balanced surgical effects of both curability and functional preservation. In 1993, Lewis introduced the role of video-assisted thoracic surgery (VATS), utilizing thoracoscopy and minithoracotomy for carcinoma of the lung.

Many clinical researches have been performed to evaluate whether thoracoscopic surgery has become truly advantageous for functional preservation and whether it can achieve curability equal to that with conventional open thoracotomy; however, the results remain unclear. With the increase in the average life span, the increase of elderly lung cancer patients has become an important problem surgically. Elderly patients often have concomitant diseases, such as ischemic heart disease, chronic pulmonary disease, and diabetes mellitus, which are serious problems during perioperative periods. Over the past decade, limited pulmonary resection has been utilized for small peripheral lung cancers supported by these phenomena.<sup>2,3</sup>

Subsequently, VATS was introduced to lung cancer surgery as a minimally invasive approach to the thorax, which allows performing anatomical pulmonary resection with lymphadenectomy. Muscle-sparing thoracotomy (MST) was introduced by Ginsberg as an alternative to posterolateral thoracotomy to reduce chest wall injury.<sup>4</sup> As a bridging procedure between VATS and posterolateral thoracotomy, MST has been utilized and investigated regarding invasiveness to the chest wall and the postoperative course.<sup>5</sup> Diagnosis of empyema was confirmed by one of the following criteria:

- Drainage of grossly purulent pleural fluid,
- Pleural fluid culture or Gram stain showing bacteria or,
- Biochemical parameters of empyema (pH < 7.2, lactate dehydrogenase level > 1,000 IU/L, glucose level < 40 mg/dl.).

The three phases of empyema consist of

- Exudative Phase: free-flowing purulent fluid through the thorax and associated inflamed parietal pleura.
- Fibropurulent Phase: loculated pleural fluid and fibrinous exudative deposits on the visceral pleural surfaces.
- Fibrous Phase: formation of a thick, fibrous rind on the visceral pleural surface of the lung.

The objectives in the treatment of empyema are to control persistence of fever, to remove pleural contents, and to fully expand the lung. The ultimate aim is to prevent chronic lung damage. Simple para-pneumonic effusions should be differentiated from empyema by thoracentesis and analysis of fluid.<sup>6</sup>

Staging initially involves plain chest radiographs (including lateral and decubitus views), chest ultrasound, and occasionally, computed tomography. Disease stage determines the choice of intervention. In case of formation of multiloculated collections and fibrinopurulent exudate (stage II), fibrinolysis, VATS assisted adhesiolysis, or open decortication should be considered. In fibrous empyema fibrinolysis and VATS assisted adhesiolysis have no role and thus open decortication should not be delayed or avoided. Timely and meticulously done open surgery results in early chest tube removal, rapid recovery, prompt hospital discharge, and complete resolution.<sup>7</sup>

For the past 50 years, lobectomy has been the standard of care for early-stage lung cancer in patients able to tolerate the procedure. However, lung-sparing procedures such as segmentectomy and wedge resection are becoming more common in the treatment of lung cancer, particularly in elderly patients.<sup>8-10</sup> Lung-sparing procedures enable the preservation of pulmonary function and decrease operative morbidity and mortality in patients with lung cancer.<sup>8</sup>

The cornerstone of physiotherapy management in lung cancer should be prescription and delivery of exercise intervention. Physical activity and exercise are vital components targeting three main aspects of the cancer continuum: prevention, mortality and morbidity. The American cancer society recommends that adults with cancer engage in at least 150 minutes of moderate-intensity aerobic exercise and two sessions of resistance exercise per week, which is the same as the guidelines for the general adult population.<sup>11,12</sup>

It is hypothesised that exercise modulates circulating metabolic and sex-steroid hormone concentrations, immune surveillance, and reduces systemic inflammation/oxidative damage.<sup>13</sup> Prehabilitation is exercise delivered prior to surgery or treatment. The known independent risk factors for PPC are being aged  $\geq 75$  years, having a body mass index  $\geq 30$  kg/m<sup>2</sup>, an Anesthesiologists score  $\geq 3$ , a current smoking history and COPD.<sup>14</sup>

Light showed that gross pus in pleural fluid, bacterial smear and culture positivity, blood glucose less than 40 mg/dL, pleural effusion pH less than 7.2, and loculation are the poor prognostic factors in parapneumonic effusion and empyema treatment outcomes.<sup>15</sup>

Thourani and colleagues reported that surgical decortications reduced the hospital stay compared with simple drainage through a catheter or chest tube.<sup>16</sup>

According to the meta-analysis done after ACCP guidelines were enunciated, all modalities of surgical treatment for empyema, resulted in enhanced success rate when compared with therapeutic thoracocentesis, tube thoracotomy, and fibrinolysis. Also, surgical treatment as compared to simple drainage modalities resulted in paucity in total mortality.<sup>17</sup> Surgical decortication is not necessarily more expensive than simple drainage intervention. In a study that compared cost-effectiveness in adults, the total hospital charge for surgical decortication was not significantly different compared with the costs for catheter drainage and tube thoracotomy.

Malignant pleural mesothelioma (MPM) is a fatal malignancy linked to asbestos exposure for which there is no known cure. The incidence of mesothelioma has increased continuously over the past 20 years.<sup>18</sup> Patients with early-stage disease and good performance status are suitable for multimodality therapy involving surgery, radiotherapy, and chemotherapy.<sup>19</sup>

Extrapleural pneumonectomy (EPP) gained wide acceptance following publications showing prolonged survival in patients with favourable prognostic factors. The goal in all patients was to achieve maximal cytoreduction and a complete macroscopic resection of the tumor (R0 or R1). The study population and clinical setting was selective and limited. Sample size was small. Follow up of patient done in later parts of study was not done

## CONCLUSION

The choice of the first interventional strategy for empyema is critical for treatment success. Even after adjusting for confounding variables, surgical decortication with VATS or thoracotomy is the optimal first line of treatment in patients with advanced

empyema. With increasing experience, a high proportion of lobectomy operations can be safely completed and proportions of pneumonectomies can be brought down. Standardized quality assurance is needed to achieve the goal.

*Funding: No funding sources*

*Conflict of interest: None declared*

*Ethical approval: The study was approved by the Institutional Ethics Committee*

## REFERENCES

1. Sengupta S. Post-operative pulmonary complications after thoracotomy. *Indian J Anaesthesia*. 2015;59(9):618-26.
2. Jensek RJ. Miniresection of small peripheral carcinoma of the lung. *Surg Clin North Am*. 1987;67:951-8.
3. Lung Cancer Study Group (Ginsberg RJ, Rubinstein LV). Randomized trial of lobectomy versus limited resection for T1N0 non-small cell lung cancer. *Ann Thorac Surg*. 1995;60:615-23.
4. Ginsberg RJ. Alternative (muscle sparing) incision in thoracic surgery. *Ann Thorac Surg*. 1993;56:752-4.
5. Giudicelli R, Thomas P, Lonjon T, Ragni J, Morati N, Ottomani R, et al. Video-assisted mini thoracotomy versus muscle-sparing thoracotomy for performing lobectomy. *Annals Tho Surg*. 1994 Sep 1;58(3):712-8.
6. Light RW. A new classification of parapneumonic effusions and empyema. *Chest* 1995;108:299-301.
7. Carey JA, Hamilton JR, Spencer DA, Gould K, Hasan A. Empyema thoracis: a role for open thoracotomy and decortication. *Archives of disease in childhood*. 1998 Dec 1;79(6):510-3.
8. Pastorino U, Valente M, Bedini V, Infante M, Tavecchio L, Gherardini G, Ravasi G. Limited resection for stage I lung cancer. *Lung Cancer*. 1991 Jan 1;7:85.
9. Miller JJ, Hatcher CR Jr. Limited resection of bronchogenic carcinoma in the patient with marked impairment of pulmonary function. *Ann Thorac Surg*. 1987;44:340-43.
10. Jaklitsch MT, Mery CM, Bueno R, Vasconcelles MJ, Richards WG, Mentzer S, et al. Lesser pulmonary resections are more common in elderly non-small cell lung cancer (NSCLC) patients but do not adversely affect survival. *In Proc Am Soc Clin Oncol* 1999 (Vol. 18, p. 471a).
11. Rock C, Doyle C, Demark-Wahnefried W, Meyerhardt J, Courneya K, Schwartz A, et al. Nutrition and physical activity guidelines for cancer survivors. *CA: A Cancer J Clin*. 2013;62:242-74.
12. Biswas A, Oh P, Faulkner G, Bajaj R, Silver M, Mitchell M, et al. Sedentary time and its association with risk for disease incidence, mortality and hospitalization in adults: a systematic review and meta-analysis. *Annals Int Med*. 2015;162:123-32.

13. McTiernan A. Mechanisms linking physical activity with cancer. *Nat Rev Cancer.* 2008;8:205-11.
14. Agostini P, Cieslik H, Rathinam S, Bishay E, Kalkat M, Rajesh P, et al. Postoperative pulmonary complications following thoracic surgery: are there any modifiable risk factors? *Thorax.* 2010;65:815-818.
15. Light RW. Parapneumonic effusions and empyema. *Proc Am Thorac Soc.* 2006;3:75-80.
16. Thourani VH, Brady KM, Mansour KA, Miller JI Jr, Lee RB. Evaluation of treatment modalities for thoracic empyema: a cost-effectiveness analysis. *Ann Thorac Surg.* 1998;66:1121-7.
17. Colice GL, Curtis A, Deslauriers J, Heffner J, Light R, Littenberg B, et al. Medical and surgical treatment of parapneumonic effusions: an evidence-based guideline. *Chest.* 2000;118:1158-71.
18. Peto J, Decarli A, La Vecchia C, Levi F, Negri E. The European mesothelioma epidemic. *Br J Cancer.* 1999;79:666-72.
19. Maziak DE, Gagliardi A, Haynes AE, Mackay JA, Evans WK. Surgical management of malignant pleural mesothelioma: a systematic review and evidence summary. *Lung Cancer.* 2005;48:157-69.

**Cite this article as:** Ahmad Z, Agrawal D, Desai SM, Jain A. A clinical audit of thoracotomy done in a tertiary care center. *Int J Res Med Sci* 2018;6:2012-7.