

Research Article

Clinical profile and outcome of Hantavirus infection with renal involvement in India

Alok Kumar*, Dorchhom Khrame, Nitin Bansal, Amar Nath Pandey,
Shakeel Ahmad, Varma Amit

Department of Medicine, Shri Guru Ram Rai Institute of Medical and Health Sciences, Dehradun, Uttarakhand, India

Received: 19 March 2014

Accepted: 5 April 2014

*Correspondence:

Dr. Alok Kumar,

E-mail: alokkraj@rediffmail.com

© 2014 Kumar A et al. This is an open-access article distributed under the terms of the Creative Commons Attribution Non-Commercial License, which permits unrestricted non-commercial use, distribution, and reproduction in any medium, provided the original work is properly cited.

ABSTRACT

Background: Hantavirus infections are found all over world but there is paucity of information about clinical features of Hantavirus infection in India. Aim of current study was to study clinical profile and outcome of patients with Hantavirus infection and renal insufficiency who presented at our institute.

Methods: All patients who were admitted in department of medicine with Hantavirus infection and renal insufficiency were included. Their basic demographic profile with relevant laboratory investigations was recorded. They were diagnosed with Hantavirus infection if they had positive IgM antibodies by ELISA test.

Results: There were seven patients with mean age of 54 years. They had mean serum creatinine level of 4.37 ± 1.86 mg%. All had thrombocytopenia and hepatic dysfunction as well. Five patients had hypotension. There was need of dialysis in three patients. They also had hypoalbuminemia. No patient had features suggestive of acute respiratory distress syndrome. All patients had recovery of renal function and there was no mortality.

Conclusion: Patients with Hantavirus infection presented like hemorrhagic fever with renal syndrome. Their outcome is good. We need to suspect Hantavirus infection in appropriate clinical scenario in India.

Keywords: Hantavirus infection, Renal insufficiency, Hypoalbuminemia, Thrombocytopenia

INTRODUCTION

Hantavirus infections are well recognized zoonoses worldwide. Hantaan virus was the first Hantavirus isolated in 1976.¹ Hantaviruses are members of the virus family, Bunyaviridae and are enveloped, single-stranded RNA viruses. The virus is rodent-borne and transmission is via aerosols of excreta, saliva and urine.²

The common clinical patterns include hemorrhagic fever with renal syndrome (HFRS) or Hantavirus pulmonary syndrome. HFRS is a kind of clinically similar illnesses sharing hemorrhagic fever with renal dysfunction and caused by Hantaan virus (HTNV), Seoul virus (SEOV), Dobrava virus (DOBV) and Thailand virus (THAIV).³

HPS is found mainly in USA and is caused by Sin Nombre and 15 other viruses.⁴

Though Hantavirus infection is found in many parts of Asia and world but there is paucity of information on clinical presentation and outcome of Hantavirus infection in India. We report here clinical characteristics and outcome of seven cases of Hantavirus infection with renal involvement who presented in department of medicine at our institute.

METHODS

We studied seven cases of Hantavirus infection and renal involvement who presented at our institute in last 4 months. Their demographic profile and presenting

clinical features were recorded. Their laboratory parameters Hemoglobin (Hb), Total Leukocyte Count (TLC), Differential Leucocyte Count (DLC) and Platelets with serial renal function test (blood urea, serum creatinine) were recorded. We also noted Serum Bilirubin, Alanine Transaminase (ALT), Aspartate transaminase (AST). Their coagulation parameters (Prothrombin Time (PT) and Activated Partial Thromboplastin Time (APTT) were also done. Their serum albumin, urine examination and other relevant laboratory parameters were also recorded.

All patients underwent chest X ray and ultrasound examination for abdomen. All patients underwent urine routine and microscopy examination. Their clinical parameters like presence of hypotension, edema, any evidence of bleeding, dyspnoea and presence of uremic symptoms; hypoxia and need for intensive care were analyzed. Their blood smear was examined for presence

of atypical lymphocytes. All of them were followed till discharge. Patients were identified as suffering from Hantavirus infection on the basis of positive ELISA tests to detect IgM antibodies (Focus technologies, Cypress, California, USA). They were also tested for malaria, dengue and leptospirosis.

RESULTS

There were seven patients. Their mean age was 54 ± 10.97 years. There were four females and three males. Their mean serum urea level was 144.86 ± 75.30 mg% and serum creatinine level was 4.37 ± 1.86 mg%. We found mean serum bilirubin of 1.27 ± 0.70 mg%. Their mean AST and ALT level were 89.29 ± 43.16 mg% and 56.14 ± 21.69 mg%. Their mean platelet count was 82142 ± 36269 / mm³ and mean serum albumin was 2.28 ± 0.35 gm%. Basic demographic data and relevant investigations have been shown in Table 1.

Table 1: Showing demographic profile and relevant investigations.

Age	Sex	Urea (mg%)	S. creatinine (mg%)	S. bilirubin (mg%)	SGOT/SGPT (unit/L)	S. albumin (gm%)	Hb (gm%)	TLC (/mm ³)	Platelets (/mm ³)
50	Female	118	3.1	1.8	155/86	2	12.6	8300	60000
52	Female	106	7.3	0.9	122/ 74	2.1	7.3	24600	120000
55	Male	223	6.3	0.7	34/25	2.6	11.8	19000	65000
45	Female	106	2.1	2.8	112/ 65	1.9	10.5	13700	100000
40	Female	91	3.8	1.2	55/45	2.9	12.4	13100	112000
72	Male	280	4.8	1.6	39/36	2.3	12.7	11800	20000
64	Male	90	3.2	.9	90	2.2	15.2	5800	90000

They presented with history of fever, abdominal pain, myalgia, anorexia and edema. Five patients suffered hypotension and needed vasopressor support. Four patients had oliguric acute renal failure. All patients had edema and hypoxia. One patient had convulsions. Three patients (42.9%) needed intensive care admission. Three patients needed dialysis and hemodialysis was performed based on clinical and biochemical parameters. Figure 1 shows important clinical features of patients. Derangement of liver enzymes was observed in four patients and hyponatremia was also seen in three patients. Hypoalbuminemia (serum albumin <3 gm%) was present in all patients. We observed thrombocytopenia in all patients and Leukocytosis was also seen in six patients. Atypical lymphocytes were seen in all patients. All patients had derangement of coagulation profile. Their APTT was 42.5 ± 8.3 seconds and PT was 14.6 ± 2.5 seconds'. One patient had clinical evidence of hemorrhage in form of hematemesis and needed platelet transfusion. Four patients had sub conjunctival hemorrhage. Urine examination showed proteinuria trace to ++ in all cases and microscopic hematuria in 7 cases. Evidence of serositis was found in six patients in form of ascites and plural effusion by ultrasound.

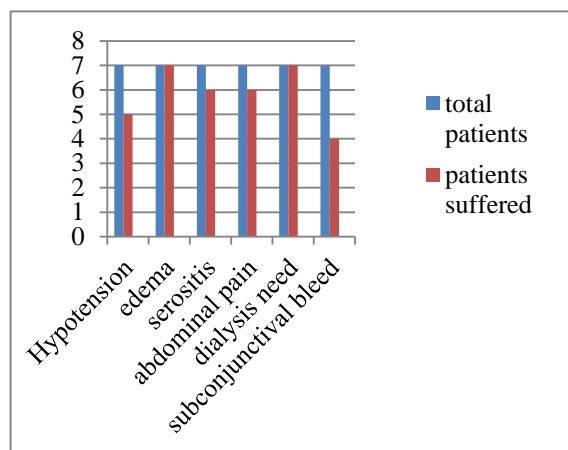


Figure 1: Showing important clinical features.

DISCUSSION

Hantavirus related HFRS classically presents with high fever, myalgia, headache, conjunctival suffusion and hemorrhage, petechial rash, nausea, vomiting and abdominal pain. It has incubation period ranging from 4

to 42 days. It is described in five clinical phases: febrile, hypotensive, oliguric, diuretic and convalescent. However, there may be overlap in many cases. Evidence of renal failure is observed usually by 5th day of the illness.⁵ Our patients presented to us 8-10 days after onset of disease. All of them had renal failure at that time, which is consistent with usual course. Our patients had oliguric renal failure in approximately 43 % (3 cases) patients. It may be variation as overlap of different stages has been described. Non oliguric renal failure has been described in 50% patients with HFRS.⁶ Our patients had deranged hepatic enzymes in majority (72%) but did not reach high level. It has been found in HFRS.⁶

Many patients of Hantavirus infection have thrombocytopenia and elevated ALT values but no renal disease.⁷ Elevated hepatic enzymes are common but do not reach high levels. Patients with HFRS shows prolonged partial thromboplastin time and left shift of leukocyte in peripheral blood smear and there are reports of mild renal abnormalities like proteinuria and hematuria.⁷ Atypical lymphocytes were seen in all patients. These represent activated CD8 cells or occasionally CD4 cells.⁶ Gastrointestinal symptoms have been reported commonly in Hantavirus infection.⁸ Our patients had prominent gastrointestinal symptoms in form of pain abdomen, vomiting. These were so severe in two cases that those case were admitted in surgery ward initially. We found clinically significant evidence of hemorrhage in only one patient in form of melena while it was almost universal in other series reported by Mehta et al from India.⁹ Though our patients also had hypoxia but there was no clinical or radiological evidence to suggest acute respiratory syndrome as in study by Mehta et al. There have been reports of respiratory symptoms in 30-50% of patients with HFRS.¹⁰ Our patients presented as renal failure predominantly while it was mainly pulmonary involvement in their study. There are reports to support that only 20% of acute HFRS cases are positive for Hantavirus RNA by reverse transcriptase PCR. There is no need to detect Hantavirus RNA by reverse transcriptase PCR for routine diagnosis.¹¹ Serological positivity is sufficient to diagnose Hantavirus infection in appropriate clinical scenario.

Chandy et al. described in their study of 152 serum samples that 23 (14.7%) individuals with febrile illness were positive for anti-hantavirus IgM while 5.7% of healthy blood donor samples were positive.¹² This study points towards existence of hantavirus infection in Indian population.. Another study reported Seoul virus like infection in 12% and Puumala virus like infection in 5% of Indian patients presenting with a leptospirosis-like symptoms' from south India.¹³

Hantavirus infection related renal failure varies in severity from place to place from mild renal failure to high mortality. We did not find any mortality in our patients. Patient with HFRS described in case report by S. Chandy et al. also survived. It appears patients with

HFRS has good outcome in India. Outcome of HFRS could vary according to causative agent.¹⁴

CONCLUSION

We must look for evidence of Hantavirus infection in patients presenting with fever, renal failure, thrombocytopenia, serositis, edema, hypoalbuminemia, hepatic dysfunction, hypoxia and prominent gastrointestinal symptoms. We found good outcome in these patients. Malaria, leptospirosis, dengue fever and scrub typhus are important differential diagnosis to consider in such clinical scenario.

Key message

Patients with Hantavirus infection presented as hemorrhagic fever with renal syndrome in our study. They had good outcome. Hantavirus infection should be suspected in patients with fever, renal failure, thrombocytopenia, edema and hypoalbuminemia.

Funding: No funding sources

Conflict of interest: None declared

Ethical approval: Not required

REFERENCES

1. Lee HW, Lee PW, Johnson KM. Isolation of the etiologic agent of Korean hemorrhagic fever. *J Infect Dis.* 1978;137:298-308.
2. McCaughey C, Hart CA. Hantaviruses. *J Med Microbiol.* 2000;49:587-99.
3. Chandy S, Mitra S, Sathish N, Vijayakumar TS, Abraham OC, Jesudason MV et al. A pilot study for serological evidence of Hantavirus infection in human population in south India. *Indian J Med Res.* 2005;122:211-5.
4. Nichol ST, Spiropoulou CF, Morzunov S, Rollin PE, Ksiazek TG, Feldmann H, Sanchez A, Childs J, Zaki S, Peters CJ. Genetic identification of a Hanta virus associated with an outbreak of acute respiratory illness. *Sci.* 1993;262:914-7.
5. Kruger DH, Rainer U, Lundkvist A. Hantavirus infections and their prevention. *Microbes Infect.* 2001;3:1129-44.
6. Peters CJ. Infections caused by arthropod and rodent borne viruses. In: Longo DL, Kasper DL, Jameson JL, Fauci AS, Hauser SL, Loscalzo J, eds. *Harrison's Principles of Internal Medicine.* 18th ed. New York: Mc Graw Hill; 2012: 1630-1631.
7. Peters CJ, Simpson GL, Levy H. Spectrum of Hantavirus infection: Hemorrhagic fever with renal syndrome and hantavirus pulmonary syndrome. *Annu Rev Med.* 1999;50:531-45.
8. Golovljova I, Vasilenko V, Mittzenkov V, Prukk T, Seppet E, Vene S et al. Characterization of hemorrhagic fever with renal syndrome caused by hantaviruses, Estonia. *Emerg Infect Dis.* 2007;13:1773-6.

9. Mehta S, Jiandani P. Ocular features of Hantavirus infection. *Indian J Ophthalmol.* 2007;55:378-80.
10. Nguyen AT, Penalba C, Bernadac P, Jaafar S, Kessler M, Canton P, Hoen B. Respiratory manifestations of hemorrhagic fever with renal syndrome. Retrospective study of 129 cases in Champagne-Ardenne and Lorraine. *Presse Med.* 2001;30:55-8.
11. Miyamoto H, Kariwa H, Araki K, Lokugamage K, Hayasaka D, Cui BZ et al. Serological analysis of hemorrhagic fever with renal syndrome (HFRS) patients in far Eastern Russia and identification of the causative hantavirus genotype. *Arch Virol.* 2003;148:1543-56.
12. Chandy S, Mitra S, Sathish N, Vijayakumar TS, Abraham OC, Jesudason MV et al. A pilot study for serological evidence of Hanta virus infection in human population in south India. *Indian J Med Res.* 2005;122:211-5.
13. Clement J, Maes P, Muthusethupathi M, Nainan G, van Ranst M. First evidence of fatal Hanta virus nephropathy in India, mimicking leptospirosis. *Nephrol Dial Transplant.* 2006;21:826-7.
14. Lázaro ME, Cantoni GE, Calanni LM, Resa AJ, Herrero ER, Iacono MA, Enria DA, González Cappa SM. Clusters of hantavirus infection, southern Argentina. *Emerg Infect Dis.* 2007;13:104-10.

DOI: 10.5455/2320-6012.ijrms20140563

Cite this article as: Kumar A, Khrame D, Bansal N, Pandey AM, Ahmad S, Varma A. Clinical profile and outcome of Hantavirus infection with renal involvement in India. *Int J Res Med Sci* 2014;2:704-7.