

## Research Article

# A retrospective study of post-operative gall bladder pathology with special reference to incidental carcinoma of the gall bladder

Jagannath Dev Sharma<sup>1\*</sup>, Indrajit Kalita<sup>2</sup>, Tonmoy Das<sup>3</sup>,  
Papari Goswami<sup>2</sup>, Manigreeva Krishnatreya<sup>4</sup>

<sup>1</sup>Department of Pathology, Dr. B. Borooah Cancer Institute, Guwahati-781016, Assam, India

<sup>2</sup>Department of Pathology, International Hospital, Guwahati-781005, Assam, India

<sup>3</sup>Executive Director, International Hospital, Guwahati-781005, Assam, India

<sup>4</sup>Department of Epidemiology, Dr. B. Borooah Cancer Institute, Guwahati-781016, Assam, India

**Received:** 10 June 2014

**Accepted:** 2 July 2014

### \*Correspondence:

Dr. Jagannath Dev Sharma,

E-mail: dr\_j\_sarma@rediffmail.com

© 2014 Sharma JD et al. This is an open-access article distributed under the terms of the Creative Commons Attribution Non-Commercial License, which permits unrestricted non-commercial use, distribution, and reproduction in any medium, provided the original work is properly cited.

## ABSTRACT

**Background:** Surgical removal of gall bladder for its diseases is common. However, not much is known about the incidence of incidental carcinoma in such patients in our population. Objective of current study was to analyze the different pathological entities of post-operative gall bladder specimen with particular emphasis on incidental carcinoma.

**Methods:** This retrospective study was carried out at a multi-specialty hospital in eastern India from the pathology records for the period from August 2005 to July 2008. The records were analyzed for gender, age group distribution, and pathological types with different histology.

**Results:** Out of 863 records, chronic cholecystitis 51.2% was the most common histology and malignancy was seen in 2.7% (23/863) both pre-operative and post-operative diagnosis. In the neoplastic group incidental carcinoma was diagnosed in 1.9% (17/23) of cases

**Conclusion:** Histopathological examination of gallbladder specimen helps to identify non-neoplastic conditions with its complications and also, for the detection of incidental carcinoma. Thorough sampling of all gallbladder specimens is a must to detect focal neoplastic changes.

**Keywords:** Carcinoma gall bladder, Cholecystitis, Gall bladder pathology, Incidental carcinoma

## INTRODUCTION

Gallbladder diseases are very common disorder in the population of gangetic belt of northern India. Recent data of the national cancer registry programme of India has shown a high age adjusted incidence rates (AAR) of gallbladder cancer in the female population of Kamrup (Urban) district, which is amongst the highest in the world.<sup>1</sup> Moreover, earlier also, Nandakumar et al. have identified this region as a geographically high risk area for carcinoma of the gall bladder.<sup>2</sup> Despite the advent of sophisticated radiological diagnostic modalities currently

available, gallbladder carcinoma has a high mortality index. 80% patients with carcinoma of the gall bladder have locally advanced or metastatic disease at presentation.<sup>3</sup> Thus, most of the cases cannot be operated upon due to its advanced stage, so gall bladder specimens are not often available for histopathological examination. Also, the incidence of incidental carcinoma in such patients operated for gall bladder disease of our population is not known. Presence of gallstone, chronic cholecystitis and epithelial dysplasia are some of the yet poorly understood risk factors for carcinoma of the gallbladder. In this study we attempted to analyze the

different pathological entities of post-operative gall bladder specimen with particular emphasis on incidental carcinoma.

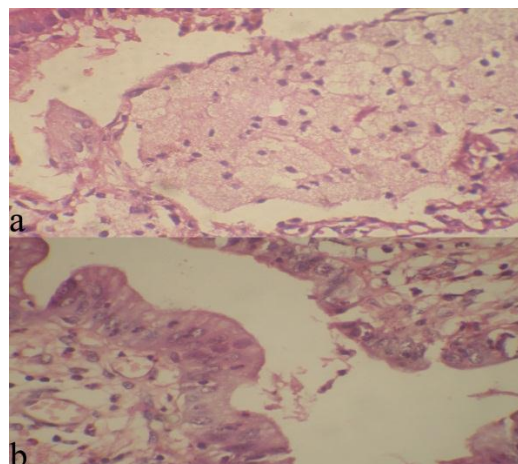
**METHODS**

This retrospective study was carried out at a multi-specialty hospital in eastern India. The records on pathology reports of gallbladder specimens were obtained from the department of pathology for patients operated from August 2005 to July 2008. The records were analyzed for gender, age group distribution, and pathological types with different histology. All the gallbladder specimens that were received in department of pathology were examined macroscopically and microscopically. Adequate tissue sections were also taken from the representative areas which were routinely processed. Tissue sections were stained with hematoxylin and eosin stain for microscopic examination by 3 pathologists. The results of our analysis are presented as percentages.

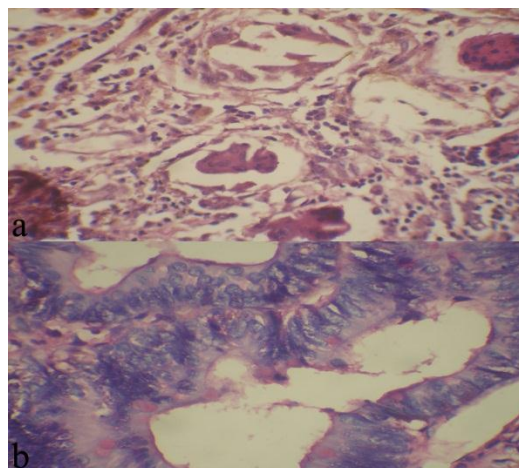
**RESULTS**

A total of 863 patients underwent gall bladder surgery during this period. Out of 863 cases, there were 64% (560/863) female patients and 36% (303/863) male patients. Relative proportion of different gallbladder diseases were, Chronic Cholecystitis (CC) 51.2% (442/863), Chronic Active Cholecystitis (CAC) in 40.4% (349/863), Acute Cholecystitis (AC) in 4.6% (40/863), neoplastic in 2.7% (23/863) and Xantho-Granulomatous Cholecystitis (XGC) in 1.04% (9/863) of patients. Broadly, the histology of different pathological entities was CC (Figure 1a), CAC (Figure 1b), XGC (Figure 2a) and neoplastic gall bladder (Figure 2b). The peak age group of CC was at 21-40 years and for CAC was 41-60 years. AC and XGC showed an equal predilection at 21-40 years and 41-60 years of age (Table 1). All the cases of XGC had associated cholelithiasis but, there was no evidence of tumor formation in the gallbladder specimen associated with XGC. Out of the total 23 neoplastic lesions, six patients were with carcinoma diagnosed preoperatively and 17 cases were incidental gall bladder carcinoma. The age range of neoplastic lesions was from 28 to 78 years of age with the peak age group at 41-60 years of age (78%) as shown in Table 1. The gender distribution was 16 patients were female and seven patients were males. Microscopically, three cases were of in- situ carcinoma 17.6% (3/17) and 82.3% (14/17) were invasive carcinoma. Clinically all the cases of incidental carcinoma were diagnosed as cholecystitis and 15 patients (88%) of invasive carcinoma had associated gallstones. Macroscopically all the cases showed thickened wall and the mucosa was eroded and nodular, small polypoid elevations. The distribution of invasive carcinoma of the gall bladder was well differentiated adenocarcinoma in 79% (11/14), mucinous carcinoma in 7% (1/14), adenosquamous carcinoma in 7% (1/14), and

in 7% (1/14) patients the histology was poorly differentiated carcinoma.



**Figure 1: Photomicrograph with H and E stain (40x) showing (a) chronic cholecystitis with cholesterosis, (b) neutrophils in the epithelium showing stratification suggestive of chronic on active cholecystitis.**



**Figure 2: Photomicrograph with H and E stain (40X) showing (a) xanthogranulomatous cholecystitis with xanthoma cell and multinucleated giant cells, (b) adenocarcinoma of the gall bladder showing severe architectural and cytological atypia.**

**Table 1: Shows the age group distribution in the various pathological entities of resected specimen of gall bladder.**

Age group	CC	CAC	AC	XGC	Neoplastic
0-20	22	19	3	0	0
21-40	205	140	16	4	1
41-60	177	149	16	4	18
Above 60	38	41	5	1	4

CC = chronic cholecystitis, CAC = Chronic on active cholecystitis, XGC = xantho-granulomatous cholecystitis

## DISCUSSION

In comparison to the western countries, the incidence of gallbladder carcinoma is high in India. Despite being the most common malignancy of the biliary tract, it is nearly always diagnosed at an advanced stage when the tumor has invaded the adjacent organs.<sup>4</sup> Incidental gallbladder carcinoma is defined as whenever gallbladder carcinoma is found on histopathology after the gallbladder has been removed for symptomatic benign gallbladder disease with or without gallstones.<sup>5</sup> In our analysis, incidental carcinoma of gall bladder showed a female preponderance (M:F=2.2:1). Vast majority of patients in our analysis with incidental carcinoma of the gall bladder were seen in the age group of 41-60 years. The reported incidence of incidental gallbladder carcinoma varies from 0.35% to 2%.<sup>6-8</sup> A previous history of gallstones was found in 75% to 98% of cases of incidental gallbladder carcinoma.<sup>9,10</sup> In our analysis, 88% of patients with incidental carcinoma had co-existing cholelithiasis. Deguara et al. had reported 1% cases of incidental gallbladder carcinoma in their study of 2577 cholecystectomies,<sup>11</sup> Khan et al. reported 1.86%,<sup>9</sup> Daphna et al. 0.35%,<sup>12</sup> and Ahmad et al. had reported it around 1.45%.<sup>10</sup> In the present study, the prevalence was 1.97%. Our analysis has shown a very high proportion of incidental gall bladder carcinoma in a relatively small sample size, which underscores the high risk of gall bladder in our population. Moreover, our analysis has shown that in the age group of 41-60 years most of the incidental cases of carcinoma gall bladder are likely to be detected. This was similar age group to that of CC which was treated by surgery. Treatment policy for patients with incidental gallbladder carcinoma depends on the depth of invasion by the tumor. Tumor stage is the most important prognostic factor.<sup>13</sup> T<sub>is</sub> and T1a gallbladder carcinoma can be treated by simple cholecystectomy. However, in T1b and above stage cancer requires extended cholecystectomy, which is important for improving the long term prognosis.<sup>5,14</sup>

Laparoscopic cholecystectomy has been contraindicated in the presence of gallbladder cancer.<sup>5</sup> Amongst the different types of cholecystitis, XGC merits special mention. It is an inflammatory lesion of the gallbladder characterized by marked proliferative fibrosis and infiltration of macrophages and foam cells involving the wall of the gallbladder. The reported prevalence varies from 0.66% to 1.8% and 91% to 100% cases have associated cholelithiasis.<sup>15,16</sup> Although XGC is not an exceptional finding, it is important because very few reports have described XGC with aggressive tumor like inflammation pattern. Spinelli et al. has reported a case of XGC which clinically and radiologically presented as an advanced gallbladder carcinoma with involvement of adjacent organs and structures.<sup>17</sup> Prevalence of XGC in our study was 1.04% but none of the cases of XGC mimicked a malignant lesion clinically or radiologically. So, fine needle aspiration biopsy and intraoperative frozen section may be helpful in the diagnosis. 100% of

cases of XGC in our analysis had associated cholelithiasis. XGC and gallbladder carcinoma may co-exist. Shukla et al. have shown that the high incidence of carcinoma gall bladder along the gangetic belt of northern India which is probably due to the presence of heavy metals like cadmium, mercury and lead in gall bladder specimens of patients.<sup>18</sup> Since, specimens of the gall bladder due to carcinoma are mostly available due to incidental diagnosis, so, similar studies on cases with incidental diagnosis of gall bladder carcinoma is imperative to establish such an association in our population as well. The morphologic changes in the gallbladder specimens are not available for a sequential follow-up study for the development of carcinoma from dysplastic lesions in cholecystectomized patients. So, the prognostic significance of this study is low in this regard.

## CONCLUSION

Histopathological examination of gallbladder specimen helps to identify non-neoplastic conditions with its complications and also, for the detection of incidental carcinoma. Thorough sampling of all gallbladder specimens is a must to detect focal neoplastic changes.

*Funding: No funding sources*

*Conflict of interest: None declared*

*Ethical approval: The study was approved by the institutional review board*

## REFERENCES

1. National Center for Disease Informatics and Research (NCDIR). Consolidated report of population based cancer registries of India 2009-2011. In: V. M. Katoch, eds. NCDIR Report. Bangalore: ICMR; 2013: 1-210.
2. Nandakumar A, Gupta PC, Gangadharan P, Visweswara RN, Parkin DM. Geographic pathology revisited: development of an atlas of cancer in India. *Int J Cancer.* 2005;116:740-54.
3. Kiran CS, Das P, Agarwal N, Gupta SD. Pathology of Gallbladder Carcinoma in India: an overview. *Indian J Med Paediatr Oncol.* 2007;28(Suppl 2):16-24.
4. Kapoor VK, Pradeep R, Haribhakti SP, Sikora SS, Kaushik SP. Early carcinoma of the gallbladder: an elusive disease. *J Surg Oncol.* 1996;62:284-7.
5. Misra MC, Guleria S. Management of cancer gallbladder found as a surprise on a resected gallbladder specimen. *J Surg Oncol.* 2006;93:690-8.
6. Kimura W, Nagai H, Kuroda A, Morioka Y. Clinicopathologic study of asymptomatic gallbladder carcinoma found at autopsy. *Cancer.* 1989;64:98-103.
7. Silk YN, Douglass HO, Nava Jr HR, Driscoll DL, Tartarian G. Carcinoma of the gallbladder. The Roswell Park experience. *Ann Surg.* 1989;210:751-7.

8. Paolucci V, Schaeff B, Schneider M, Gutt C. Tumor seeding following laparoscopy: international survey. *World J Surg.* 1999;23:989-97.
9. Khan MA, Khan RA, Siddiqui S, Maheshwari V. Occult carcinoma of gallbladder: incidence and role of simple cholecystectomy. *J-K Practitioner.* 2007;14:22-3.
10. Elian A. Occult gallbladder carcinoma. *Tanta Med Sc J.* 2007;2:58-64.
11. Deguara J, Borg CM, Laferia G. Incidental gallbladder carcinoma in the Maltese Archipelago. *Malta Med J.* 2003;15(Suppl 1):1728-9.
12. Weinstein D, Herbert M, Bendet N, Sandbank J, Halevy A. Incidental finding of gallbladder carcinoma. *Israel Med Assoc J.* 2002;5:334 -6.
13. Eugenio C, Cesare T, Giuseppinella M, Iapichino G, Currò G. Incidental gall bladder carcinoma: does the surgical approach influence the outcome? *ANZ J Surg.* 2005;75:795-8.
14. Sikora SS, Singh RK. Surgical strategies in patients with gallbladder cancer: nihilism to optimism. *J Surg Oncol.* 2006;93:670-81.
15. Dixit VK, Prakash A, Gupta A, Pandey M, Gautam A, Kumar M, et al. Xanthogranulomatous cholecystitis. *Dig Dis Sci.* 1998;43:940-42.
16. Kwon AH, Matsui Y, Uemura Y. Surgical procedures and histopathologic findings for patients with xanthogranulomatous cholecystitis. *J Am Coll Surg.* 2004;199:204-10.
17. Spinelli A, Schumacher G, Pascher A, Lopez-Hanninen E, Al-Abadi H, Benckert C, et al. Extended surgical resection for xanthogranulomatous cholecystitis mimicking advanced gallbladder carcinoma: a case report and review of literature. *World J Gastroenterol.* 2006;12:2293-6.
18. Shukla VK, Prakash A, Tripathi BD, Reddy DCS, Singh S. Biliary heavy metal concentrations in carcinoma of the gall bladder: case-control study. *Br Med J.* 1998;317:1288-9.

DOI: 10.5455/2320-6012.ijrms20140871

**Cite this article as:** Sharma JD, Kalita I, Das T, Goswami P, Krishnatreya M. A retrospective study of post-operative gall bladder pathology with special reference to incidental carcinoma of the gall bladder. *Int J Res Med Sci* 2014;2:1050-3.