

Case Report

A rare case of xanthogranulomatous cervicitis in post radiation radical hysterectomy

Padmanaban K. Govindaraman^{1*}, S. Marimuthu²

¹Department of Pathology, Thanjavur medical college and hospital, Thanjavur, Tamilnadu, India

²Department of Surgical Oncology, Thanjavur medical college hospital, Thanjavur, Tamilnadu, India

Received: 26 May 2016

Revised: 27 May 2016

Accepted: 15 June 2016

*Correspondence:

Dr. Padmanaban K. Govindaraman,

E-mail: padmanabankg@yahoo.in

Copyright: © the author(s), publisher and licensee Medip Academy. This is an open-access article distributed under the terms of the Creative Commons Attribution Non-Commercial License, which permits unrestricted non-commercial use, distribution, and reproduction in any medium, provided the original work is properly cited.

ABSTRACT

Xanthogranulomatous inflammation is a distinguished form of chronic inflammation affecting several organs, predominantly the kidney and gallbladder. Involvement of female genital tract is rare. So far only one case of xanthogranulomatous inflammation of cervix has been reported in Indian literature. We report a case of xanthogranulomatous cervicitis in a 38 year female who had undergone radiotherapy for carcinoma cervix. Probably this is the first case in Indian literature to be reported in the setting of carcinoma of cervix.

Keywords: Xanthogranulomatous, Cervicitis, Inflammation, Carcinoma

INTRODUCTION

Xanthogranulomatous inflammation is characterized by xanthogranuloma composed of foamy histiocytes, hemosiderin laden macrophages and foreign body giant cells. Kidney, gall bladder, salivary glands and bones are well known to be involved by xanthogranulomatous inflammation.¹ Xanthogranulomatous inflammation of the female genital tract is rare. It most often affects the endometrium, but involvement of the cervix, vagina, fallopian tube and ovary may also rarely occur.^{2,3}

CASE REPORT

We report a case of a 38 year female presented with bleeding per vaginum for past six months. Speculum examination revealed an ulcerated growth in cervix. A punch biopsy was taken from the growth and histopathological examination revealed squamous cell carcinoma moderately differentiated (Figure 1). Preoperative external beam radiation was given as the

disease was locally advanced clinically. Subsequently, radical hysterectomy with bilateral pelvic node dissection was done.

Grossly, uterus with cervix measured 8x5x2 cm, cut surface revealed a yellowish nodule in the cervix measuring about 1 cm in the posterior lip (Figure 2). Histopathological examination revealed collections of foamy macrophages, lymphocytes and few foreign body giant cells surrounding cholesterol clefts (Figure 3A and B). Lining squamous epithelium of cervix revealed radiation induced atypia (Figure 3A). No residual malignancy was found. Endometrium revealed proliferative phase glands, no endometritis was noted. Bilateral adnexae and pelvic nodes were free of tumor. Gram staining of the cervical tissue did not reveal any microorganisms. Other basic investigations were within normal limits.

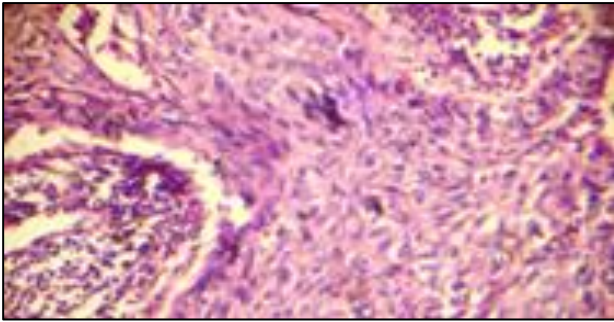


Figure 1: Photomicrograph of squamous cell carcinoma; H and E 100x.



Figure 2: Hysterectomy specimen exhibiting yellowish nodule in cervix (pointed with forceps).

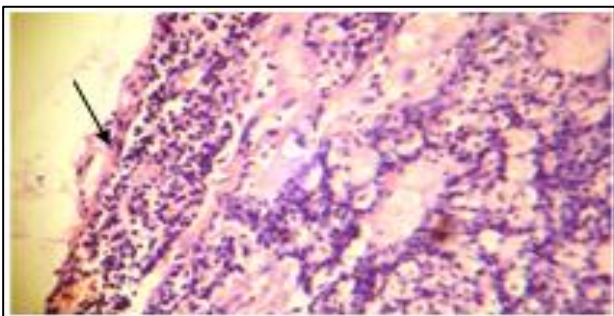


Figure 3a: Photomicrograph exhibiting foamy macrophages, chronic inflammatory cells beneath squamous epithelium (arrow) H and E 100x.

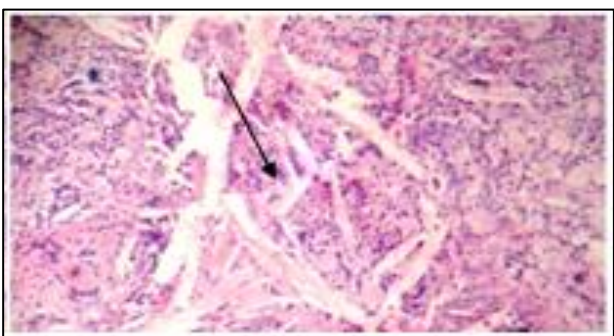


Figure 3b: Cholesterol clefts (arrow) surrounded by foamy macrophages. H and E.100X.

DISCUSSION

Ladefoged et al found that only 19 cases of xanthogranulomatous inflammation of female genital tract had been reported in the literature.³ Most of the them have been reported in Endometrium, ovary and fallopian tube.^{4,5} Till date only one case of xanthogranulomatous cervicitis has been reported in India and this is the second case to be documented to our knowledge, and infact first case to be reported in the setting of carcinoma of cervix.²

In 1990, Russack and Lammers reported six Xanthogranulomatous endometritis cases associated with endometrial carcinoma that had been irradiated with external beam and/or intracavitary implants. The proposed mechanism of development may involve a complex interaction of elements such as obstruction, inflammation and a lipid source as well as generation of free radicals and lipid peroxidation, which are unique to the irradiated tissues.^{2,6} Our case had history of external beam radiation. Two cases of xanthogranulomatous salpingitis have been reported in the literature.²

Xanthogranulomatous cholecystitis and pyelonephritis develop on basis of inflammation, tissue necrosis and obstruction, and stenosis.⁴ Chronic infection leads to tissue necrosis and continuously releases cholesterol and other lipids from the dead cells, these cellular components are phagocytosed by macrophages, leading to xanthomatous process is also a possible explanation of this entity.⁵

The yellowish colour of the cervix nodule is due to accumulation of foamy histiocytes. Because of the presence of foamy histiocytes, malakoplakia should be considered in the differential diagnosis of xanthogranulomatous inflammation. However, both are identical chronic inflammatory diseases and which have the common pathogenetic pathway. In xanthogranulomatous inflammation, the cytoplasmic concentric calcified Michaelis-Gutmann bodies are not seen which can be seen in Malakoplakia.⁵ We did not find a Michaelis-Gutmann body in our case. Immunohistochemistry with CD68 marker is positive in foamy histiocytes.^{4,5} In our case we have not done immunohistochemistry, because the histopathological features were straight forward.

CONCLUSION

To conclude, we found that only one case of xanthogranulomatous cervicitis had been reported in the India and this may be the second case of xanthogranulomatous cervicitis to be reported from India and probably first case in the setting of carcinoma cervix. Such morphological pattern of inflammation can occur secondary to radiation therapy for carcinoma of cervix also.

Funding: No funding sources

Conflict of interest: None declared

Ethical approval: Not required

REFERENCES

1. Rosai J. Rosai and Ackerman's surgical pathology. In: Rosai J, eds. 9th ed. Missouri: Mosby; 1996:1042-1043. 1227, 2142, 1057875.
2. Narayan R, Mishra M, Mohanty R, Sinha T. Xanthogranulomatous cervicitis. Indian J pathol microbial. 2008;51:458-9.
3. Ladefoged C, Lorentzen M. Xanthogranulomatous inflammation of the female genital tract. Histopathology. 1988;13:541-51.
4. Doğan-Ekici AI, Usubütün A, Küçükali T, Ayhan A. Xanthogranulomatous endometritis: a challenging imitator of endometrial carcinoma. Infectious Diseases in Obstetrics and Gynecology. 2007;3. Article ID 34763. <http://dx.doi.org/10.1155/2007/34763>.
5. Karigoudar MH, Kushtagi AV, Karigouda RM, Sirasagi A. Xanthogranulomatous oophoritis- a rare inflammatory lesion. Journal of Krishna institute of medical sciences university. 2013;2(2).
6. Russack V, Lammers RJ. Xanthogranulomatous endometritis: report of six cases and a proposed mechanism of development. Arch Pathol Lab Med. 1990;114:929-32.

Cite this article as: Padmanaban KG, Marimuthu S. A rare case of xanthogranulomatous cervicitis in post radiation radical hysterectomy. Int J Res Med Sci 2016;4:3094-6.