

Original Research Article

Functional outcome of galeazzi fracture dislocation treated by open reduction and internal fixation with dynamic compression plate

Manoj Kumar, Amit Kumar, Sanjeev Gupta, Neeraj Mahajan,
Zubair A. Lone, Maneer Ahmed*

Department of Orthopaedics, Government Medical College, Jammu, Jammu and Kashmir, India

Received: 18 April 2021

Revised: 22 April 2021

Accepted: 23 April 2021

***Correspondence:**

Dr. Maneer Ahmed,

E-mail: drmaneermir@gmail.com

Copyright: © the author(s), publisher and licensee Medip Academy. This is an open-access article distributed under the terms of the Creative Commons Attribution Non-Commercial License, which permits unrestricted non-commercial use, distribution, and reproduction in any medium, provided the original work is properly cited.

ABSTRACT

Background: Galeazzi fracture involves fracture of the distal 1/3rd of radius shaft associated with dislocation of distal radioulnar joint. Open reduction and rigid internal fixation of radius is goal standard treatment. The aim of this study was done to evaluate the functional outcome of Galeazzi fracture dislocation managed by open reduction and internal fixation of radius.

Methods: The study was conducted in department of orthopaedics Government Medical college Jammu from December 2018 to February 2021. 30 patients of Galeazzi fracture dislocation were managed with Open reduction and internal fixation of Radius with plating and were followed up to evaluate the results.

Results: Age of the patients ranged between 23 years to 60 years with a mean range of 42 years. 22 cases were male (73.3%), 8 cases were females (26.6%). In 19 cases injury was in right side and in 11 cases injury was in left side. In most of the cases injury was due to RTA (80%) and in rest of cases injury was due to fall from height (20%).

Conclusions: Anatomic restoration of length of the radius with rigid internal fixation is key to satisfactory results in Galeazzi fracture dislocations and K-wire fixation of distal radio ulnar joint is not necessary if anatomic reduction of the joint is obtained by indirect means such as open reduction and internal fixation of the radius and immobilization.

Keywords: Galeazzi fracture, Distal radio-ulnar joint, Walsh classification, Mayo wrist score

INTRODUCTION

Galeazzi fracture involves fracture of the distal 1/3rd of radius shaft associated with dislocation of distal radioulnar joint. Most often the fracture occurs at the junction of middle 1/3 and distal 1/3 between the insertion of pronator teres and pronator quadratus. Campbell stressed upon the need of open reduction and rigid internal fixation for this fracture and called it as 'the fracture of necessity'.

Early operative intervention should be done because of possible complications with delay in surgery.^{1,2} First it was described by the British surgeon Sir Astley Cooper in 1822 and then it was named after Galeazzi who first reported a

series of 18 cases in 1934 in which he described the mechanism, incidence, and management of this injury.³

Walsh et al classification: (a) type 1 which is characterized by a dorsal displacement of the distal radius (apex volar), and it is caused by axial load applied to the forearm while the forearm is in supination; (b) type 2 which is characterized by volar (posterior) displacement of the distal radius which makes it an apex dorsal.⁴

In present study we studied the outcome of galeazzi fracture dislocation with open reduction and internal fixation of radius.

METHODS

The prospective study was conducted in Government Medical College and Hospital, Jammu from December 2018 to February 2021. 30 patients of galeazzi fracture dislocation were included in this study. All cases were followed up prospectively in the department. Informed consent was taken from all the patients and ethical clearance was taken.

Inclusion criteria

Fracture shaft of radius with an associated dislocation of distal radio-ulnar joint. The shaft is considered to be part of radius between bicipital tuberosity proximally and an area 4-5 cm from the distal articulating surface of radius distally, All the Galeazzi fracture dislocation of either sex above the age of 23 years and less than 60 years will be included.

Exclusion criteria

Galeazzi fracture dislocation <23 years, fracture of distal end of radius, associated with fracture of ulna, associated with dislocation of elbow, open injuries

The causes of injury included road traffic accident (RTA) in 24(80%) patients whereas in 6 (20%) patients it was due to fall from height.

All cases were managed with open reduction and internal fixation with plating by anterior Henry approach. All operations were performed under general anaesthesia and Supraclavicular Block. Tourniquet was used in all cases and was inflated prior to incision. The landmarks were the radial head or lateral to the biceps tendon proximally to the radial styloid distally.

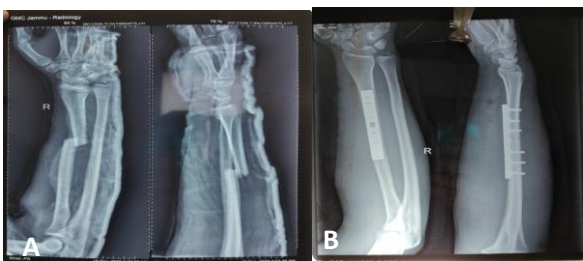

Figure 1: Pre-operative and post-operative radiographs of a 24-year-old-male with galeazzi fracture dislocation.

After rigid anatomical fixation with plating of radius the distal radioulnar joint was assessed intraoperatively and was found reduced and stable hence, K-wire fixation was not needed. A posterior Above elbow slab was applied and sutures were removed after 2 weeks. The slab was removed at 2-4 weeks. After that Physiotherapy was advised. Patients were advised to carry out daily exercises at home like active flexion, extension, pronation, supination without lifting heavy weight. Patients were

advised to report for follow up after 6 weeks. Radiographs were taken for assessment of radiological union (Figure 1). The patients were followed up for a period of 1 year. The statistical tool used were percentage, range and mean.

RESULTS

Age of the patients ranged between 23 years to 60 years with a mean range of 42 years. 22 cases were male (73.3%), 8 cases were females (26.6%). In 19 cases injury was in right side and in 11 cases injury was in left side. Most of the cases injury was due to Road traffic accident 24 (80%), 06 (20%) cases were due fall from height. All cases preoperatively were immobilized with above elbow POP slab. Patients were evaluated for surgery. Volar plating by anterior henry approach was done.in most of the cases rigid internal fixation was achieved by 3.5 mm AO dynamic compression plates. Intra-operatively distal radio ulnar joint was assessed for stability in all cases and was found reduced and stable by indirect means owing to anatomic reduction by rigid plating hence K-wire fixation was not needed for DRUJ. Immobilization was done in above elbow POP slab in full supination for 2-4 weeks in all cases. After that Physiotherapy was initiated for elbow, wrist and finger movements. Patients were followed up at frequent intervals. Using mayo wrist score, 24 cases gave excellent result. 3 cases good, 2 case fair and 1 case gave poor result. Poor results were due to old age, associated co morbidity and loss of distal radio-ulnar joint stability.

Table 1: Mayo Wrist score for functional assessment of wrist.

Pain	Point
No pain	25
Mild pain	20
Moderate	15
Severe	0
Work status	
Regular job	25
Restricted job	20
Able to work but unemployed	15
Unable to work due to pain	0
Range of motion	
>120°	25
100 to 119°	20
90 to 99°	15
60 to 89°	10
30 to 59°	5
0 to 29°	0
Grip strength (% normal)	
90 to 100	25
75 to 89	15
50 to 74	10
25 to 49	5
0 to 24	0

Total point scores: excellent (91 to 100), good (80 to 90), fair (65 to 79), and poor (<64).

Table 2: Functional outcome achieved in present study.

Outcome	Number of patients	Percentage
Excellent	24	80
Good	03	10
Fair	02	6.6
Poor	01	3.3
Total	30	100

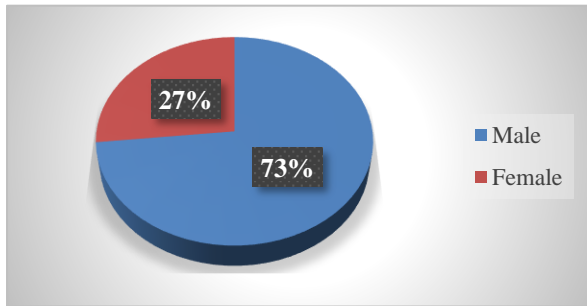


Figure 2: Sex distribution.

DISCUSSION

In our study all cases were managed with open reduction and internal fixation with plating of radius without need for k wire fixation of DRUJ. In a study conducted by Anderson et al found that volar plating is technically easier and result in better soft tissue coverage.⁵ The treatment outcome of galeazzi fracture has drastically improved from a high failure rate of 52% with closed treatment (Houghston) to 70-80% excellent with AO plating.⁶ We had used 3.5 mm dynamic compression plating in all cases. We had excellent results in 25 patients (83.3%). All studies in this subject have cited the poor results are obtained when the injuries are treated by closed methods only.

Regarding post-operative immobilization all cases were immobilized with above elbow POP slab for a period of 2-4 weeks in supination. In a study by reckling et al, immobilization was done in supination and continued for 6-8 weeks. In a study by MOORE TM et al, post-operative immobilization in neutral position or 5-10° of supination for 4 weeks was done.^{7,8} In a study conducted by Abdul Ravoof et al they found excellent result in 75% cases which were managed with open reduction and internal fixation of radius with AO DCP plates.⁹

The authors believe that the sample size in the present study is small.

Limitation

The authors believe that the sample size in the present study is small.

CONCLUSION

Anatomic restoration of length of radius with rigid internal fixation is key to achieve satisfactory results in Galeazzi fracture dislocation. K-wire fixation of distal radio ulnar joint is not necessary if reduction is achieved by indirect means such as open reduction and internal fixation of the radius and immobilization.

Funding: No funding sources

Conflict of interest: None declared

Ethical approval: The study was approved by the Institutional Ethics Committee

REFERENCES

1. Reckling FW, Cordell LD. Unstable fracture-dislocations of the forearm. The Monteggia and Galeazzi lesions. Arch Surg. 1968;96(6):999-1007.
2. Reckling FW, Pelti Sebastin SJ, Chung KC. A historical report on Riccardo Galeazzi and the management of Galeazzi fractures. J Hand Surg Am. 2010;35:1870-7.
3. Giannoulis FS, Sotereanos DG. Galeazzi fractures and dislocations. Hand Clin. 2007;23:153-63.
4. Walsh HP, Laren CA, Owen R. Galeazzi fractures in children. J Bone Joint Surg Br. 1987;69(5):730-3.
5. Anderson LD, Sisk D, Tooms RE, Park WI. Compression-plate fixation in acute diaphyseal fractures of the radius and ulna. J Bone Joint Surg Am. 1975;57(3):287-97.
6. Hughston JC. Fracture of the distal radial shaft; mistakes in management. J Bone Joint Surg Am. 1957;39(2):249-64.
7. Katolik LI, Trumble T. Distal radioulnar joint dysfunction. Journal of the American Society for Surgery of the Hand. 2005;5(1):8-29.
8. Moore TM, Klein JP, Patzakis MJ, Harvey JP. results of compression plating of closed Galeazzi fractures. JBJS. 1985;67:1015-21.
9. Ravoof A, Ravoof A, Deepak CD. Surgical management of galeazzi fracture dislocation. International J Recent Trends in Sci and Techn. 2014;11(2):264-6.

Cite this article as: Kumar M, Kumar A, Gupta S, Mahajan N, Lone ZA, Ahmed M. Functional outcome of galeazzi fracture dislocation treated by open reduction and internal fixation with dynamic compression plate. Int J Res Med Sci 2021;9:1352-4.