

## Original Research Article

# Effect of intravenous dexmedetomidine and small dose fentanyl on shoulder tip pain in gynecological laparoscopic surgeries under spinal anaesthesia

Anjum Naz<sup>1\*</sup>, Hasibul Hasan Shirazee<sup>2</sup>

<sup>1</sup>Department of Anaesthesiology and Intensive Care, North Bengal Medical College and Hospital, Siliguri, West Bengal, India

<sup>2</sup>Department of Obstetrics and Gynaecology, R.G. Kar Medical College, Kolkata, West Bengal, India

**Received:** 05 October 2016

**Accepted:** 12 October 2016

### \*Correspondence:

Dr. Anjum Naz,

E-mail: [dranjumnaz@rediffmail.com](mailto:dranjumnaz@rediffmail.com)

**Copyright:** © the author(s), publisher and licensee Medip Academy. This is an open-access article distributed under the terms of the Creative Commons Attribution Non-Commercial License, which permits unrestricted non-commercial use, distribution, and reproduction in any medium, provided the original work is properly cited.

### ABSTRACT

**Background:** Shoulder tip pain and discomfort due to peritoneal stretching is the major limiting factor of spinal anaesthesia in laparoscopic surgeries. Aim of the study was to evaluate the effect of intravenous dexmedetomidine along with small dose fentanyl in abolishing the shoulder tip pain during gynaecological laparoscopic surgery and to assess its respiratory and hemodynamic effects.

**Methods:** 50 ASA grade I and II, with age 18-50 yrs and weight 45-70 kgs, who were undergoing elective gynecological laparoscopic surgeries with estimated pneumoperitoneum time of one hour or less, were included in the study. Injection dexmedetomidine 1 mcg/kg was infused over a period of ten minutes before spinal anaesthesia with 3.5 ml of injection ropivacaine (0.75%) in lateral position. Injection fentanyl 0.5mcg/kg was given intravenously before intraperitoneal insufflation. Shoulder tip pain, peri-operative heart rate, noninvasive blood pressure, end tidal carbon dioxide, respiratory rate and sedation level using Ramsay sedation score were assessed at frequent intervals.

**Results:** 35 patients were comfortable with no complaints, 11 patients had mild and two patients had moderate shoulder tip pain which was relieved by reducing abdominal pressure or/and an additional dose of fentanyl (25 mcg). One patient had severe pain and had to be converted to general anaesthesia. Ready sedation score was 2 or 3 for all the patients except one who was deeply sedated and had to be intubated. The drug combination used reduced the shoulder tip pain in gynaecological laparoscopic surgeries performed under spinal anaesthesia while maintaining the stable intra-operative hemodynamics.

**Conclusions:** This study has provided the preliminary evidence of feasibility of use of dexmedetomidine along with low dose fentanyl to reduce the discomfort and shoulder tip pain during gynaecological laparoscopic procedures of short duration under spinal anaesthesia in selected patients.

**Keywords:** Dexmedetomidine, Fentanyl, Gynaecological laparoscopic surgery, Shoulder tip pain, Spinal anaesthesia

### INTRODUCTION

Although general anaesthesia is considered as the gold standard for laparoscopic surgeries, regional anaesthesia in the form of subarachnoid block is a safer option in patients with moderate medical problems related to respiratory system where general anaesthesia along with

pneumoperitoneum can be hazardous.<sup>1-3</sup> However the major limiting factor for the use of spinal anaesthesia in laparoscopy is patient discomfort, anxiety and shoulder tip pain.<sup>4</sup> The problem of shoulder tip pain is more severe in gynecological laparoscopies compared to other laparoscopic surgeries because of the mandatory trendelenberg position in the former.

Several techniques have been used to alleviate this problem with varying results.<sup>5-7</sup> Sedation and analgesia in the form of midazolam, opioids and other agents like ketamine and propofol have been used.<sup>8,9</sup> In present experience we have found that the amount of sedation and analgesia needed for delineating the discomfort and shoulder pain in gynecological laparoscopic procedures leads to respiratory depression and hypoventilation.

We conducted this study to observe the feasibility of using intravenous dexmedetomidine along with small dose fentanyl to abolish the shoulder tip pain, thus making the patient more comfortable without causing excessive sedation and respiratory depression. From a pilot study conducted on a small number of cases we found that dexmedetomidine alone is not sufficient to deal with the pain and discomfort during pneumoperitoneum. We hypothesized that addition of small dose of fentanyl will have a synergistic analgesic action with dexmedetomidine without causing respiratory depression and excessive sedation.

## METHODS

After obtaining the approval of Institutional Ethics Committee for the feasibility study; 50 patients undergoing gynecological laparoscopic surgery were included in the study. Written informed consent for the procedure and study was obtained from all patients. Patients with ASA grade I and II, with age 18-50 years and weight 45-70 kgs, who were undergoing elective gynecological laparoscopic surgeries with estimated pneumoperitoneum time of one hour or less (Table 1) were included in this study.

Patients with a history of allergy to the study drugs, pregnant and lactating women and those with a known contraindication of spinal anaesthesia were excluded from the study. In the preoperative visit, it was made clear to the patient that any pain, discomfort or anxiety will be dealt with administration of systemic drug or if needed, conversion to general anaesthesia. Similarly, the surgeons were communicated to ask for general anaesthesia if they felt any technical difficulty out of the anaesthetic procedure.

All the patients were given lorazepam 2 mg on the morning of surgery. Inside the operation room after attachment of the monitoring lines, patients were preloaded with 10 ml/kg of crystalloid and were premedicated with intravenous ondansetron 4 mg and intravenous glycopyrrolate 0.2 mg.

Injection dexmedetomidine 1 mcg/kg was infused over a period of ten minutes and patients were then given spinal anaesthesia with 3.5 ml of injection ropivacaine (0.75%) in L3-L4 or L4-L5 space in lateral position with a 26 gauge quincke needle using a midline approach. After turning the patient supine, level of sensory block was assessed. Before insufflation for pneumoperitoneum,

injection fentanyl 0.5mcg/kg was given intravenously. Insufflation of gas was done at the rate of 1.5 litres/min and the maximum abdominal pressure was kept at 12 mmHg. Supplementary oxygen at 4 liters/min was given with face mask and ET CO<sub>2</sub> monitor was attached.

Intra-operative heart rate (HR), non-invasive mean blood pressure (MBP), end tidal carbon dioxide (ETCO<sub>2</sub>), and respiratory rate were monitored and noted preoperatively, during dexmedetomidine infusion, after completion of infusion i.e. before spinal anaesthesia, after spinal anaesthesia, during creation of pneumoperitoneum, after trendelenberg position, thereafter every 10 minutes, after desufflation and on admission to Post Anaesthesia Care Unit (PACU).

Hypotension (>20% decrease in systolic blood pressure) was treated with intravenous fluid boluses and injection mephentermine 3 mg in incremental doses. Bradycardia (heart rate <50 bpm) was treated with intravenous atropine 0.6 mg. Discomfort and shoulder tip pain were comprehended either by verbal complaint by the patient or by facial and body expression.

The severity of pain was gauged as nil, mild, moderate and severe. Supplemental doses of fentanyl 25 µg were given if the patient required. A conversion to general anaesthesia was made, if the patient was too uncomfortable, too sedated or the surgery got prolonged.

Sedation level using Ready sedation score was assessed at every 15 minutes intraoperatively and every hour in PACU. Time of complete regression of spinal anaesthesia, post-operative nausea and vomiting (PONV), retention of urine or any other side effects were noted in PACU. A diclofenac sodium suppository 100 mg was given at the end of the procedure and oral paracetamol 20 mg/kg was given after 6 hours as prophylactic analgesic when the patients were allowed oral sips of water.

## Statistical analysis

Statistical analysis of perioperative hemodynamic changes was done using paired Student's t test. A p value more than 0.05 was considered insignificant.

## RESULTS

The dermatome level of analgesia at T3-T5 level was achieved satisfactorily in all patients. Out of 50 patients, plan of surgery was changed for one patient after anaesthesia by the surgical team and an open surgery was performed instead of laparoscopy. Two patients needed conversion to general anaesthesia, one for severe pain and the other for excessive sedation and an anticipated prolonged surgery (Table 1). The cardiovascular changes were minimal and anticipated. After dexmedetomidine infusion there was a decrease in heart rate from the base line 79.3±9.51 to 62.1±6.27 which again increased during insufflation of gas.

**Table 1: Patient characteristics and operative information (n= 49).**

Patient characteristics	Operative information
Age (years)	35.5± 12.1
Weight (Kg)	55.47± 9.7
Height (cm)	155.51±8.7
<b>Surgical Procedures</b>	
Diagnostic laparoscopy with dye test	10
Diagnostic laparoscopy and ovarian cyst puncture	9
Laparoscopic ovarian cysectomy	11
Adhesiolysis for chronic PID or endometriosis	13
Laparoscopic tubal recanalisation	6
Duration of spinal anaesthesia (minutes)	261.5±34.8

Data are represented as Mean±Standard Deviation or number of subjects.

There was an increase of MBP baseline 88.3±6.50 mmHg after dexmedetomidine infusion which decreased

considerably after spinal anesthesia to 71.9±5.8 mmHg and got improved after CO<sub>2</sub> insufflation (Table 3, Figure 1). ETCO<sub>2</sub> and respiratory rate increased after insufflation of CO<sub>2</sub> till 15 minutes in a step wise manner and stabilized thereafter without any further increase till decompression of the pneumoperitoneum, when it returned to normal. SpO<sub>2</sub> showed a slight decrease after creation of pneumoperitoneum and trendelenberg position (Table 3).

**Table 2: Incidence and severity of shoulder tip pain in 49 patients.**

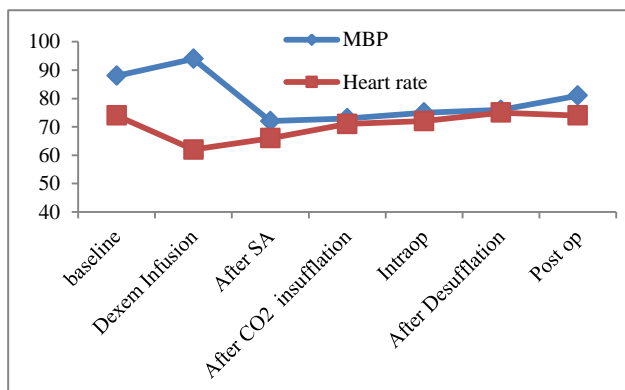
No pain	Mild pain	Moderate pain	Severe pain
35 (71.4%)	11 (22.4%)	2 (4.1%)	1 (2.0%)

35 patients were comfortable and did not complain of any discomfort or shoulder pain. 11 patients had mild, two patients had moderate shoulder tip pain and abdominal discomfort (Table 2).

**Table 3: Perioperative hemodynamic changes.**

Variables	Baseline	After Dexem infusion	After spinal Anaesthesia	After CO <sub>2</sub> insufflation	Intra operative	After desufflation	1 hour Post operative
MBP (mmHg)	88.3±9.53	93.7±9.24	71.9±8.50*	73.05±4.31	75.3±5.67	76.8±8.21	81.01±7.33
Heart rate (bpm)	79.3±9.51	62.1±6.27*	66.5±7.15*	71.4±8.05	72.3±6.53	75.3±7.31	74.6±6.77
ETCO <sub>2</sub> (mmHg)	31.5±1.44	31.8±0.88	30.88±1.38	38.3±2.21*	36.8±2.11*	33.4±1.70	31.6±1.02
Respiratory rate (per minute)	14.1±1.29	13.9±1.11	14.01±1.26	21.9±2.51	20.8±2.61	14.6±1.1	13.8±1.21
Oxygen saturation SpO <sub>2</sub> (%)	98.1±1.20	98.01±1.31	97.9±1.16	97.1±1.13	97.3±0.9	97.8±1.24	98.05±1.29

Data is expressed as Mean±standard deviation. MBP= Mean Blood Pressure, ETCO<sub>2</sub>= End tidal carbon dioxide (n= 47<sup>#</sup>). \*Significantly (p<0.05) different from baseline. #Excluding two patients who needed conversion to general anaesthesia.



**Figure 1: Variation of mean blood pressure (MBP) and heart rate perioperatively.**

A supplemental dose of fentanyl or slight decrease in abdominal pressure or both were sufficient to alleviate the problem in all the 13 patients. One patient had severe discomfort which was not relieved by any of the above methods and had to be converted to general anaesthesia.

Ready sedation score was 2 or 3 for all the patients except one who was deeply sedated and was ultimately intubated and given general anaesthesia as surgery was anticipated to be prolonged. Postoperatively, none of the patients had PONV, analgesia in addition to the routine prophylactic one was demanded by only two patients at night who were given a repeat dose of diclofenac suppository. All the patients resumed oral intake on the day of surgery. One patient had urinary retention and needed catheterization.

## DISCUSSION

General anaesthesia with muscle relaxation and controlled ventilation has been the preferred anesthetic technique for laparoscopic procedures utilizing carbon dioxide (CO<sub>2</sub>) as insufflating gas for pneumoperitoneum.<sup>1</sup> Spinal anaesthesia is usually avoided for some side effects including shoulder pain secondary to diaphragmatic irritation and discomfort besides the suppressive effect on the respiratory mechanical function along with the mechanical effect of pneumoperitoneum. Use of sedation and analgesics to alleviate the shoulder pain and abdominal discomfort due to stretching of peritoneum have a suppressive effect on the compensatory respiratory responses for increased intra-abdominal pressure and increased CO<sub>2</sub> load. Hence general anaesthesia with controlled ventilation is adopted for even minor and diagnostic laparoscopic procedures.

Shoulder pain during laparoscopic procedures is actually a referred pain which occurs due to diaphragmatic irritation during pneumoperitoneum and arises from C5 dermatome. Therefore it is not possible to alleviate it with the spinal analgesic effect alone. There is a clear evidence of decrease in tidal volume and an increase in the end tidal CO<sub>2</sub> and arterial CO<sub>2</sub> after the creation of pneumoperitoneum under spinal anaesthesia; due to mechanical effect of pneumoperitoneum and the absorption of CO<sub>2</sub> from peritoneal surface.<sup>10</sup> In a conscious patient undergoing laparoscopy with pneumoperitoneum, under spinal anaesthesia, the preserved inspiratory diaphragmatic activity maintains ventilation and, the gas exchange within physiological limits.<sup>10,11</sup> Therefore, while administering a systemic drug to alleviate the shoulder pain it has to be kept in mind that the ventilatory response to hypercapnia is well preserved.

In the present study, there was significant increase in ET CO<sub>2</sub> after insufflation with a compensatory increase in respiratory rate which reached 21.9±2.51 breaths per minute. Respiratory depression was unlikely with the analgesic technique used. Dexmedetomidine, an  $\alpha_2$  agonist is frequently used as a short term sedative analgesic in ICU and in preoperative period as premedication, as an anaesthetic adjuvant, and postoperative sedative and analgesic.<sup>12</sup>

Presynaptic activation of  $\alpha_2$  adrenoceptor in locus ceruleus inhibits the release of norepinephrine and results in sedative and hypnotic effects. Locus ceruleus is the site of origin for the descending medullospinal noradrenergic pathway known to be an important modulator of nociceptive neurotransmission. Stimulation of  $\alpha_2$  adrenoceptors in this area terminates the propagation of pain signals leading to analgesia. At the spinal cord, stimulation of  $\alpha_2$  adrenoceptor at the substantia gelatinosa of the dorsal horn leads to inhibition of firing of nociceptive neurons and inhibition

of release of substance P. Also the  $\alpha_2$  adrenoceptors located at the nerve endings have a possible role in the analgesic mechanism of  $\alpha_2$  agonists by preventing norepinephrine release. Thus dexmedetomidine has supraspinal, spinal and peripheral sites of analgesic action.<sup>13</sup>

Combinations of medication that offer synergistic effect allow reduction in required dosage and decrease in dose related side effects. Badvaik *et al* have clearly shown the synergistic analgesic action of dexmedetomidine and fentanyl in their study.<sup>14</sup> They have advocated use of the combination of dexmedetomidine with fentanyl for sedation and analgesia during minimal to mildly painful procedures that require conscious sedation. In the present study, we exploited this synergistic analgesic effect of the two drugs to decrease the shoulder tip pain while maintaining a conscious sedation with a ready sedation score of 2 or 3 without any respiratory depression. Dexmedetomidine itself does not cause any respiratory depression and a small dose of fentanyl used in our study did not cause any serious respiratory depression.

Regarding hemodynamics, the changes were found to be within physiological limits. The initial increase in Mean blood pressure (MBP) is anticipated due to  $\alpha_2$  mediated vasoconstriction. We had given a prophylactic dose of glycopyrrolate to avoid any bradycardia. Though there was a decrease in heart rate from base line in all cases, only one patient had bradycardia which could be reverted with intravenous atropine. Postoperative pain was minimal and most of the patients were pain free. This could be attributed to the analgesic effect of spinal anaesthesia along with the prophylactic use of diclofenac suppository and oral paracetamol.

The present study has demonstrated the efficacy of combination of bolus dose of dexmedetomidine with low dose fentanyl in alleviating the discomfort and shoulder pain during gynecological laparoscopies. However, for analyzing respiratory depression, considering more variables of the respiratory dynamics such as measurement of tidal volume and blood gases would have given a more accurate picture. Another limitation of the study is that the plasma concentration of fentanyl was not measured. As per the literature the range of plasma concentration of fentanyl providing analgesia without respiratory depression is 0.6-2 ng/ml. Thus, measuring the plasma concentration of fentanyl would add to the evidence that the combination does not cause respiratory depression.

## CONCLUSION

This study has provided the preliminary evidence of feasibility of use of dexmedetomidine along with low dose fentanyl to reduce the discomfort and shoulder tip pain during gynaecological laparoscopic procedures of short duration under spinal anaesthesia in selected patients. The drug combination used maintains the intra-

operative hemodynamic stability with minimal side effects. Spinal anaesthesia along with the above mentioned drug combination provides good muscle relaxation and optimum operative field while maintaining the hemodynamic stability and facilitates postoperative analgesia. Further comparative evaluations with other regional or general anaesthetic techniques involving large sample size would be appropriate to establish the significance of this technique in laparoscopic surgeries performed under spinal anaesthesia.

#### ACKNOWLEDGEMENTS

Authors would like to thank Dr. Nishat Hussain Ahmed and Dr. Tabish Hussain for their contribution in analysis and interpretation of the data and revising the article critically for important intellectual content.

*Funding: No funding sources*

*Conflict of interest: None declared*

*Ethical approval: The study was approved by the Institutional Ethics Committee*

#### REFERENCES

1. Chui PT, Gin T, Oh TE. Anesthesia for laparoscopic general surgery. *Anaesth Intensive Care*. 1993;21(2):163-71.
2. Gramatica L Jr, Brascesco OE, Mercado Luna A, Martinessi V, Panebianco G, Labaque F, et al. Laparoscopic cholecystectomy performed under regional anesthesia in patients with chronic obstructive pulmonary disease. *Surg Endosc*. 2002;16: 472-5.
3. Van Zundert AAJ, Stultiens G, Jakimowicz JJ, van den Borne BEEM, van der Ham WGJM, Wild smith JAW. Segmental spinal anaesthesia for cholecystectomy in a patient with severe lung disease. *Br J Anaesth*. 2006;96:464-6.
4. Alexander JJ. Pain after laparoscopy. *Br. J. Anaesth*. 1997;79:369-78.
5. Ghodki PS, Sardesai SP, Thombre ST. Evaluation of the effect of intrathecal clonidine to decrease shoulder tip pain in laparoscopy under spinal anaesthesia. *Indian J Anaesth*. 2010;54(3):231-4
6. Sarli L, Costi R, Sansebastiano G, Trivelli M, Roncoroni L. Prospective randomized trial of low-pressure pneumoperitoneum for reduction of shoulder-tip pain following laparoscopy. *Br J Surg*. 2000;87:1161-5.
7. Cunniffe MG, Mc Anena OJ, Dar MA, Calleary J. A prospective randomised trial of intraoperative bupivacaine irrigation for management of shoulder tip pain following laparoscopy. *Am J Surg*. 1998;176:258-61.
8. Sinha R, Gurwara AK, Gupta SC. Laparoscopic surgery using spinal anesthesia. *JSLs*. 2008;12:133-8.
9. Ali Y, Elmasry MN, Negmi H, Ouffi HA, Fahad B, Rahman SA. The feasibility of spinal anesthesia with sedation for laparoscopic general abdominal procedures in moderate risk patients. *M.E.J. Anesth*. 2008;19(5):1027-39.
10. Pasupati RN, Sivasanmugam T, Ravishankar M. Respiratory changes during spinal anaesthesia for gynaecological laparoscopic surgery. *J Anaesth Clin Pharmacol*. 2010;26(4):475-9.
11. Warner DO, Warner MA, Ritman EC. Human chest wall function during epidural anesthesia. *Anesthesiology*. 1996;85:761-73.
12. Paris A, Tonner PH. Dexmedetomidine in anaesthesia. *Curr Opin Anaesthesiol*. 2005;18:412-8.
13. Gertler R, Brown HC, Mitchell DH. Dexmedetomidine: a novel sedative- analgesic agent. *BUMC Proceedings*. 2001;14:13-21.
14. Badwaik RT, Siddiqui RA, Borkar AS. Synergistic analgesic action of dexmedetomidine and fentanyl in rats. *IJPMS*. 2012;3(2):19-23.

**Cite this article as:** Naz A, Shirazee HH. Effect of intravenous dexmedetomidine and small dose fentanyl on shoulder tip pain in gynecological laparoscopic surgeries under spinal anaesthesia. *Int J Res Med Sci* 2016;4:4688-92.