

Original Research Article

Fundus first laparoscopic cholecystectomy in patients with gall stone disease and the Fitz-Hugh-Curtis syndrome

Alexander F. Ale*, Mercy W. Isichei, Danaan J. Shilong, Solomon D. Peter, Andrew H. Shitta, Michael A. Misauno

Department of Surgery, Jos University Teaching Hospital, Jos, Plateau State, Nigeria

Received: 17 April 2020

Accepted: 13 May 2020

*Correspondence:

Dr. Alexander F. Ale,
E-mail: falexale@yahoo.com

Copyright: © the author(s), publisher and licensee Medip Academy. This is an open-access article distributed under the terms of the Creative Commons Attribution Non-Commercial License, which permits unrestricted non-commercial use, distribution, and reproduction in any medium, provided the original work is properly cited.

ABSTRACT

Background: To present this experience using the fundus-first technique during laparoscopic cholecystectomy for the management of symptomatic gall stone disease with an intra-operative finding of Fitz-Hugh-Curtis syndrome.

Methods: This is a prospective review of patients who had the fundus-first dissection during laparoscopic cholecystectomy. The study was carried out at the Jos University Teaching Hospital (JUTH), and FOMAS hospital, both of which are tertiary hospitals located in Jos. Patients were recruited from January 2017 - January 2019. All patients undergoing laparoscopic cholecystectomy who had an intraoperative diagnosis of Fitz-Hugh-Curtis syndrome, and who had the fundus-first dissection, were included in the study. Patients who had fundus-first dissection for indications other than Fitz-Hugh-Curtis syndrome, were excluded from the study. Demographic and clinical information of patients included age, sex, duration of surgery, complications, and duration of hospital stay. Descriptive statistics were applied.

Results: A total of 76 patients had elective laparoscopic cholecystectomies over the study period. Of that number, 17 (22.4%) patients had an intra- operative diagnosis of Fitz-Hugh-Curtis syndrome, and had the fundus-first dissection. The mean patient age was 46.3 years (SD = 11.7 years). All patients were female. The mean operating time was 70 minutes (SD = 23 minutes). The duration of hospital stay was 24 hours. There was one conversion due to uncontrollable intraoperative bleeding.

Conclusions: This study revealed that the fundus-first dissection is suitable for removing the gall bladder during laparoscopic cholecystectomy in patients with gall stone disease, and an intraoperative finding of Fitz-Hugh-Curtis syndrome.

Keywords: Fundus first, Fitz hugh curtis, Gall stones, Laparoscopic cholecystectomy

INTRODUCTION

Laparoscopic cholecystectomy is regarded as the gold standard procedure for the surgical treatment of gall stone disease.^{1,2} As variable as biliary anatomy is, so are the access and dissection techniques involved in laparoscopic cholecystectomy. French surgeons initially proposed the fundus-first dissection technique. This technique gave way to the Reddick Olsen technique of gall bladder fundic traction to expose Calot's triangle. The Reddick

Olsen technique was published in 1989 as the standard technique for laparoscopic cholecystectomy and is also referred to as the classical or conventional method. In this method, after the creation of the pneumoperitoneum and the insertion of four standard ports, a grasper is applied to the fundus of the gall bladder to retract it cephalad over the visceral margin of the liver towards the dome of the liver.³⁻⁵ This step is essential as it elevates the liver to expose the Calot's triangle for dissection. A right lateral grasper is then used to retract the infundibulum caudal

and laterally. This maneuver straightens the cystic duct and helps protect the common bile duct from inadvertent injury.⁶ Careful dissection is carried out at the Calot's triangle to achieve the critical view of safety. This critical view is achieved when the surgeon can see only two structures (the cystic duct and artery) entering into the gall bladder.⁷⁻⁹ It must be obtained before any structures are clipped or transected. The cystic duct and artery are carefully clipped and transected while electrocautery or harmonic scalpel is used to separate the gall bladder from the liver bed.

In the fundus-first (also known as the dome down) technique, downward and lateral traction is applied to the fundus of the gall bladder while the liver is carefully pushed upward with a liver retractor to expose the gall bladder bed. The gall bladder is then dissected off its bed first and is used to identify and isolate the cystic duct and artery, which are both clipped and transected.

The fundus-first method has been underutilized possibly because, in the early days of laparoscopic cholecystectomy, only rudimentary instruments were available. However, with the advent of modern instruments to achieve liver retraction, some surgeons are proposing its routine use in laparoscopic cholecystectomy.¹⁰ The same indications for performing a fundus-first technique in open cholecystectomy also apply to the laparoscopic fundus-first technique. These indications include dense adhesions in the Calot's triangle, acute cholecystitis, small contracted thick-walled gall bladder, stones in Hartmann's pouch with short cystic duct and the Mirizzi syndrome.^{1,11,12}

The Fitz-Hugh-Curtis syndrome is a perihepatitis that results in violin string adhesions between the liver capsule and the anterior abdominal wall.¹³ It is an intraoperative finding. It usually, but not exclusively occurs in female patients with pelvic inflammatory disease of gonococcal or chlamydial etiologies.¹⁴⁻¹⁷

This syndrome often presents with right upper quadrant pain together with lower abdominal pain and vaginal discharge in women.¹⁸ However, some patients may present with isolated right upper quadrant pain which may mimic other hepatobiliary pathology.^{14,19}

The incidence of this syndrome ranges from 4% to 27% in women with pelvic inflammatory disease.^{20,21}

When Fitz-Hugh-Curtis syndrome is encountered during a laparoscopic cholecystectomy, the essential step of flipping the gall bladder over the dome of the liver to expose the Calot's triangle (i.e. the conventional method) cannot be achieved if the adhesions are not divided. Sometimes, the adhesions are so dense that a considerable amount of time is spent trying to divide them, thereby causing some delay in the procedure, making the fundus-first approach a better alternative, as

the adhesions do not have to be dissected before using the technique.^{22,23}

In this research paper, authors present this experience using the fundus-first laparoscopic cholecystectomy for the management of symptomatic gall bladder disease with an intra-operative finding of Fitz-Hugh-Curtis syndrome. Authors decided to use the fundus-first approach due to the dense and extensive nature of the peri-hepatic adhesions.²⁴

METHODS

This prospective review was carried out at the Jos University Teaching Hospital (JUTH), and FOMAS hospital, both of which are tertiary health care centers located in Jos. Patients were recruited over a two-year period (January 2017 - January 2019).

Inclusion criteria

All patients undergoing laparoscopic cholecystectomy with an intraoperative diagnosis of Fitz-Hugh-Curtis syndrome, and who had the fundus first dissection were included in the study.

Exclusion criteria

Patients undergoing laparoscopic cholecystectomy who had fundus first dissection for indications other than Fitz-Hugh-Curtis syndrome, were excluded from the study.

Patient preparation and surgery

Consecutive patients with symptomatic gall stone disease were booked for laparoscopic cholecystectomy. Patients were prepped and placed under general anesthesia. The peritoneal cavity was accessed and insufflated using the Hasson's trocar. An initial diagnostic laparoscopy was done using a 10mm telescope with a 30° viewing angle which was inserted through an umbilical port, three other ports were placed at the classical sites under direct vision.

Patients who had an intra operative diagnosis of Fitz-Hugh-Curtis syndrome (determined at the initial diagnostic laparoscopy), as well as those who had a difficult Calot's triangle anatomy had the fundus-first dissection. The cholecystectomy specimen was removed from the peritoneal cavity through the umbilical port in a retrieval bag. All port sites were closed with vicryl 0.

Statistical analyses

Data of all the patients were captured and analyzed using the SPSS version 21. Demographic and clinical information of patients included age, sex, duration of surgery, presence of complications, and duration of hospital stay. Descriptive statistics were applied.

RESULTS

Twenty-six patients had the fundus-first laparoscopic cholecystectomy out of 76 elective cholecystectomies performed over the study period. Of those who had the fundus-first approach, 17 were due to the presence of Fitz-Hugh-Curtis syndrome. There was one conversion to open cholecystectomy due to uncontrollable intraoperative bleeding. The mean age was 46.3 years (SD = 11.7 years). All patients were female. The mean operating time was 70 minutes (SD = 23 minutes). The duration of hospital stay was 24 hours.

DISCUSSION

Fundus-first laparoscopic cholecystectomy is not routinely performed by most laparoscopic surgeons and it is usually reserved for difficult cases.^{25,26} In this study, all cases of gall stone disease with Fitz-Hugh-Curtis syndrome were successfully treated with the fundus-first technique with only one conversion from laparoscopic to open cholecystectomy due to uncontrollable intraoperative bleeding. The successful use of the fundus-first dissection in these patients attests to the safety of this procedure and compares well with the results from other authors.^{27,28} In this study, authors encountered a relatively high number of cases of Fitz-Hugh-Curtis syndrome (22.4%). This contrasts the low reporting of the condition in this environment which has a high prevalence of pelvic inflammatory disease.²⁹ This contrast may be explained by the fact that Fitz-Hugh-Curtis syndrome is an intraoperative diagnosis, and the practice of laparoscopic surgery is relatively young in the country, making it an uncommon diagnosis.^{13,29,30}

When Fitz-Hugh-Curtis syndrome is encountered during a laparoscopic cholecystectomy, the essential step of flipping the gall bladder over the dome of the liver to expose the Calot's triangle cannot be achieved if the adhesions are not first divided. Some surgeons prefer to divide the adhesions (i.e. perform an adhesiolysis) first, and still go ahead with the conventional method.³¹

Some patients tend to present with very dense and extensive adhesions (Figure 1), and authors hypothesize that the fundus-first technique may be an alternative to the classical method in such cases. Since it does not require the initial division of adhesions, it may be a way the fundus-first technique avoid the prolonged surgery time that may be associated with adhesiolysis prior to conventional laparoscopic cholecystectomy in the presence of Fitz-Hugh-Curtis syndrome.

In this study, the mean operating time was 70 minutes (SD = 23 minutes), and this is generally within the time that most researchers accomplish this procedure.^{32,33} It is noteworthy, however, that some researchers believe that the fundus first technique is faster than the classical method.³⁴⁻³⁶

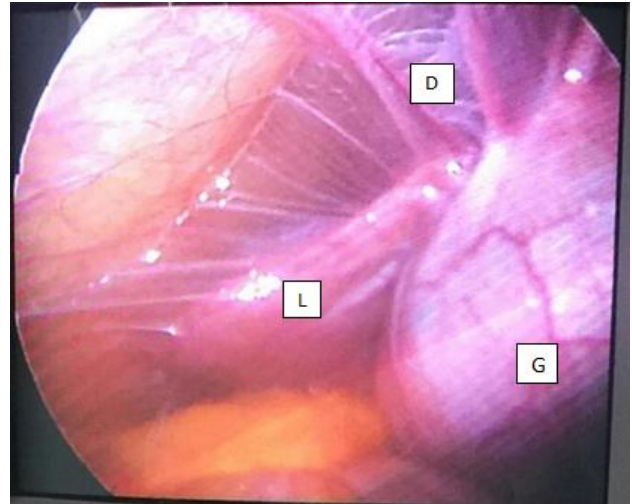


Figure 1: Typical violin string adhesions of th fitz hugh curtis syndrome seen in a patient with chronic calculous cholecystitis undergoing laparoscopic choecystectomy. (D): Dense violin string adhesions, (G): Gall bladder, (L): Liver.

There was one conversion to open cholecystectomy due to uncontrollable intraoperative bleeding. This conversion rate is in tandem with other studies which show a low conversion rate with the fundus-first approach.^{33,36}

Authors also had one case of umbilical port site infection. This is consistent with other studies that reported fundus-first method to be safe with a low incidence of complication and have recommended it as a way of decreasing the rate of bile duct injury especially in cases with unclear biliary anatomy.¹¹ All patients were discharged within 24hrs post operatively.

CONCLUSION

This study revealed that the fundus-first dissection is suitable for removing the gall bladder during laparoscopic cholecystectomy in patients with gall stone disease and an intraoperative finding of Fitz-Hugh-Curtis syndrome.

Funding: No funding sources

Conflict of interest: None declared

Ethical approval: Not Required

REFERENCES

1. Gupta A, Agarwal PN, Kant R, Malik V. Evaluation of fundus-first laparoscopic cholecystectomy. *JLS*. 2004;8(3):255-8.
2. Endo S, Souda S, Nezu R, Yoshikawa Y, Hashimoto J, Mori T, et al. A new method of laparoscopic cholecystectomy using three trocars combined with suture retraction of gallbladder. *J Laparoendosc Adv Surg Tech A*. 2001;11(2):85-8.
3. Cengiz Y, Dalenbäck J, Edlund G, Israelsson LA, Jänes A, Möller M, et al. Improved outcome after

- laparoscopic cholecystectomy with ultrasonic dissection: a randomized multicenter trial. *Surg Endosc.* 2010;24(3):624-30.
4. Cengiz Y, Janes A, Grehn A, Israelsson LA. Randomized trial of traditional dissection with electrocautery versus ultrasonic fundus-first dissection in patients undergoing laparoscopic cholecystectomy. *Br J Surg.* 2005;92(7):810-3.
 5. Elbeshry TM, Ghnam WM. Retrograde (fundus first) Laparoscopic Cholecystectomy in Situs Inversus Totalis. *Sultan Qaboos Univ Med J.* 2012;12(1):113-5.
 6. Hunter JG. Avoidance of bile duct injury during laparoscopic cholecystectomy. *Am J Surg.* 1991;162(1):71-6.
 7. Conrad C, Wakabayashi G, Asbun HJ, Dallemagne B, Demartines N, Diana M, et al. IRCAD recommendation on safe laparoscopic cholecystectomy. *J Hepatobiliary Pancreat Sci.* 2017;24(11):603-15.
 8. van de Graaf FW, Zaimi I, Stassen LPS, Lange JF. Safe laparoscopic cholecystectomy: A systematic review of bile duct injury prevention. *Int J Surg.* 2018;60:164-72.
 9. Manatakis DK, Papageorgiou D, Antonopoulou MI, et al. Ten-year Audit of Safe Bail-Out Alternatives to the Critical View of Safety in Laparoscopic Cholecystectomy. *World J Surg.* 2019 Nov 1;43(11):2728-33.
 10. Bakr AA, Khalil ME, Esmat GE. Acute cholecystitis is an indication for laparoscopic cholecystectomy: a prospective study. *JLSLS.* 1997;1(2):119-23.
 11. Mahmud S, Masaud M, Canna K, Nassar AH. Fundus-first laparoscopic cholecystectomy. *Surg Endosc.* 2002;16(4):581-4.
 12. Kelly MD. Acute mirizzi syndrome. *JLSLS.* 2009;13(1):104-9.
 13. Onoh RC, Mgbafuru CC, Onubuogu SE, Ugwuoke I. Fitz-Hugh-Curtis syndrome: An incidental diagnostic finding in an infertility workup. *Niger J Clin Pract.* 2016;19(6):834-6.
 14. Khine H, Wren SB, Rotenberg O, Goldman DL. Fitz-Hugh-Curtis Syndrome in Adolescent Females: A Diagnostic Dilemma. *Pediatr Emerg Care.* 2019;35(7):e121-3.
 15. Jia W, Fadhlillah F. Fitz-Hugh-Curtis syndrome: a diagnostic challenge. *Clin Case Rep.* 2018;6(7):1396-7.
 16. Jeong TO, Song JS, Oh TH, Lee JB, Jin YH, Yoon JC. Fitz-Hugh-Curtis syndrome in a male patient due to urinary tract infection. *Clin Imaging.* 2015;39(5):917-9.
 17. Takata K, Fukuda H, Umeda K, Yamauchi R, Fukuda S, Kunimoto H, et al. Fitz-Hugh-Curtis syndrome in a man positive for Chlamydia trachomatis. *Clin J Gastroenterol.* 2018;11(4):338-42.
 18. Tanitame K, Tanitame N, Okano Y. Fitz-Hugh-Curtis Syndrome. *Clin Gastroenterol Hepatol.* 2019.
 19. Fare PB, Allio I, Monotti R, Foieni F. Fitz-Hugh-Curtis Syndrome: A Diagnosis to Consider in a Woman with Right Upper Quadrant Abdominal Pain without Gallstones. *Eur J Case Rep Intern Med.* 2018;5(2):000743.
 20. Risser WL, Risser JM, Benjamins LJ, Feldmann JM. Incidence of Fitz-Hugh-Curtis syndrome in adolescents who have pelvic inflammatory disease. *J Pediatr Adolesc Gynecol.* 2007;20(3):179-80.
 21. Sharma JB, Malhotra M, Arora R. Incidental Fitz-Hugh-Curtis syndrome at laparoscopy for benign gynecologic conditions. *Int J Gynaecol Obstet.* 2002;79(3):237-40.
 22. Lirici MM, Califano A. Management of complicated gallstones: results of an alternative approach to difficult cholecystectomies. *Minim Invasive Ther Allied Technol.* 2010;19(5):304-15.
 23. Kelly MD. Laparoscopic retrograde (fundus first) cholecystectomy. *BMC Surg.* 2009;9(1):19.
 24. Owens S, Yeko TR, Bloy R, Maroulis GB. Laparoscopic treatment of painful perihepatic adhesions in Fitz-Hugh-Curtis syndrome. *Obstet Gynecol.* 1991;78(3 Pt 2):542-3.
 25. Hussain A. Difficult laparoscopic cholecystectomy: current evidence and strategies of management. *Surg Laparosc Endosc Percutan Tech.* 2011;21(4):211-7.
 26. Kato K, Kasai S, Matsuda M, Onodera K, Kato J, Imai M, et al. A new technique for laparoscopic cholecystectomy--retrograde laparoscopic cholecystectomy: an analysis of 81 cases. *Endoscopy.* 1996;28(4):356-9.
 27. Ota A, Kano N, Kusanagi H, Yamada S, Garg A. Techniques for difficult cases of laparoscopic cholecystectomy. *J Hepatobiliary Pancreat Surg.* 2003;10(2):172-5.
 28. Rosenberg J, Leinskold T. Dome down laparoscopic cholecystectomy. *Scand J Surg.* 2004;93(1):48-51.
 29. Arowojolu AO, Ilesanmi AO. Clinical and laparoscopy diagnosis of acute pelvic inflammatory disease in Nigeria. *J Obstet Gynaecol.* 1998;18(3):276-7.
 30. Omokanye LO, Balogun OR, Salaudeen AG, Olatinwo AW, Saidu R. Ectopic pregnancy in Ilorin, Nigeria: a four year review. *Niger Postgrad Med J.* 2013;20(4):341-5.
 31. Palade R, Vasile D, Grigoriu M, Voiculescu D. (The Fitz-Hugh-Curtis syndrome in laparoscopic surgery). *Chirurgia (Bucur).* 2002;97(6):557-61.
 32. Turcu F. (Fundus-first laparoscopic cholecystectomy). *Chirurgia (Bucur).* 2008;103(5):569-72.
 33. Tartaglia N, Cianci P, Di Lascia A, Fersini A, Ambrosi A, Neri V. Laparoscopic antegrade cholecystectomy: a standard procedure? *Open Med (Wars).* 2016;11(1):429-32.
 34. Tartaglia N, Petruzzelli F, Vovola F, Fersini A, Ambrosi A. Antegrade cholecystectomy before ligating the elements. A technique that reduces complications. *Ann Ital Chir.* 2019;90:162-4.

35. Neri V, Ambrosi A, Fersini A, Tartaglia N, Valentino TP. Antegrade dissection in laparoscopic cholecystectomy. *JLS*. 2007;11(2):225-8.
36. Tuveri M, Borsezio V, Calo PG, Medas F, Tuveri A, Nicolosi A. Laparoscopic cholecystectomy in the obese: results with the traditional and fundus-first technique. *J Laparoendosc Adv Surg Tech A*. 2009;19(6):735-40.

Cite this article as: Ale AF, Isichei MW, Shilong DJ, Peter SD, Shitta AH, Misauno MA. Fundus first laparoscopic cholecystectomy in patients with gall stone disease and the Fitz-Hugh-Curtis syndrome. *Int J Res Med Sci* 2020;8:2062-6.