

## Case Report

# Interstitial granulomatous dermatitis: a rare case report of dermatological manifestation of rheumatoid arthritis

Jagadeesh Chandrasekaran, Neetu Mariam Alex\*

Department of Medicine, Apollo Main Hospital, Greams road, Chennai, Tamil Nadu, India

**Received:** 08 May 2020

**Accepted:** 01 June 2020

**\*Correspondence:**

Dr. Neetu Mariam Alex,

E-mail: neetumariam@gmail.com

**Copyright:** © the author(s), publisher and licensee Medip Academy. This is an open-access article distributed under the terms of the Creative Commons Attribution Non-Commercial License, which permits unrestricted non-commercial use, distribution, and reproduction in any medium, provided the original work is properly cited.

### ABSTRACT

Interstitial granulomatous dermatitis (IGD), a rare dermatological disorder was first described by Ackerman et al, in the year 1993. It is characterized by a heterogeneous clinical spectrum and a specific histopathological pattern. It has been described in association with a number of auto-immune disorders, drugs, fungal infections, and malignancies. It may manifest as papules, patches, plaques, nodules, annular lesions, or less frequently, as described classically, as indurated linear subcutaneous cords. This case is being reported as interstitial granulomatous dermatitis is rare dermatological manifestation of rheumatoid arthritis and presentation as large ulcerated skin lesions is further extremely rare. In this case report we describe a 67-year-old gentleman with Seropositive Rheumatoid arthritis. He presented to our hospital with complaints of multiple well defined skin lesions with pus discharge over lower limbs, trunk and upper limbs. Biopsies from left upper limb and abdomen showed focal necrobiosis with surrounding granulomatous inflammation with rare perivascular granulomas. He was subsequently diagnosed to have interstitial granulomatous dermatitis based on histopathological examination. Interstitial granulomatous dermatitis has been described to be associated with a number of autoimmune conditions and drugs. It is very important for clinicians to have knowledge about this rare skin condition as it may be heralding presentation of a serious underlying condition like lymphoproliferative disorders or solid organ malignancies. There is no specific treatment and causative disease has to be diagnosed and targeted.

**Keywords:** Interstitial granulomatous dermatitis, Palisaded neutrophilic and granulomatous dermatitis, Rheumatoid arthritis

### INTRODUCTION

Interstitial granulomatous dermatitis (IGD), a rare dermatological disorder was first described by Ackerman et al., in the year 1993.<sup>1</sup> IGD in association with arthritis is known as Ackerman syndrome. It is characterized by a heterogeneous clinical spectrum and a specific histopathological pattern. Classical presentation is linear, indurated sub-cutaneous cords along the lateral aspect of the trunk, known as Rope sign; but it is seen only in a minority of patients.

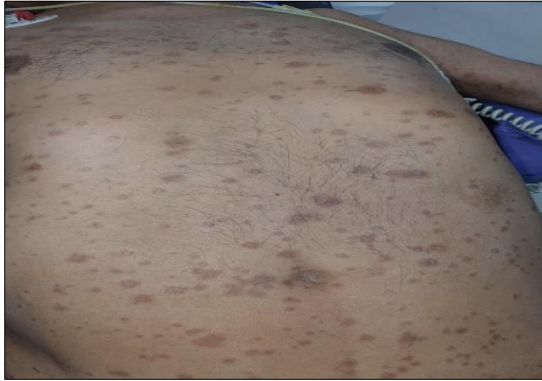
It may also manifest as erythematous and violaceous papules, patches, nodules, plaques, annular lesions, and at

different body sites.<sup>2,3</sup> It is described to be associated with many auto immune disorders, drugs and malignancies. In this case report we describe a 67-year-old gentleman, a known case of Rheumatoid arthritis (RA), strongly seropositive for RA Factor and Anti-CCP.

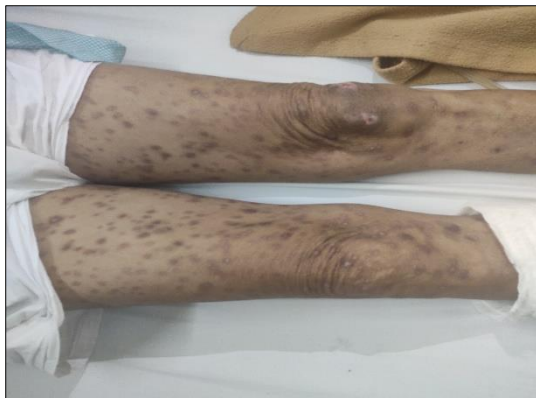He presented to our hospital with complaints of multiple well defined skin lesions with pus discharge over lower limbs, trunk and upper limbs. He was subsequently diagnosed to have interstitial granulomatous dermatitis based on histopathological examination. He was successfully treated with steroids and cyclophosphamide. This case is reported in view of IGD being a very rare dermatological manifestation of Rheumatoid arthritis.

## CASE REPORT

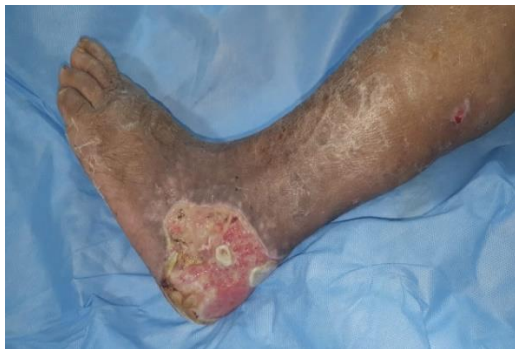A 67-year-old gentleman, a known case of Rheumatoid Arthritis and Usual interstitial pneumonia (UIP) type of interstitial lung disease (ILD), on maintenance dose methotrexate presented with chief complaints of on and off low grade fever for 1 month, progressive discrete well defined hyper pigmented lesions mainly over lower limbs, trunk and also on upper limbs, multiple ulcerative lesions with pus discharge, a non healing ulcer over left foot and swelling of both lower limbs for past 2 months (Figure 1, 2, 3).



**Figure 1: Well-defined hyperpigmented lesions over trunk.**



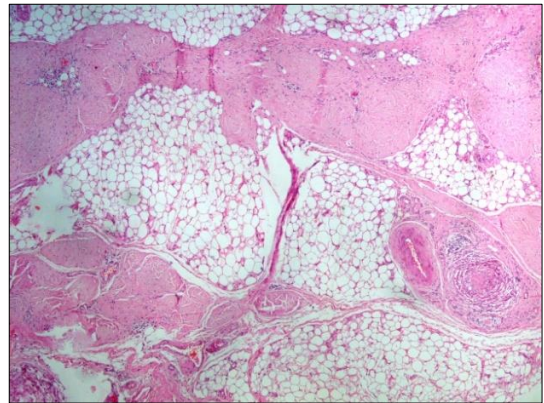
**Figure 2: Well-defined hyperpigmented lesions over both lower limbs.**



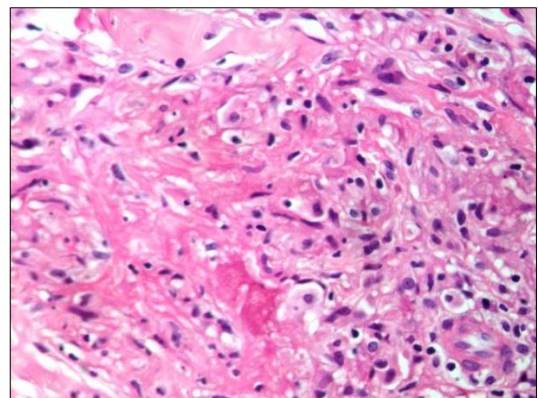
**Figure 3: Non-healing ulcer over left foot.**

He was initially evaluated and managed as chicken pox in other hospital. In view of progressive deterioration of clinical status he was referred to us.

He was conscious, oriented, febrile (Temperature: 101°F) and tachycardic (Heart rate: 104/min) at the time of presentation. Physical examination was notable for bilateral pitting pedal edema; multiple discrete well defined hyperpigmented lesions all over the body with few of them excoriated, forming ulcers with pus discharge. He also had a non healing ulcer with pus discharge over left foot. Baseline blood investigations revealed anemia (Haemoglobin: 8.6gm/dl), significantly elevated ESR (117 mm/hr) and A: G reversal (Albumin: 2.4mg/dl, globulin: 4.1mg/dl, A: G 0.58). Blood and tissue samples were sent for culture and sensitivity testing and he was started on empirical antibiotics. Bilateral lower limb arterial and venous doppler did not show evidence of thrombosis. Wound debridement was done and samples were sent for histopathological examination (HPE). HPE report was inconclusive. XPERT MTB was negative. Tissue culture grew *Pseudomonas aeruginosa*; antibiotics were optimized as per sensitivity report.



**Figure 4: Histopathological examination showing interstitial granuloma.**

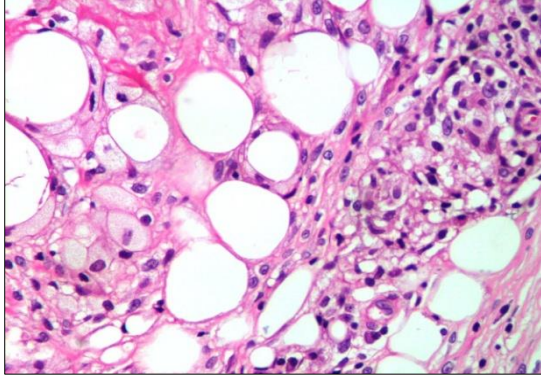


**Figure 5: Histopathological examination showing necrobiosis of collagen fibres.**

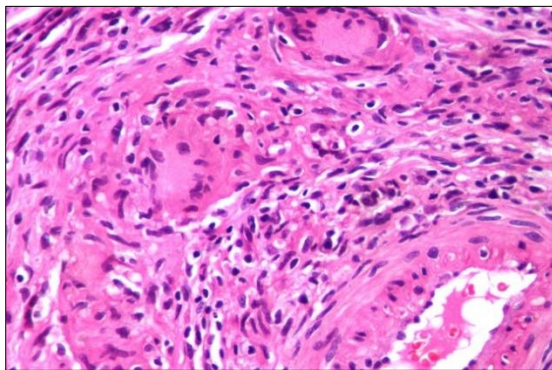
After a detailed discussion with infectious diseases specialist, dermatologist and rheumatologist, repeat



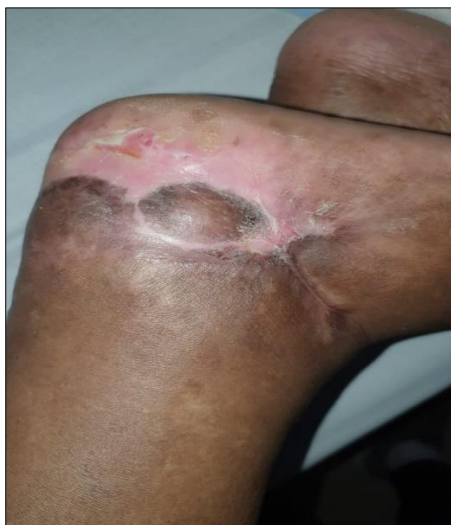biopsy was done from edges of active lesions over left upper limb, foot and abdomen, and samples were sent for HPE. Biopsies from left upper limb and abdomen showed focal necrobiosis with surrounding granulomatous inflammation with rare perivascular granulomas (Figure 4, 5, 6, 7).



**Figure 6: Histopathological examination showing histiocytic infiltration.**



**Figure 7: Histopathological examination showing perivascular granuloma.**



**Figure 8: Completely healed ulcer over left foot post treatment.**

He was diagnosed to have interstitial granulomatous dermatitis, a rare dermatological manifestation of RA. Regular collagen dressings were done during hospital stay and we discharged him on oral steroids and cyclophosphamide. He was reviewed after 3 months as outpatient and skin lesions had resolved completely (Figure 8). AFB Cultures of tissue were eventually negative.

**DISCUSSION**

Interstitial granulomatous dermatitis (IGD) is rare dermatoses, which is more common in middle aged women, as are auto immune disorders. Mean age of onset is around 58years of age.<sup>5</sup> But in our case, he was an elderly male with background of systemic auto immune disorder. Though exact aetiology is not known, it has been described in association with a number of auto immune disorders, drugs, fungal infections, and malignancies (Table 1).<sup>2,4,5</sup>

**Table 1: Conditions described to be associated with IGD.<sup>2,4,5</sup>**

Disorder/Drug	Established associations
Auto immune disorders	Systemic lupus erythematosus, Antiphospholipid syndrome, autoimmune thyroiditis and autoimmune hepatitis, Churg-Strauss syndrome, Behcet’s disease, vitiligo, Rheumatoid arthritis.
Drugs	Angiotensin-converting-enzyme inhibitors, calcium channel blockers, beta blockers, diuretics, hypolipidemic agents, anticonvulsants, antihistamines and TNF-alpha blockers (etanercept, infliximab, and adalimumab), antidepressants, Trastuzumab, ganciclovir
Infections	Pulmonary paracoccidioidomycosis
Malignancy	Promyelocytic leukemia, bronchial and esophageal squamous cell carcinomas
Others	Pulmonary silicosis, chronic uveitis

Its exact pathophysiology is unclear, but its association with many autoimmune diseases supports that deposition of immune complexes in dermal vessels leading to activation of complements and neutrophils which results in necrobiosis of dermal collagen and subsequent granulomatous histological pattern. But when it is associated with drugs, HPE pattern is characterised by vacuolar degenerative changes, exocytosis of lymphocytes and absence of neutrophils.

In this case, presence of focal areas of necrobiosis, surrounding granulomatous inflammation with rare perivascular granulomas, and absence of vacuolar

degenerative changes makes it more likely to be IGD secondary to RA, given the RA background. Clinically it may manifest as papules, patches, plaques, nodules, annular lesions, or less frequently as described classically indurated linear subcutaneous cords. But ulcerative skin lesions, as described in our patient are very rare. Mostly these are asymptomatic, though they may be pruritic or painful occasionally. Arthritis may occur before, during or after the onset of skin lesions. It is usually symmetric, non-erosive and non-deforming, affecting mainly the joints of the upper limbs.<sup>3</sup>

Diagnosis is established by biopsy of an active lesion and histopathological examination which may show characteristic features of IGD like infiltration of reticular

dermis by histiocytes in palisading arrangement and areas of collagen degeneration, and variable number of eosinophils and neutrophils. CD-68 positive histiocytic interstitial infiltration seen on immunohistochemistry and absence of significant mucin deposition on alcian blue staining in areas of granulomatous inflammation will help in further confirmation of the diagnosis. Close differentials to IGD include Palisaded Neutrophilic and Granulomatous Dermatitis (PNGD), Granuloma annulare (GA); others are rheumatoid nodules, rheumatoid vasculitis, Lichen planus, erythema multiforme, erythema elevatum diutinum, erythema chronicum migrans, early inflammatory stage of morphea and interstitial granulomatous drug eruption.<sup>2,5</sup> Table 2 describes the differentiating features between IGD, PNGD, and GA.<sup>2,6</sup>

**Table 2: Differentiating HPE features between IGD, PNGD and GA.**

Feature	Interstitial granulomatous dermatitis (IGD)	Palisading neutrophilic granulomatous dermatitis (PNGD)	Granuloma annulare (GA)
Layers of dermis affected	Middle and deeper layers of dermis	All the layers of dermis	Patchy and superficial
Type of infiltrate	Histiocytic	Neutrophilic	lymphohistiocytic
Vasculitis	Not present	Leukocytoclastic	Not present
Palisades	Smaller “rosettes” of palisading histiocytes	palisades of histiocytes, neutrophils, and nuclear debris	Large/absent
Mucin	Absent	Absent	Abundant

There is no specific therapy for interstitial granulomatous dermatitis. In case if it is drug induced, withholding the offending drug may result in resolution of the skin lesions. Though moderately effective potent topical steroids are the first line of drugs used in these patients. Some use narrow band ultra-violet B phototherapy along with topical steroids. Systemic steroids, cyclosporine, cyclophosphamide, methotrexate, hydroxychloroquine, dapsone, and Anti TNF  $\alpha$  agents like ustekinumab, infliximab, tocilizumab and etanercept have been used by different authors, though there have been some case reports of Anti TNF  $\alpha$  agents being implicated in causation of IGD also. It has an unpredictable outcome, and is characterized by periods of flares and remissions. In our case we managed him with systemic steroids and cyclophosphamide and he responded well.

## CONCLUSION

Interstitial granulomatous dermatitis is rare dermatoses of unknown aetiology. It has been described to be associated with a number of autoimmune conditions and drugs. It is very important for clinicians to have knowledge about this rare skin condition as it may be heralding presentation of a serious underlying condition like lymphoproliferative disorders or solid organ malignancies. There is no specific treatment and causative disease has to be diagnosed and targeted. It may

resolve spontaneously with control of primary disease. The disease course is characterized by periods of flares and remissions.

*Funding: No funding sources*

*Conflict of interest: None declared*

*Ethical approval: Not required*

## REFERENCES

- Ackerman A. Clues to Diagnosis in Dermatopathology. Chicago IL: ASCP Press; 1993:309-312.
- Veronez IS, Dantas FL, Valente NY, Kakizaki P, Yasuda TH, Cunha TA. Interstitial granulomatous dermatitis: rare cutaneous manifestation of rheumatoid arthritis. An Bras Dermatol. 2015;90(3):391-3.
- Antunes J, Pacheco D, Travassos AR, Soares-Almeida LM, Filipe P, Sacramento-Marques M. Autoimmune thyroiditis presenting as interstitial granulomatous dermatitis. An Bras Dermatol. 2012;87(5):748-51.
- Ahmed ZS, Sabaa Joad MS, Bandagi SS. Interstitial granulomatous dermatitis successfully treated with etanercept. Am J Case Reports. 2014;15:94.
- Błażewicz I, Szczerkowska-Dobosz A, Pęksa R, Stawczyk-Macieja M, Barańska-Rybak W, Nowicki

- R. Interstitial granulomatous dermatitis: a characteristic histological pattern with variable clinical manifestations. *Adv Dermatol Allergol.* 2015 Dec;32(6):475.
6. Rabasco AG, Martinez AE, Ninet VZ, Sanchez JL, Miquel VA. Interstitial Granulomatous Dermatitis in a Patient with Lupus Erythematosus. *Am J Dermatopathol.* 2011 Dec;33(8):871-2.

**Cite this article as:** Chandrasekaran J, Alex NM. Interstitial granulomatous dermatitis: a rare case report of dermatological manifestation of rheumatoid arthritis. *Int J Res Med Sci* 2020;8:2688-92.