

## Case Report

# Laparoscopic drainage of sub phrenic abscess

**Ketan Vagholkar\*, Amish Pawanarkar, Balvinder Yadav, Aditya Deshpande, Suvarna Vagholkar**

Department of Surgery, D.Y. Patil University School of Medicine, Navi Mumbai, India

**Received:** 18 August 2016

**Accepted:** 22 August 2016

**\*Correspondence:**

Dr. Ketan Vagholkar,

E-mail: kvagholkar@yahoo.com

**Copyright:** © the author(s), publisher and licensee Medip Academy. This is an open-access article distributed under the terms of the Creative Commons Attribution Non-Commercial License, which permits unrestricted non-commercial use, distribution, and reproduction in any medium, provided the original work is properly cited.

### ABSTRACT

Sub phrenic collections are a common sequel to hepatobiliary surgery. Prompt diagnosis and treatment are necessary to reduce the morbidity and mortality to a bare minimum. Contrast enhanced CT (CECT) scan is the best imaging modality to identify the location and approximate size of the collection. Laparoscopic drainage is the best option for treating sub phrenic abscesses. A case of a sub phrenic abscess drained laparoscopically is presented to highlight the efficacy of this approach.

**Keywords:** Sub phrenic abscess, Dropped gall stones, Laparoscopic treatment

### INTRODUCTION

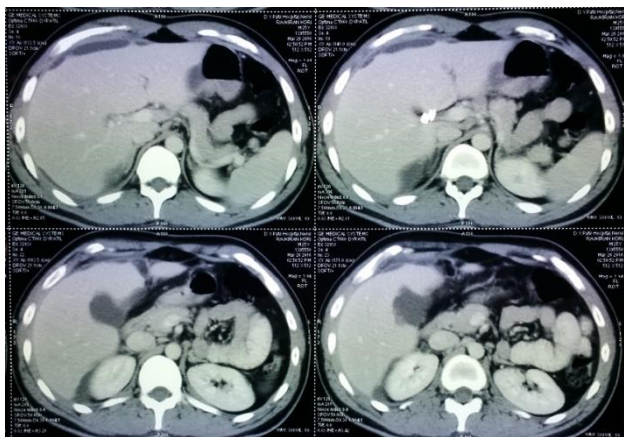
Laparoscopic cholecystectomy is now the gold standard for the removal of the gall bladder. However post-operative complications are commonly seen especially in those patients wherein the dissection has been difficult due to severe adhesions, oozing from the gall bladder bed and occasionally a bile leak from the gall bladder bed. Dropped gall stones during laparoscopic cholecystectomy is an addition to the list of etiological factors. These sequelae eventually lead to collections in the peri-hepatic area which invariably get infected giving rise to septic complications.<sup>1</sup> Majority of surgeons prefer an open approach to these complications. However a laparoscopic approach is extremely effective in tackling such complications. A case of a sub-phrenic collection following a laparoscopic cholecystectomy dealt with laparoscopically is presented to highlight the surgical efficacy of laparoscopy in a salvage role as well.

### CASE REPORT

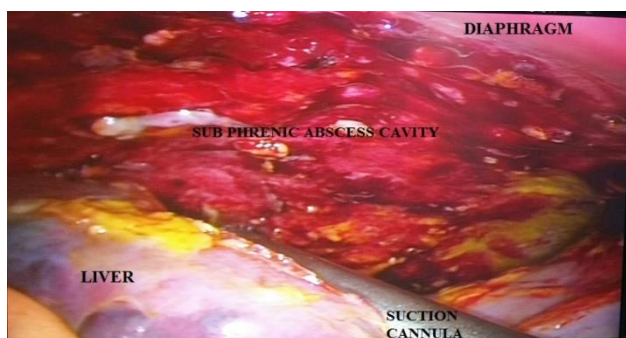
A 24 year old male presented with severe excruciating pain in the right hypochondrium extending to the right

hemi thorax posteriorly. Patient had undergone laparoscopic cholecystectomy one week back which was uneventful.<sup>2</sup> Patient was passing flatus and stools normally with no other symptoms. However, on the 10<sup>th</sup> day after surgery, patient started complaining of severe pain in the right hypochondrium extending to the posterolateral aspect of the right hemi thorax. There was no history of fever, jaundice, vomiting or anorexia. Physical examination revealed normal vital parameters. Per abdomen examination did not reveal any abnormal signs. Hematologic investigations revealed raised WBC counts of 19,000 with neutrophilic leucocytosis. Liver function tests were normal. Renal parameters were normal. A CECT was performed which revealed an extensive peri-hepatic collection extending from right sub-diaphragmatic space to right sub-hepatic region. (Figure 1) There was no evidence of any radio opacity due to a possible dropped gall stone. The common bile duct and the adjacent part of small intestine and colon were also normal. Patient was started on antibiotic combination comprising of cephalosporin, aminoglycosides and metronidazole. The WBC counts dropped from 19,000 to 9,000 after 5 days of antibiotics. However, patient still complained of pain though the severity and intensity had reduced. In view of persistence

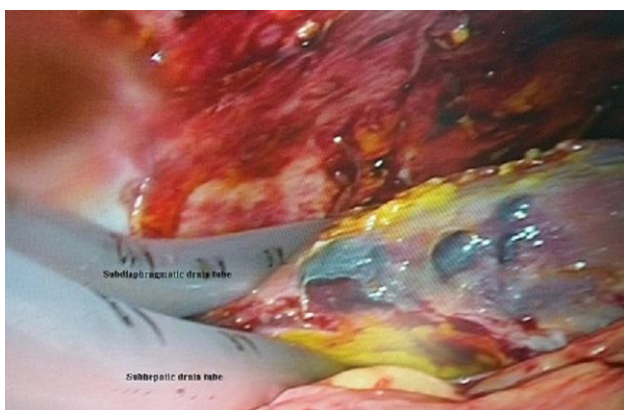
of symptoms and raised WBC counts, a decision to drain the collection laparoscopically was made. A 10mm sub-umbilical port was used to introduce the scope and a 10mm epigastric port for the introduction of dissecting instruments and suction catheter. The sub-diaphragmatic abscess cavity was opened and drained.



**Figure 1: CECT showing a sub phrenic as well as sub hepatic collection. Clips are seen in place. There is no evidence of any dropped gall stone.**



**Figure 2: Sub phrenic abscess cavity laid open.**



**Figure 3: Drains placed in the sub phrenic and sub hepatic spaces.**

(Figure 2) About 1L of purulent fluid was aspirated from the right sub-diaphragmatic space whereas around 250ml

of purulent fluid was aspirated from sub-hepatic space. A saline lavage was given to ensure complete evacuation of the infected fluid and debris.

Two 28F drains were introduced through separate openings made in right lumbar region under direct vision. One of the drains was placed in the right sub-diaphragmatic space and the other in the sub-hepatic space (Figure 3). Post-operative recovery was uneventful. Drains were removed on the 6<sup>th</sup> post-operative day with complete resolution of the symptoms with normalcy of bowel habits and normal WBC counts.

## DISCUSSION

Development of respiratory and abdominal symptoms after surgery should raise the suspicion of a peri-hepatic collection in patients who have undergone biliary tract surgery. Right sub-hepatic region is the commonest site for accumulation of post-operative collections.<sup>1</sup> If the volume of accumulated fluid is extensive, it eventually extends into the sub-diaphragmatic space. Extensive adhesions develop between the liver and the under surface of the diaphragm. The cavity eventually gets walled off from the rest of the peritoneal cavity.<sup>2,4</sup> This also exerts an effect on the respiratory excursions of the right hemi-diaphragm which cause complications of the lower lobe of lung usually accompanied with a sympathetic pleural effusion. Sepsis can make the situation worst as the patient can develop frank septicaemia. A contrast enhanced CT scan of the abdomen is the best investigation to identify the exact location, size and the presence of any dropped gall stones especially in cases following laparoscopic cholecystectomy.<sup>2,4</sup> Hence timely diagnosis is of utmost importance. Prompt surgical intervention is the mainstay of treatment. A pigtail catheter can be placed in the abscess cavity under radiologic guidance. However, the failure rate of this method of drainage is extremely high as the contents of the abscess cavity are usually thick and contain particulate debris. Open surgical intervention is an excellent approach to deal with in this situation. However, morbidity associated with open drainage is quite high. Laparoscopic approach is undoubtedly the best approach for dealing with such a situation.<sup>5,6</sup> The same port sites, namely sub-umbilical and epigastric can be used for intervention under direct vision. Loculated abscess cavities can be broken and accessed. This can be followed by irrigation of abscess cavity with an antibiotic containing solution. Dropped gall stones if diagnosed by imaging should be removed as far as possible. Placement of large-tube drains can be done under direct vision. A 28F drainage tube is optimal to drain the abscess cavity. The advantage of large bore tubes is that they do not get blocked by particulate debris. In rare cases where the septic process does not settle down, the large bore tube can be converted into a sump drain which ensures complete clearance of all the infected material. The drains are removed usually after a period ranging from 2-7 days depending upon the response to the treatment.

## CONCLUSION

Sub-phrenic and sub-hepatic collections are commonly encountered after laparoscopic cholecystectomy especially in difficult cases. Contrast enhanced CT scan of the abdomen is the investigation of choice to diagnose and quantify the collection. A dropped gall stone needs to be looked for. A walled off sub-phrenic abscess can be best be dealt with by laparoscopic approach.

## ACKNOWLEDGEMENTS

Author would like to thank the Dean of D.Y. Patil University School of Medicine for allowing us to publish this case report. They would also like to thank Parth K. Vagholkar for his help in typesetting the manuscript.

*Funding: No funding sources*

*Conflict of interest: None declared*

*Ethical approval: Not required*

## REFERENCES

1. Sluis VRF. Subphrenic abscess. Surg Gynecol Obstet. 1984;158(5):427-30.
2. Nayak L, Menias CO, gayer G. Dropped gall stones: spectrum of imaging findings, complications and diagnostic pitfalls. Br J Radiol. 2013;86(1028):20120588.
3. Lugt VJC, Graaf PW, Dallinga RJ, Stassen L. Abscess formation due to lost stones during laparoscopic cholecystectomy. Ned Tijdschr Geneesk. 2005;149(48):2683-6.
4. Vagholkar K, Pawanarkar A, Vagholkar S. Dropped gall stones: an entity in evolution. Int Surg J. 2016;3:1048-50.
5. Szijarto A, Levay B, Kupcsulik P. Unusual consequences of incomplete laparoscopic cholecystectomy. Eur J Gastroenterol Hepatol. 2014;26(3): 357-60.
6. Lam SC, Kwok SP, Leong HT. Laparoscopic intracavitary drainage of sub phrenic abscess. J Laparendosc Adv Surg Tech A. 1998;8(1):57-60.

**Cite this article as:** Vagholkar K, Pawanarkar A, Yadav B, Deshpande A, Vagholkar S. Laparoscopic drainage of sub phrenic abscess. Int J Res Med Sci 2016;4:4192-4.