

Acute toxicity of the aqueous-methanolic *Moringa oleifera* (Lam) leaf extract on female Wistar albino rats

Mitchel O. Okumu^{1*}, James M. Mbaria¹, Laetitia W. Kanja¹, Daniel W. Gakuya², Stephen G. Kiama³, Francis O. Ochola⁴, Paul O. Okumu⁵

¹Department of Public Health Pharmacology and Toxicology, Faculty of Veterinary Medicine, University of Nairobi, Nairobi, Kenya,

²Department of Clinical Studies, Faculty of Veterinary Medicine, University of Nairobi, Nairobi, Kenya

³Department of Veterinary Anatomy and Physiology, Faculty of Veterinary Medicine, University of Nairobi, Nairobi, Kenya

⁴Department of Pharmacology and Toxicology, Faculty of Medicine, Moi University, Nairobi, Kenya

⁵Department of Veterinary Pathology, Microbiology and Parasitology, Faculty of Veterinary Medicine, University of Nairobi, Nairobi, Kenya

Received: 11 July 2016

Revised: 15 August 2016

Accepted: 01 September 2016

***Correspondence to:**

Dr. Mitchel Otieno Okumu,
Email: mytchan88@gmail.com

Copyright: © the author(s), publisher and licensee Medip Academy. This is an open-access article distributed under the terms of the Creative Commons Attribution Non-Commercial License, which permits unrestricted non-commercial use, distribution, and reproduction in any medium, provided the original work is properly cited.

ABSTRACT

Background: Herbal preparations are widely assumed to be safe on oral administration and therefore the documentation of the toxic potential of some herbal concoctions used as medicine and nutrients is limited. *Moringa oleifera* (MO) is a plant that is gaining tremendous popularity in rural communities in Kenya as a means of offsetting nutritional and medicinal needs. However, very little is known about the safety of the plant on oral administration. Thus, the aim of the current study was to assess the biochemical and histological changes in the liver following the administration of an aqueous-methanolic (AQ-ME) MO leaf extract in female Wistar albino rats.

Methods: Acute oral toxicity study on the AQ-ME MO leaf extract was conducted by the use of the limit test dose of the up and down procedure (OECD guideline number 425) with slight modifications. Briefly, ten (10) healthy, nulliparous, non-pregnant female Wistar strain albino rats aged 8-12 weeks and weighing 180±20 grams were used for the study. These animals were randomly selected into two groups; control and treatment group each having five (5) animals. They were then labelled to enable identification and control group animals were orally administered with physiological buffer saline once daily over a 48-hour period. The five (5) rats in the treatment group were dosed orally one at a time and once daily with a 2000 mg/kg dose of the AQ-ME MO leaf extract to determine the median lethal dose over a 48 hour period. Blood was then collected and used to prepare serum for biochemical analysis of aspartate amino transferase (AST), alanine amino transferase (ALT) and total bilirubin (TB) which are important biomarkers of liver dysfunction. Biochemical assays of these enzymes were performed using the method of the International Federation of Clinical Chemists (IFCC). Death was used as an endpoint, livers harvested and used to prepare transverse sections for histopathological examination. These sections were stained using the haematoxylin and eosin (H&E) method and observed for pathological changes using an optical microscope.

Results: A 2000 mg/kg oral dose of AQ-ME MO leaf extract caused a significant ($p<0.05$) increase in the mean levels of AST but a non-significant ($p>0.05$) increase in the mean levels of total bilirubin in the treatment group relative to the control group. On the other hand, the extract caused a non-significant ($p>0.05$) decrease in the mean levels of ALT in the treatment group relative to the control. The post mortem analysis of the hepatic index (liver to body weight ratio) revealed that there was a non-significant increase ($p>0.05$) in the hepatic index of the treatment group relative to the control. However, the transverse liver sections of treatment group animals showed mild distortions in the architecture of liver cells.

Conclusions: Based on these results, the LD₅₀ of the AQ-ME MO leaf extract was found to be >2000 mg/kg in female wistar albino rats.

Keywords: *Moringa oleifera*, Aqueous-methanol, Wistar rats, OECD 425, Biochemical assays, Liver

INTRODUCTION

Plant resources have for a good long time sustained both human and animal life.¹ Thus, in as much as there has been an evolution in modern medicine, herbal remedies are still popular as a means of promoting healthy outcomes and mitigating disease conditions. However, there is low interest in the toxic manifestations brought about by natural products due to the unfounded belief that drugs obtained from nature are devoid of any toxic ramifications.² *Moringa oleifera* is a plant that originates in Asia but is nowadays cultivated extensively in various parts of the world. Thus, the plant goes by many names; benzolive tree, morunga, drumstick tree, nebeday among others.³ Traditional folklore, oral history and native *materia medica* have associated *Moringa oleifera* with a range of medicinal, nutritional and miscellaneous applications.⁴ Medicinally, the antioxidant, wound healing, hypotensive, and diuretic effects of this plant have been reported.⁵⁻⁷ Nutritionally, the plant has been reported to be rich in calcium which boosts milk production in lactating mothers.⁸ Water clarification has been reported as a miscellaneous use.⁹ However, before fully embracing this plant, there is an overwhelming need to not only scientifically assess these claims but to also investigate the safety of this plant on oral administration. The rat animal model is one of the most widely used methods of evaluating acute oral toxicity effects of various substances. However, due to animal welfare reasons, methodologies using minimum number of animals are now being adopted.¹⁰ These methods are simple, reproducible and are able to classify test substances in a similar manner to other methodologies of testing acute toxicity. The aim of the present investigation was to evaluate the potential of leaves of *Moringa oleifera* to cause acute oral toxicity in female wistar strain albino rats by using biochemical and histopathologic biomarkers of liver injury.

METHODS

Collection and authentication of plant material

Fresh aerial plant material of *Moringa oleifera* was collected from the University of Nairobi Kibwezi farm in Makueni County. The leaves were manually separated from the plant and soaked in 1% w/v sodium chloride (NaCl) for 5 minutes to remove microbes. Further washing was done with aqueous-ethanol and later the leaves were rinsed using distilled water. They were then exposed to ambient air to allow surface moisture to dry. The botanical identity was authenticated at the National Museum Herbarium, Nairobi Kenya and a voucher specimen was submitted for future reference.

Preparation of plant material

The leaves were thinly spread on a mesh tied on racks in a well-ventilated, insect, rodent and dust free room. They were allowed to dry in the shade for 10 days. The dried

leaves were reduced to powder using an electric mill at the Department of Public Health, Pharmacology and Toxicology of the University of Nairobi.

Preparation of the extract from the plant material

In preparing the extract, the method of Anwar et al was adopted with slight modifications.¹¹ One hundred grams of dried leaf powder of *Moringa oleifera* was accurately weighed on an analytical balance (Mettler PM 4600) and poured into a one liter conical flask wrapped in aluminium foil. Eight hundred ml of a methanol-water co-solvent system in the ratio 80:20 v/v was then gradually added to the powder with gentle agitation until slurry of uniform consistency was formed. The phytochemicals present in the leaf powder were then extracted by stirring technique using a magnetic bar and stirrer (Heidolph, Germany). The stirrer was set to operate at 200 revolutions per minute for 48 hours and this process was repeated for another batch of 100 grams of leaf powder. The slurry was then centrifuged (Heraeus technik centrifuge, Germany) at 3000 revolutions per minute (RPM) for 5 minutes and the supernatant collected and subsequently transferred to a rotary evaporator (Büchi-technik AG, Switzerland) set at 45°C to remove excess solvent and concentrate the extract. Further solvent removal and concentration of the extract was done in a sand bath for 24 hours. The dark brown semi-solid product was then stored in light resistant bottles and later refrigerated awaiting further work.

Animal model

Ten healthy female wistar strain albino rats aged between 8 and 12 weeks and weighing 180±20 grams were used for the study. The animals used were nulliparous and non-pregnant. They were obtained from the animal house of the Department of Public Health, Pharmacology and Toxicology of the University of Nairobi. Before commencement of the study, ethical approval was obtained from the Faculty of Veterinary Medicine Biosafety, Animal Care and Use Committee (BACUC) of the University of Nairobi. Reference BACUC/J56/76385/2014 issued on 20-01-2016.

Housing and feeding conditions

Rat cages measuring 35 (L) × 25 (W) × 18 (H) were used to house the animals. The cages were lined with wood shavings which served as beddings for the animals. The temperature in the animal house was maintained at 25±3°C and relative humidity at 56±4%. Rat pellets from a commercial feed supplier (Unga feeds) were used to feed the animals. Water was provided *ad libitum* and a 12-hour light and dark cycle was maintained.

Experimental design for acute oral toxicity study

The animals were randomly assigned to two groups of 5 rats each. They were individually weighed and marked

to enable identification. They were then fasted overnight before commencement of the study. Group 1 served as the control and animals in this group were orally administered with 2 ml of physiological buffer saline once daily. Group 2 served as the treatment group and a test dose (2000 mg/kg) of AQ-ME MO was selected based on the limit test dose of the up and down procedure for determining LD₅₀.¹² Five female rats were orally dosed with the extract one at a time over a 48-hour period as follows; animal 1 was orally dosed with 2000 mg/kg of the extract using physiological buffer saline as vehicle. The survival of this animal dictated the sequential administration of the same dose to 4 other animals. Physical changes in the mucous membranes, appearance of the fur and skin were monitored over a 48-hours period as were clinical signs of the rate of respiration, perspiration, incidence of urinary incontinence, blood pressure changes and heart rate. Moreover, central nervous system effects such as locomotor activity, sensitivity to sound, drowsiness, tremors, convulsions were also used as indices for assessing the acute oral toxic effect of the *Moringa oleifera* leaf extract. The guidance document on humane endpoints was used to limit the overall suffering of the animals.¹³

Handling of animals and biochemical analysis

Laboratory established protocols were followed throughout the study.¹³ Latex hand gloves and protective masks were used at all times. In addition, anti-tetanus and anti-rabies vaccines were made available and stored under refrigeration. Blood was collected from each animal 48 hours after extract administration via the lateral vein of the tail using a 2 ml hypodermic syringe and needle when the animal was restrained. An aliquot (1.0 ml) of the collected blood was placed in plain tubes for biochemical analysis. This blood was left to stand for 30-45 minutes and thereafter centrifuged at 3000 revolutions per minute for 10 minutes to extract serum which was stored at -20°C and used within 12 hours for biochemical assays. Aspartate amino transferase (AST), alanine amino transferase (ALT) and total bilirubin (TB) were assayed for each animal using commercial kits according to the manufacturer's protocols.¹⁴ Thereafter the animals were humanely euthanized using intravenous sodium pentobarbital injection (150 mg/kg bwt) and death was confirmed by using the following indicators; lack of heartbeat, lack of respiration, lack of corneal reflex, lack of response to pinch and greying of the mucous membranes. Livers were harvested and stored in 10% formalin to facilitate histopathological work.

Disposal of rodent carcasses

After confirmation of death, the carcasses were placed in special non-polyvinylchloride (non-PVC), sealable, transparent plastic bags. They were then incinerated.

Gross pathology of the rat livers

For liver histopathological analysis, mid-sections of the left lobes of the liver were collected for histopathology. The rat liver tissue specimens were fixed in 10% formalin. Once fixed, the tissues were processed and embedded in paraffin wax. The tissue blocks were sectioned at 5 microns (5μ) using a microtome. The sections were then de-paraffinized, hydrated, stained using haematoxylin and eosin (H&E) and observed under the light microscope.

Statistical analysis

Results were presented as mean±standard error of the mean and data analysed using GenStat Discovery 4th edition statistical software. One-way analysis of variance (ANOVA) was used to analyse the data. Decision was made at significance level of 95% (p<0.05).

RESULTS

Physico-clinical changes and mortality

The oral administration of the aqueous-methanol *M. oleifera* leaf extract at a dose of 2000 mg/kg over a 48-hour period (48-hr, LD₅₀) did not produce any physical changes in the skin, fur, eyes and mucous membranes. Additionally, there were no significant changes in the clinical signs of respiration and heart rate, blood pressure, salivation, lacrimation, perspiration, urinary incontinence and defecation. Moreover, the animals did not show any signs of aggression during handling. However, at the onset of test extract administration (2000 mg/kg), there was a decrease in the locomotor activity of 3 out of the 5 animals which normalised after 10 minutes. No mortality or morbidity was observed in any of the animals during the entire period of the study.

Liver weight to body weight ratio (hepatic index)

Post mortem analysis of the hepatic index (liver to body weight ratio) revealed that there was a non-significant increase (p>0.05) in the hepatic index of the treatment group relative to the control (Table 1).

Table 1: Effect of the test substances on the mean body and liver weight of wistar albino rats.

Treatment	Body weight in grams	Liver weight in grams	Hepatic index
Control (physiological buffer saline)	114.00±15.47	5.96±1.33	0.05±0.01
2000mg/kg AQ-ME MO	125.90±22.05	8.26±2.47	0.07±0.02

n=5 values per group (Mean±SEM), SEM; Standard error of the mean, AQ-ME; aqueous methanol, MO-*Moringa oleifera*

Biochemical changes

The mean level of serum AST was significantly elevated in the treatment group (2000 mg/kg) relative to the control while there was a non-significant decrease in the level of serum ALT in the treatment group relative to the control (Table 2). From our observations, the AST/ALT ratio of control and treatment group (2000 mg/kg) was in the range 1.22 ± 0.21 and 1.58 ± 0.14 respectively.

Table 2: Biochemical profile of female wistar albino rats used in acute oral toxicity testing of AQ-ME *M. oleifera* leaf extract.

Parameter	Control (physiological buffer saline)	2000 mg/kg AQ-ME <i>MO</i> leaf extract
AST (U/L)	127.46 ± 6.64	$143.64 \pm 9.22^*$
ALT (U/L)	106.71 ± 16.01	91.18 ± 9.93
TB (mg/dL)	2.24 ± 1.24	3.00 ± 1.21
AST: ALT ratio	1.22 ± 0.21	1.58 ± 0.14

n=5, values (mean \pm SEM), asterisk (*): significantly different at $p < 0.05$, when compared to control, AQ-ME: aqueous methanol, *MO*: *Moringa oleifera*, AST: aspartate amino transferase, ALT: alanine amino transferase, TB: total bilirubin, U/L: units per litre, mg/dL: milligrams per decilitre.

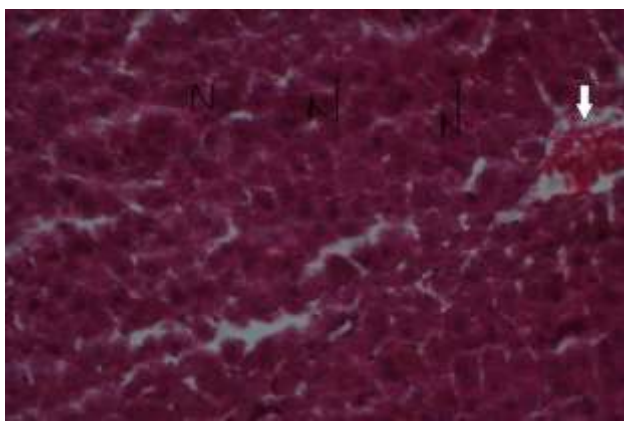


Figure 1: Liver section of control group rat orally administered with physiological buffer saline. The hepatocytes have a normal (N) cyto-architecture and there is mild congestion of the hepatic vein (Arrow) ($\times 10$ H/E).

Histopathological changes

To further evaluate the toxic potential of the AQ-ME *MO* leaf extract we performed histological examinations on the rat liver sections. Histopathology of the livers from the control group showed normal regular liver architecture characterised by; normal distinct hepatocytes and scanty congestion of the hepatic vein (Figure 1). However, histopathological work on the liver of experimental rats treated with a 2000 mg/kg dose of the AQ-ME *MO* leaf extract revealed a mild form of hepatic injury characterized by focal hepatocyte swelling and

necrosis in areas around the central vein and hepatic veins as well as congestion of hepatic vessels (Figure 2).

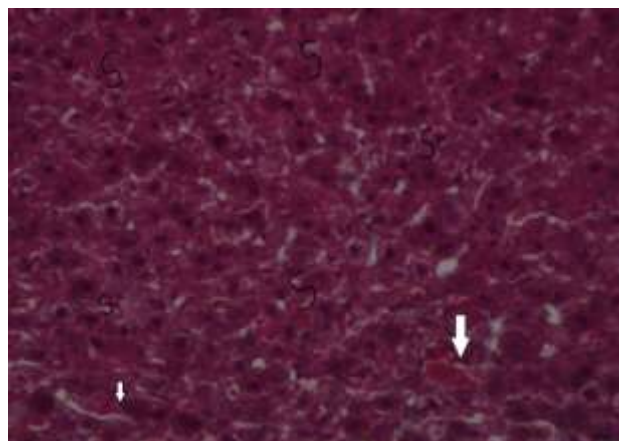


Figure 2: Liver section of treatment group rat orally administered with a 2000 mg/kg dose of aqueous-methanol *M. oleifera* leaf extract. There is hepatocyte swelling (s) and central vein congestion (Arrow) ($\times 10$ H/E).

DISCUSSION

The findings of the present study indicate that the AQ-ME *M. oleifera* leaf extract showed no relevant toxic manifestations and mortality at the test dose of 2000 mg/kg. According to Husna RN et al, the absence of toxic manifestations and mortality in animals treated with a particular test dose implies that the LD_{50} is greater than the test dose.¹⁵ Although this may hold true, studies that are more elaborate and long term are essential to determine the potential toxic ramifications of this extract.

In light of the findings of Butterweck V et al, some phytochemicals present in medicinal plants such as flavonoids may have antidepressant activity.¹⁶ In our previous work, having used the methods of Harborne JB et al, Kokate CK et al, Evans WC et al to qualitatively screen the extract for the presence of phytochemicals of pharmacological value, we reported the presence of flavonoids as well as other phytochemical constituents.¹⁷⁻²⁰ Thus, the observed decrease in locomotor activity in the experimental rats treated with a 2000 mg/kg dose of the extract may be attributable to the presence of the flavonoid phytochemical.

Hepatic index is the ratio of the liver to the overall body weight. It is a more accurate means of establishing the changes in the size of the liver as compared to only measuring the weight of the liver alone because to a large extent, liver weight is dependent on experimental animal size.²¹ In the present study, post mortem analysis of the hepatic index revealed that there was a non-significant increase in the hepatic index of the treatment group relative to the control. This observation is in agreement with the findings of previous authors who reported

alterations in the hepatic index of animal models treated with various plant extracts.^{22,23}

There was a significant elevation in AST in the treatment group relative to the control. This is suggestive of the occurrence of general cellular damage and is consistent with the observations of previous authors.^{24,25} However, since ALT is a more specific biomarker of liver injury and given the fact that AST may also be found in other tissues (cardiac, brain and skeletal muscles) these findings suggest that the aqueous-methanol *M. oleifera* leaf extract may not obviously cause toxic manifestations in the liver but may probably have some toxic effect on other tissues.²⁶ Furthermore, there was no significant difference in the levels of bilirubin between the control and treatment groups, further validating the low oral toxicity of the aqueous-methanol leaf extract at the tested dose. Bilirubin is a catabolic product of haemoglobin. Elevated levels of this substance accurately indicate the incidence of haemolysis.²⁷ Moreover, the AST/ALT ratio may be useful in the diagnosis of some diseases of the liver.²⁸ A value of less than 1 may point to the occurrence of leakage of ALT into systemic circulation while a ratio greater than 1 may be indicative of myocardial infarction. When the value is greater than 2 it may suggest alcoholic hepatitis or steatosis.²⁹

From our observations, the mean AST/ALT ratio of the treatment group rats was non-significantly higher than that of the control group rats. This result compares well with the work of other authors who studied the effects of these parameters post extract administration.³⁰

Based on the findings of histopathological work on the livers of rats treated with a 2000 mg/kg dose of AQ-ME *M. oleifera* leaf extract, there was indication of early signs of a mild form of liver injury implying that the extract may have some potentially deleterious effects on the liver at higher doses. This is in agreement with the work of other authors.³¹ The observed effects may possibly be due to primary or secondary metabolic products of one or several of the phytochemicals present in the extract.

CONCLUSION

Thus, in view of these results, the LD₅₀ of the aqueous-methanol *M. oleifera* leaf extract was found to be >2000 mg/kg body weight in the tested animal model. However, it is evident from these results that the aqueous-methanol *M. oleifera* leaf extract may have some potential of causing toxic effects at higher doses in female wistar strain albino rats. There is a need for further work on the sub-acute and chronic effects of this extract.

ACKNOWLEDGEMENTS

The authors would like to acknowledge the contribution of Dr. Joshua Orungo Onono in providing valuable insight into the statistical work related to this study. This research has been carried out under the financial support

of Carnegie Foundation of New York-Science Initiative Group through Regional Initiative in Science and Education-African Natural Product and Training Network (RISE-AFFNET).

Funding: Carnegie New York Science Initiative group through RISE-AFFNET

Conflict of interest: None declared

Ethical approval: The study was approved by the Faculty of Veterinary Medicine Biosafety, Animal Care and Use Committee (BACUC) of the University of Nairobi

REFERENCES

- Barnes J, Anderson LA, Philipson JD. Herbal Medicine. 3rd ed. London:Pharmaceutical press; 2007:1-23.
- Stickel F, Egerer G, Seitz HK. Hepatotoxicity of Botanicals. Pub Health Nutr. 2000;3:113-24.
- Fahey JW. *Moringa oleifera*: a review of the medical evidence for its nutritional, therapeutic and prophylactic properties, Part 1. Trees for Life J. 2005;1:5.
- Singh D, Arya PV, Aggarwal VP, Gupta RS. Evaluation of antioxidant and hepatoprotective activities of *Moringa oleifera* leaves in carbon-tetrachloride intoxicated rats. Antioxidants. 2014;3:569-91.
- Santos AF, Argolo AC, Paiva PM, Coelho LC. Antioxidant activity of *Moringa oleifera* tissue extracts. Phytother Res. 2012;26(9):1366-70.
- Faizi S, Siddiqui BS, Saleem R, Siddiqui S, Aftab K, Gilani AH. Fully carbamate and hypotensive thiocarbamate glycosides from *Moringa oleifera*. Phytochemistry. 1995;38:957-63.
- Guevara AP, Vargas C, Sakurai H, Fujiwara Y, Hashimoto K, Maoko T, et al. An antitumor promoter from *Moringa oleifera*. Mutation research. 1999;440:181-8.
- Iqbal S, Bhangar MI. Effect of season and production location on antioxidant activity of *Moringa oleifera* leaves grown in Pakistan. J Food Consumption Anal. 2006;19(6-7):544-51.
- Eze VC, Ananso JD. Assessment of water purification potential of *Moringa oleifera* seeds. Intern J Microbiol App. 2014;1(2):23-30.
- OECD guideline for testing of acute oral toxicity of chemicals, No 425. Environmental health and safety monograph series on testing and assessment, 2000.
- Anwar F, Kalsoom U, Sultana B, Mushtaq M, Mehmood T, Arshad HA. Effect of drying method on the total phenolics and antioxidant activity of cauliflower (*Brassica oleraceae L*) extracts. Intern Food Res J. 2013;20(2):653-9.
- Forster N, Ulrich C, Schreiner M, Arndt N, Schmidt R, Mewis I. Ecotype variability in growth and secondary metabolite profile in *moringa oleifera*. impact of water and sulphur availability. J Agriculture Food Chem. 2015;63:2852-61.

13. OECD guidance document on acute oral toxicity testing, No 423. Environmental health and safety monograph series on testing and assessment, 2000.
14. Schuman G, Bonora R, Ceriotti F, Ferard G, Ferrero CA, Franck PFH et al. International federation of clinical chemists (IFCC) primary reference procedures for the measurement of catalytic activity concentrations of enzymes at 37°C. Clin Chem Lab Med. 2002;40:725-33.
15. Husna RN, Noriham A, Nooraain H, Azizah AH, Amna OF. Acute oral toxicity effects of *Momordica charantia* in sprague dawley rats. Int J Biosci Biochem Bioinform. 2013;3(4):408-10.
16. Butterweck V, Jurgenliemk G, Nahrstedt A, Winterhoff H. Flavonoids from *Hypericum perforatum* shows antidepressant activity in the forced swimming test. Planta Med. 2000;66(1):3-6.
17. Okumu MO, Mbaria JM, Kanja LW, Gakuya DW, Kiama SG, Ochola FO. Phytochemical profile and antioxidant capacity of leaves of *Moringa oleifera* extracted using different solvent systems. J Pharmacogn Phytochem. 2016;5(4):302-8.
18. Harborne JB. Phytochemical methods: a guide to modern techniques of plant analysis' Chapman and Hall, London; 1998:49-188.
19. Kokate CK, Purohit AP, Gokhale SB. Pharmacognosy. 39th ed. Pune: Nirali Prakashan; 2007:108-109.
20. Evans WC. Trease and Evans Pharmacognosy. 16th ed. Edinburgh: Saunders; 2009:585-589.
21. Saad RA, El-Bab MF, Shalaby AA. Attenuation of acute and chronic liver injury by melatonin in rats. J Talibah Uni Sci. 2013;7(2):88-96.
22. Elvin-Lewis M. Should we be concerned about herbal remedies? J Ethnopharma. 2001;75:141-64.
23. Roy S, Chodhury DM, Paul SR. Antioxidant potential of rhizome of *Alocasia decipiens* Schott. Asian J Pharm Clin Res. 2013;120-2.
24. Cavanaugh BM. Nurse's: manual of laboratory and diagnostic tests. 4th ed. Philadelphia: Davis Company; 2003:688-690.
25. Kabubii ZN, Mbaria JM, Mathiu M. Acute toxicity studies of *Myrsine Africana* aqueous seed extract in male wistar rats on some haematological and biochemical parameters. Intern J Phytomed Phytotherapy. 2015;1:9.
26. Singh A, Bhat TK, Sharma OP. Clinical biochemistry of hepatotoxicity. J Clin Toxicol. 2011;S4:001.
27. Tripathi KD. Essentials of Medical Pharmacology. 5th ed. New Delhi: Jaypee Brothers; 2003:65-66.
28. Crook MA. Clinical chemistry and metabolic medicine. 7th ed. London: Hodder Arnold; 2006:426.
29. Sacher RA, Mepheron RA. Wildman's clinical interpretation of laboratory tests. 3rd ed. Pennsylvania: FA Davis Company; 1991:416-443.
30. Sagar K, Vidayasagar GM. Evaluation of acute toxicities of leaf extract of *Caesalpinia bonducella* (L). Flem Int J Pharma Biosci. 2010;6:1-15.
31. Roy S, Bhattacharya S. Arsenic induced histopathology and synthesis of stress proteins in liver of *Channa punctatus*. Ecotoxicology. Environ Saf. 2006;65:218-28.

Cite this article as: Okumu MO, Mbaria JM, Kanja LW, Gakuya DW, Kiama SG, Ochola FO, et al. Acute toxicity of the aqueous-methanolic *Moringa oleifera* (Lam) leaf extract on female Wistar albino rats. Int J Basic Clin Pharmacol 2016;5:1856-61.