

## Case Report

# Tarlov cyst- a rare occurrence: a short series of two cases

Kamal Kumar Arora<sup>1\*</sup>, Priti Chaudhary<sup>2</sup>

<sup>1</sup>Department of Orthopaedics, GMC, Amritsar, Punjab, India

<sup>2</sup>Department of Anatomy, AIIMS, Bathinda, Punjab, India

**Received:** 02 January 2020

**Revised:** 02 March 2020

**Accepted:** 04 March 2020

**\*Correspondence:**

Dr. Kamal Kumar Arora,

E-mail: [kka1967@gmail.com](mailto:kka1967@gmail.com)

**Copyright:** © the author(s), publisher and licensee Medip Academy. This is an open-access article distributed under the terms of the Creative Commons Attribution Non-Commercial License, which permits unrestricted non-commercial use, distribution, and reproduction in any medium, provided the original work is properly cited.

### ABSTRACT

Tarlov cysts were first noted and described by Tarlov in 1938. The overall incidence of these is somewhere between 08%-09% of the total population with female preponderance. Most commonly, they are in sacral region. Patients were either asymptomatic or reported in the OPD with low backache with radiculopathy CT guided micro fenestration of the cyst was done using the aspiration-injection technique in the symptomatic patient. The primary outcomes, pain and function, were assessed by using the lumbar spine outcomes questionnaire. The outcome in our cases was excellent in terms of pain intensity, personal care, lifting, walking, sitting etc., requiring no further surgical intervention.

**Keywords:** Tarlov cyst, Radiculopathy, CT guided fenestration

### INTRODUCTION

Tarlov cysts were first noted and described by Tarlov in 1938.<sup>1</sup> At first he found these cysts to be asymptomatic but on continued observation of these, he found some of these becoming symptomatic due to increase in size and eventual pressure symptoms on the surrounding structures resulting in radiculopathy, urethral dysfunction, sexual dysfunction, vaginismus and continued sex arousal dysfunction syndrome in females and abdominal dysfunction due to pressure. These cysts have female preponderance with most common presentation in the age group between 31-50 years. The overall incidence of these is somewhere between 08%-09% of the total population. Treatment is both conservative and surgical and is under evaluation for these rarely occurring entities. There has been a steady progression of case reports and small surgical series that report successful surgical treatment of Tarlov cysts with concomitant relief of patients' symptoms and improvement in their neurological dysfunction, yet patients are still told that these lesions are asymptomatic by physicians. These Tarlov cysts require continuous

watch over their occurrence and need new surgical interventional procedures for their life lasting cure.

### CASE REPORTS

We at a tertiary institute of Punjab, India came across two cases of Tarlov cysts while examining the low backache patients in outdoor patient department (OPD) of Orthopaedics. One of the patients (45 F) who reported in the OPD with low backache with radiculopathy was advised MRI and landed with an incidental finding of having a Tarlov cyst in the sacral region but without any signs and symptoms. There was no history of trauma/fracture of any kind. There was no sexual dysfunction/abdominal discomfort.

In another case, a female, 37 years of age, with chief complaint of low backache radiating to both of lower limbs mainly to the back of thighs bilaterally associated with tingling sensation (dysaesthesia) in the back of thighs. There was history of trauma six months back with a fall on pelvic region but there was no history of fracture of pelvis/in or around the hip joint. There was neither any

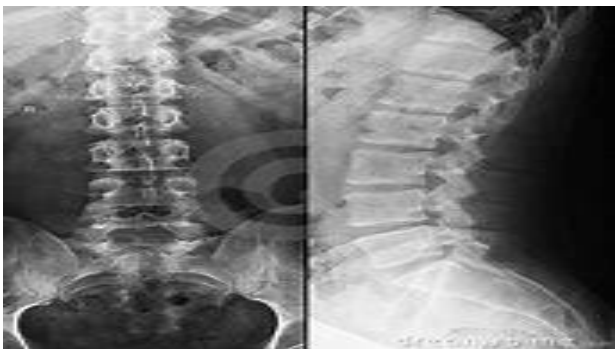
complaint of bowel or bladder disturbance nor there was any complaint of sexual disturbance.

Patient complained of neurogenic claudication and had to take rest after walking for a distance. All routine investigations were in normal limits in first case. X-rays were normal. In second case routine investigations were within normal limits except rise in connective tissue protein (CRP). She was advised X-ray lumbosacral spine both in anteroposterior and lateral views, which showed degenerative changes in the spine along with scoliosis with convexity towards left side, erosion in the region of L5-S1 and a shadow anteriorly in L5-S1 region.

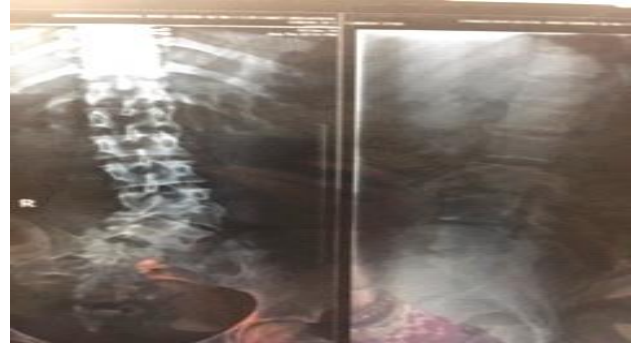Since she was having the radicular pain, she was advised magnetic resonance imaging (MRI) of the lumbosacral spine since it includes both soft tissue pathology along with bony pathology if any.

The MRI report showed a well-defined cystic mass lesion measuring 85×40 mm seen in presacral space extending from L5 to lower sacral region. No septae or soft tissue seen within it. It was originating from right perineural space at L5-S1 with widening of the neural foramina. No definite vertebral aplasia/hypoplasia was seen. The visualized vertebrae showed normal height and marrow signal intensity. No antero or postero listhesis. Visualized intervertebral disc showed normal morphology, height and signal intensity. The ligamentum flavum and facet articulations unremarkable. Thus, the MRI showed the likely features of giant Tarlov cyst.

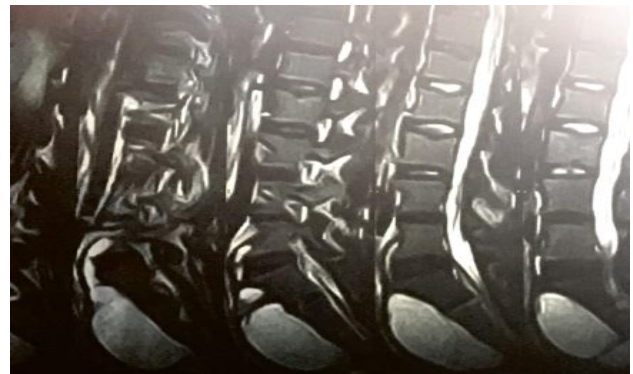Based upon MRI report first case was advised conservative treatment in the form of NSAIDs, pregabalin, physiotherapy and in second case after through counselling of the patient and after explaining all the risks involved, CT guided micro fenestration of the cyst was done using the aspiration-injection technique. Briefly, aspiration preceded by performance of diagnostic CT to select the level providing access to the cyst through the thinnest overlying bone. Following aspiration, an air-fluid level developed; this was monitored intermittently with CT fluoroscopy for evidence of rapid cyst refilling, which would indicate a connection to the thecal sac and thereafter was sealed with fibrin glue. She was kept on parenteral antibiotics post operatively for five days.



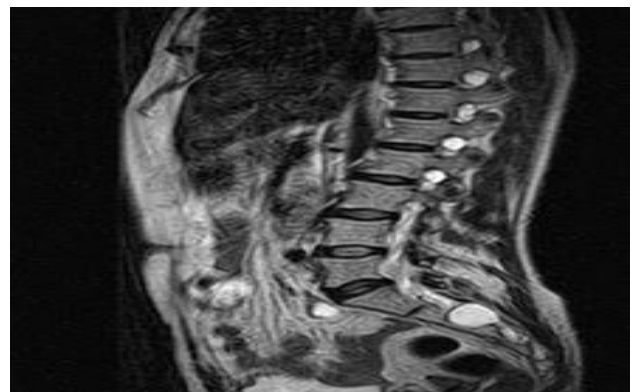
**Figure 1: X-rays of case 1.**



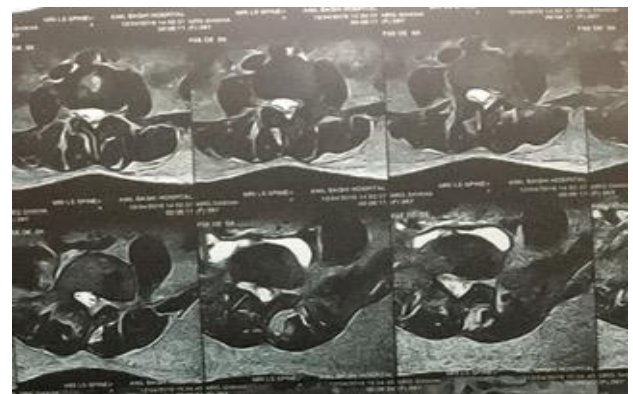
**Figure 2: X-rays of case 2.**



**Figure 3: MRI of first patient.**



**Figure 4: MRI of second patient.**



**Figure 5: Axial view of MRI of second patient.**

## DISCUSSION

Tarlov cysts were first described by Tarlov in 1938, after he identified five cysts in 30 adult patients at autopsy.<sup>1</sup> His 1953 monograph detailed their pathology, including compression and distortion of local nerves and hemorrhage.

These are also called perineural, sacral, lumbar, thoracic or cervical nerve root cysts. These are cerebrospinal-fluid-filled (CSF) sacs most frequently located in the spinal canal of the S1-to-S5 region of the spinal cord (less frequently in the cervical, thoracic or lumbar spine), and can be distinguished from other meningeal cysts (arachnoid cysts) by their nerve-fiber-filled walls. These cysts are formed within the nerve-root sheath at the dorsal root ganglion.<sup>2</sup>

Small, asymptomatic Tarlov cysts are actually present in an estimated five to nine percent of the general population; 86.6% of these were females and 13.4% were males. The largest majority of patients were 31 to 60 years of age, with a combined 80.4 percent in that age demographic.

An estimated 33 percent of patients have a cyst(s) present in other parts of the body also, mostly in abdomen or hand/wrists. Ensuing work has established that Tarlov cysts can cause axial sacrococcygeal pain; intrathecal hypotension; perineal pain; sensory loss; and bladder, bowel, and sexual dysfunction. Radicular symptoms have also been recognized.

As stated above, they are named for neurologist Isadore Tarlov, who described them in 1938.<sup>3</sup> They have been occasionally associated in patients with connective tissue disorders like Marfan syndrome, Ehlers-Danlos syndrome, Sjogren syndrome, Loeys-Dietz syndrome.<sup>5</sup>

It is postulated that a hemorrhage in nerve sheath causes an accumulation of red cells, which in turn impairs drainage of the veins in the perineurium and epineurium. This impaired drainage of venous blood from the perineurium and epineurium results in rupture of these veins and subsequent cyst formation.<sup>5-7</sup> Congenital etiology has also been suggested secondary to arachnoidal proliferations within the root sleeve, and subsequent obstruction of normal CSF flow.<sup>6</sup> The pathogenesis of these cysts remains unclear but the most accepted mechanism of the cyst formation has been described as a "ball valve" mechanism, which occurs secondary to stenosis at the ostium of the nerve root sheath, with the passage of CSF into the cyst, but restriction of its outflow, causing cystic dilation.<sup>6</sup> Tarlov cysts are relatively uncommon when compared to other neurological cysts.

These cysts often detected incidentally during MRI or CT scans for other medical conditions. They are also observed using magnetic resonance neurography with communicating subarachnoid cysts of the spinal meninges. Cysts with diameters of 1 cm or larger

are more likely to be symptomatic. Some 40% of patients with symptomatic Tarlov cysts can associate a history of trauma or childbirth as between 1948 and 1970, there were at least 59 cases of symptomatic spinal perineural cysts reported in the literature.<sup>8</sup>

In another study evaluating 500 sequential MRI scans of patients with low back pain, 4.6% (23) prevalence of Tarlov cyst was noted. Out of these 23 patients, only 01% (five) were symptomatic for either local sacral pain or sacral radiculopathy. Nabors classify arachnoid cysts into three types.<sup>9</sup>

### *Type I*

Extra-dural but no nerve roots or rootlets such as intra-sacral meningoceles, probably of congenital origin developing from the dural sac to which they are connected by a little collar. They are found at the point of exit of a dorsal nerve root from the dural sac. They are sometimes difficult to identify and can be "seen" as a type II cyst on imaging. These cysts are often associated with foramina enlargement and scalloping of the vertebrae. It is very important to distinguish them from sacral meningoceles going to the pelvic area. They are often associated with other congenital abnormalities (teratomas, dermoides, lipomas, and other abnormalities (uro-genital and ano-rectal).

### *Type II*

Extra-dural, nerve root present such as Tarlov or perineural cysts. There are often multiple cysts, mostly found in the sacrum area. There are two subtypes: Tarlov (perineural) cysts are located posteriorly to the root ganglion, with nerve fibres inside or secondly nerve tissue in the walls; they are not communicating with the perineural arachnoid space. Type-II cysts are very small in the upper sacral area, but can be bigger (up to 3 centimetres or 1.2 inches) if found located in the lower part of the sacrum. The second variant of type-II cysts are called "meningeal diverticuli". They are located anteriorly to the nerve root ganglion, with nerves fibres inside and communicating with the subarachnoid space.

### *Type III*

Intra-dural, these are either congenital or caused by trauma, they are rarely associated with other abnormalities and are rare in occurrence. About 75% can be found in the dorsal area. Most of the congenital type-III cysts can be found posterior to the spinal cord, as opposed to those caused by trauma which can be found anteriorly to the spinal cord.<sup>10,11</sup> Post traumatic inflammation induces cavitation and cystic formation of these and leads to greater secondary CNS injury.<sup>12</sup> Cellular migration causing these cyst cavities was observed both in vitro and in vivo and cavitation was observed to be prevented with the use of an anti-inflammatory drugs. Furthermore, a migration inflammatory cell into traumatized tissue has

been observed with inflammation. Usually, the diagnosis is self-evident.

Occasionally appearances are atypical and possible differential considerations include dural ectasia, spinal synovial cyst, meningocele, nerve sheath tumor, spinal metastases.

One of the important differential not to be missed is arachnoid cyst, which is a fluid-filled sac that occur on the arachnoid membrane that covers the brain (intra-cranial) and the spinal cord (spinal), they may also expand into the space between the pia mater and arachnoid membranes (subarachnoid space). The most common locations for intracranial arachnoid cysts are near the temporal lobe (the middle fossa), near the third ventricle (the suprasellar region), and the area that contains the cerebellum, pons, and medulla oblongata (the posterior fossa). In many cases, arachnoid cysts are asymptomatic. In cases in which symptoms occur, headaches, seizures and abnormal accumulation of excessive cerebrospinal fluid in the brain (hydrocephalus) are common.

An increase in pressure in or on the cysts may increase symptoms and cause nerve damage. Sitting, standing, walking and bending are typically painful, and often, the only position that provides relief is reclining flat on one's side. Symptoms vary greatly by patient and may flare up and then subside. Any of the following symptoms may be present in patients. Pain in the area of the nerves affected by the cysts, especially the buttocks, weakness of muscles, difficulty sitting for prolonged periods, loss of sensation on the skin, loss of reflexes, changes in bowel function, such as constipation, changes in bladder function, including increased frequency or incontinence, changes in sexual function.

Tarlov cysts near the sacrum can be divided into four categories, according to their experienced symptoms.

In group 1, pain on tailbones that radiates to the legs with potential weakness. In group 2, pain on bones, legs, groin area, sexual dysfunctions, and dysfunctional bladder. In group 3, pain that radiate from the cyst site across hips to the lower abdomen. In group 4, no pain, just sexual dysfunction and dysfunctional bladder.

Tarlov cysts that do not cause symptoms should be monitored periodically for any increase in size or whether symptoms develop.

There is no specific, accepted therapy for individuals with symptomatic Tarlov cysts. Treatment is directed toward the specific symptoms that are apparent in each individual and may include drugs, surgery and other techniques.

There are reports that changes in their diet and/or the addition of nutritional supplements to alter the alkalinity/acidity balance in the body may have helped with symptoms.

Non-steroidal anti-inflammatory drugs (NSAIDs) to treat nerve irritation and inflammation. Corticosteroid injections to relieve pain temporarily. Transcutaneous electrical nerve stimulation or TENS to relieve nerve pain.

Tarlov cysts have been treated aspiration. Results from aspiration vary and, in most cases, the cysts eventually fill up with cerebrospinal fluid again. Several different procedures, involve draining a Tarlov cyst and then filling the cyst with fat, or muscle.

Another nonsurgical procedure used to treat individuals with symptomatic Tarlov cysts uses a combination of substances that mimic blood clotting (fibrin glue). After the cysts drained, fibrin glue is used to seal or "glue" the cyst, preventing the cysts from filling up again. This procedure has led to short-term and long-term relief of symptoms. Complications have been reported in cases where the cyst communicates readily with the spinal fluid containing space.

Surgical removal is used to treat symptomatic individuals who do not respond to other forms of therapy. Surgical intervention depends upon numerous factors such as the progression of the disorder; the degree of nerve root compression; the size of the connection between the subarachnoid space and the cyst; an individual's age and general health. These methods, meanwhile, include lumbar-peritoneal and cystosubarachnoidal drainage and shunting. bipolar cautery to shrink cysts decompressive laminectomy. laminectomy with either total cyst resection, partial cyst wall resection and duroplasty/plication of cyst walls.<sup>14-22</sup>

Despite standard limitations such as malfunction and infection after shunting, persistence of pain after laminectomy, radicular deficits after ablative procedures, a prior review found that 88.6% of patients in the studies evaluated were satisfactorily relieved by surgery according to the outcome criteria of each report.

Recently microsurgical techniques, (laminectomy and microfenestration) that has been used to treat symptomatic Tarlov cysts. They appear to cause fewer adverse events and preserve neural tissue better.<sup>23-26</sup>

In another procedure, after microsurgery to expose and drain the cysts, a muscle flap is used to fill the cyst in order to prevent recurrence. Results of treatment may be disappointing if irreversible nerve damage has already occurred.

More recently minimally invasive percutaneous techniques have also emerged. Lee described using a patient's temporary response to cyst aspiration as a diagnostic maneuver to select candidates for surgery.<sup>27</sup> In 1997, Patel first described injecting autologous fibrin glue into aspirated cysts.<sup>28</sup> Four of four (100%) patients exhibited marked improvement without recurrence during 23 months, with one achieving lasting relief. They

postulated that fibrin deposition on cyst walls would impede CSF ingress, trigger fibrosis, and, ideally, promote cyst contracture. Zhang et al subsequently reported that 100% of 31 patients treated with intra-cystic fibrin glue injection achieved satisfactory relief without recurrence during 28 months of follow-up.<sup>29</sup> This methodology was further refined by the development by Murphy of the 2-needle technique evaluated in this report.<sup>30</sup> Maintaining an equilibrium of intra cystic pressure during aspiration-injection, this procedure reduced pressure-related procedural radicular pain sometimes noted with the single-needle technique and perhaps improved fibrin sealant filling.

We in the present study followed Murphy's two needle aspiration injection technique and found this method effective and reliable and without any major complications.

## CONCLUSION

Despite widespread belief to the contrary, it has been known for some 70 years that perineurial cysts are sometimes symptomatic, and that associated symptoms and signs may be relieved by successful treatment of the troublesome cyst. Surgical methods are effective but are often complicated by infection, postoperative CSF leak, or damage to neural tissue; these make them an imperfect first-option treatment and suggest the need for a percutaneous image-guided approach. The double needle aspiration-injection technique described herein constitutes a safe and efficacious treatment option, and one that holds promise for relieving cyst-related symptoms in many patients with very small risk.

*Funding: No funding sources*

*Conflict of interest: None declared*

*Ethical approval: Not required*

## REFERENCES

1. Tarlov IM. Perineurial cysts of spinal nerve roots. Arch Neurol Psychiatry. 1938;40:1067-74
2. Goyal RN, Russell NA, Benoit BG, Belanger JM. "Intraspinal cysts: a classification and literature review". Spine. 1987;12:209-13.
3. Pankaj KS, Vinay KS, Amir A, Sanjeev G. Tarlov Cyst and Infertility. J Spinal Cord Med. 2009;32(2):191-9.
4. Arnold PM, Teuber J. Marfan syndrome and symptomatic sacral cyst: report of two cases. J Spinal Cord Med. 2013;36(5):499-503.
5. Tarlov IM. Spinal perineurial and meningeal cysts. J Neurol Neurosurg Psychiatry. 1970;33:833-43.
6. Paulsen RD, Call GA, Murtagh FR. Prevalence and percutaneous drainage of cysts of the sacral nerve root sheath (Tarlov cysts). Am J Neuroradiol. 1994;15:293-7.
7. Schreiber F, Haddad B. Lumbar and sacral perineurial cysts causing pain. J Neurosurg. 1951;8:504-9.
8. Wilkins RH. Prevalence and percutaneous drainage of cysts of the sacral nerve root sheath (Tarlov cysts) [commentary]. Am J Neuroradiol. 1994;15:298-9.
9. Nishiura I, Koyama T, Handa J. Intrasacral perineurial cyst. Surg Neurol. 1985;23(3):265-9.
10. Nabors MW, Pait TG, Byrd EB. Updated Assessment and Current Classification of Spinal Meningeal cysts. J Neurosurg. 1988;68(3):366-77.
11. Singh PK, Singh VK, Azam A, Gupta S. Tarlov Cyst and Infertility. J Spinal Cord Med. 2009;32(2):191-7.
12. Zhang T, Zhenhua L, Weiming G, Bingwei S, Shuheng L, Kai Z. Percutaneous Fibrin Glue Therapy for Meningeal Cysts of the Sacral Spine with or without Aspiration of the Cerebrospinal Fluid. J Neurosurg Spine. 2007;7(2):145-50.
13. Bartels RH, Overbeeke JJ. Lumbar cerebrospinal fluid drainage for symptomatic sacral nerve root cysts: an adjuvant diagnostic procedure and/or alternative treatment? Technical case report. Neurosurg. 1997;40:861-4.
14. Morio Y, Nanjo Y, Nagashima H. Sacral cyst managed with cyst-subarachnoid shunt: a technical case report. Spine. 2001;26:451-3.
15. Siqueira EB, Schaffer L, Kranzler LI. CT characteristics of sacral perineurial cysts: report of two cases. J Neurosurg. 1984;61:596-8.
16. Rodziewicz GS, Kaufman B, Spetzler RF. Diagnosis of sacral perineurial cysts by nuclear magnetic resonance. Surg Neurol. 1984;22:50-2.
17. SaMC, Sa RC. Tarlov cysts: report of four cases [in Portuguese]. Arq Neuropsiquiatr. 2004;62:689-94.
18. Tanaka M, Nakahara S, Ito Y. Surgical results of sacral perineurial (Tarlov) cysts. Acta Med Okayama. 2006;60:65-70.
19. Nishiura I, Koyama T, Handa J. Intrasacral perineurial cyst. Surg Neurol. 1985;23:265-9.
20. Voyadzis JM, Bhargava P, Henderson FC. Tarlov cysts: a study of 10 cases with review of the literature. J Neurosurg. 2001;95:25-32.
21. Strully KJ, Heiser S. Lumbar and sacral cysts of meningeal origin. Radiology. 1954;62:544-9.
22. Yucesoy KK, Naderi S, Ozer H. Surgical treatment of sacral perineurial cysts: a case report. Kobe J Med Sci. 1999;45:245-50.
23. Mummaneni PV, Pitts LH, Cormack BM. Microsurgical treatment of symptomatic sacral Tarlov cysts. Neurosurg. 2000;47:74-8.
24. Guo D, Shu K, Chen R. Microsurgical treatment of symptomatic sacral perineurial cysts. Neurosurg. 2007;60:1059-65.
25. Rasmussen MM, Clemmensen D, Karabegovic S. A novel microsurgical method for the treatment of spinal nerve root cysts. Dan Med J. 2012;59:4539.
26. Caspar W, Papavero L, Nabhan A. Microsurgical excision of symptomatic sacral perineurial cysts: a study of 15 cases. Surg Neurol. 2003;59:101-5.
27. Lee JY, Impekovon P, Stenzel W. CT-guided percutaneous aspiration of Tarlov cyst as a useful diagnostic procedure prior to operative intervention. Acta Neurochir (Wien). 2004;146:667-70.

28. Patel MR, Louie W, Rachlin J. Percutaneous fibrin glue therapy of meningeal cysts of the sacral spine. *Am J Roentgenol.* 1997;168:367-70.
29. Zhang T, Li Z, Gong W. Percutaneous fibrin glue therapy for meningeal cysts of the sacral spine with or without aspiration of the cerebrospinal fluid. *J Neurosurg Spine.* 2007;7:145-50.
30. Murphy K, Wyse G, Schnupp S. Two-needle technique for the treatment of symptomatic Tarlov cysts. *J Vasc Interv Radiol.* 2008;19:771-3.

**Cite this article as:** Arora KK, Chaudhary P. Tarlov cyst- a rare occurrence: a short series of two cases. *Int J Res Orthop* 2020;6:643-8.