

Original Research Article

Functional outcome of acetabular fracture fixation by modified Stoppa's approach

Rahul Kadam, Preetam Singh Dagar*, Abhay Challani, Ashutosh Jadhav, Jehangir Pestonji

Department of Orthopaedics , MGM Medical College , Kamothe , Navi Mumbai, Maharashtra, India

Received: 26 October 2018

Revised: 04 December 2018

Accepted: 06 December 2018

*Correspondence:

Dr. Preetam Singh Dagar,

E-mail: drpreetamdagar@gmail.com

Copyright: © the author(s), publisher and licensee Medip Academy. This is an open-access article distributed under the terms of the Creative Commons Attribution Non-Commercial License, which permits unrestricted non-commercial use, distribution, and reproduction in any medium, provided the original work is properly cited.

ABSTRACT

Background: We analysed the clinical and functional outcome of acetabular fracture treated by Modified Stoppa approach. In this study, we also analysis Intraoperative and post-complications of fractures treated by the modified Stoppa approach.

Methods: All of the, 20 patients who needed the anterior approach for the treatment of acetabular fracture at our hospital from May 2016 To May 2018, were subjected to surgery via modified Stoppa approach. Pre-operative Anterior posterior (AP) view and Judet and CT scan were done to classify the fracture. Functional outcome was assessed by using the modified Merle D' Aubigne Postel clinical grading system, radiological outcome by Matta et al and perioperative complication were assessed by retrospectively analyzing medical records and radiographics examination.

Results: The clinical results were excellent in 12 cases , very good 2 in cases and good in 1 cases , fair in 1 case and poor in 4 cases. Although the radiological 12 cases had anatomical reduction, 5 imperfect reduction and 3 poor reduction.

Conclusions: It can be concluded that the modified Stoppa approach could be used as an alternative to the ilioinguinal approach. It's provides excellent access and visulaistion to the anterior column and quadrilateral surface and the rates of complication were less as compare to ilioinguinal approach.

Keywords: Modified Stoppa approach, Ilioinguinal approach, Judet view

INTRODUCTION

It is accepted that quality of anatomical reduction of an acetabulum fracture affects the final outcome.¹ In order to achieve good results, focus on anatomical reduction, rigid fixation and early rehabilitation is necessary.^{2,3,4} However, special care is required to avoid injury to nearby important adjacent pelvic structures during fixation of acetabular fractures making it a challenging task.

As these fractures are more complicated several obstacles are encountered during operative reduction approaches.

Presently there are various operative approaches described for management of acetabular fracture. Deciding an approach depends on the fracture configuration, skin condition at the site of surgical incision, the direction of displacement and duration from initial injury.⁵

The Stoppa approach is an approach which is commonly used in the treatment inguinal hernias.^{6,7} In the early 1990, Hirven Salo et al and Cole and Bolhofner had described a modified stoppas approach for internal fixation of acetabular and pelvic fractures.^{8,9} It comprised of an anterior approach with splitting of the rectus

abdominis muscle to gain intrapelvic extraperitoneal access.

This approach offers a direct access to the pubis, the posterior surface of the ramus, the quadrilateral surface, the pubic eminence and the infrapectineal surface, along with the sciatic notch and anterior sacroiliac joint.¹⁰ Addition of lateral window helps in improving the exposure of the quadrilateral surface and posterior column.

The modified Stoppa intrapelvic approach has received greater acceptance as an alternative for the ilioinguinal approach. In view of the above available literature, we performed this study to evaluate the efficacy of the operative technique and internal fixation of the acetabular fractures using the Modified Stoppa approach.

Aims and Objectives

- To study the efficacy of the operative technique via modified Stoppa approach.
- To study intraoperative and postoperative complications and the duration of surgery.

METHODS

This retrospective study includes 20 patients of acetabular fracture treated by Modified Stoppa Approach from May 2016 to May 2018. Patients admitted to MGM hospital, Kamothe were selected.

Inclusion criteria

All simple and combined acetabular fracture types with anterior displacement.

Exclusion criteria

Posterior only pattern (eg: posterior wall, posterior column, transverse) that exist below the ischial spine, Previous history of cesarean section, hysterectomy, bladder injury.

In preoperative evaluation, for operative planning, plain X-rays (AP pelvic view and Judet view) and 3D or 2 D CT scan were done (Figure 1). All fractures were classified according to Judet and Letournel classification (Table 1).

All patients were treated with the modified Stoppa approach except 3 patients in which additional lateral window was used to assist for proper fixation of fracture. All 30 patients were regularly followed up at 2 weeks, 6 weeks, 3 months, 6 months and 1 year to evaluate functional outcome by the Modified Merl D' Aubigne and Postel clinical grading system.

On the basis of postoperative X-rays, radiological scoring was done using MATTA et al scoring system.

Table 1: Fractures classification according to Judet and Letournel classification.

Fracture pattern	Number
Transverse	1
T-type	2
Both column	6
Anterior column	4
Anterior column-posterior hemitransverse	4
Transverse-posterior wall	3

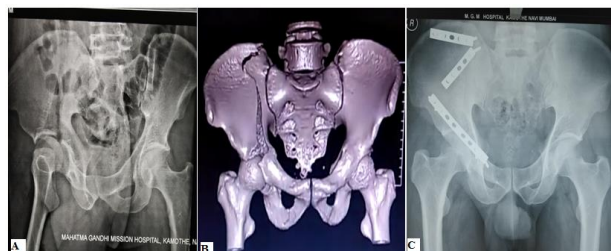

Figure 1: Preoperative PBH X-ray (A) and 3D CT scan image (B) shows fracture of acetabulum and postoperative PBH X-ray (C) shows fixation of fractures by plates.

Surgical technique

The patient is positioned in supine position on the operation table. The surgeon stands on the opposite side of the fracture to allow improved visualization and better access to the true intrapelvic cavity. A transverse skin incision is used starting 2 cm above the pubic symphysis. The linea alba is incised at the midline and split vertically from below to upwards. Protecting the bladder, the rectus abdominis muscle is then retracted upwards. Sharp dissection is used to elevate the rectus to expose the symphysis body and pubic ramus. The rectus and neurovascular structures are protected by retracting them laterally and anteriorly. On gaining access to the internal aspect of the pelvis, the corona mortis vessels may be encountered. These vessels are ligated if identified and should not be actively explored. Full access is then developed from anterior to posterior along the pelvic brim, sharply dividing and elevating the iliopectineal fascia superiorly and obturator fascia inferiorly and exposing the medial wall of the acetabulum, the fracture and the pelvic brim. The obturator nerves and vessels are easy to identify as they pass through the sciatic foramen. Make sure these are protected throughout the duration of surgery. Extreme precaution is exercised to protect the external iliac artery and vein for their protection. These can be found to lie just over the iliopsoas muscle. These structures are retracted upwards. On proper exposure of the fracture site, anatomical reduction was attempted and internal fixation was performed.

In cases where the modified Stoppa approach alone was found to be inadequate for fracture reduction or implant

fixation, the use of a lateral window made along the iliac crest proved beneficial.¹¹

Postoperatively, in patients in whom good fixation was achieved during surgery, passive range of motion exercises of the hip joint were started. These patients were safely started on continuous passive motion device. Depending on associated injuries, patient condition and accuracy of anatomical reduction patients were encouraged to walk with crutches.

The statistical analysis p-value for the Friedman test is less than that of 0.05 indicates significance of difference between the means mean functional score when compared at different time points. To find out exact significance we used Wilcoxon-signed rank test in which p-value for less than that of 0.05 indicates significance of difference between the respective time points.

RESULTS

The study group included 14 males and 6 females with an average age of 32.7 years (range 20 to 60) (Figure 2). The mode of injury was motor vehicle accidents in 16 patients and fall from height in 4 patients (Figure 3).

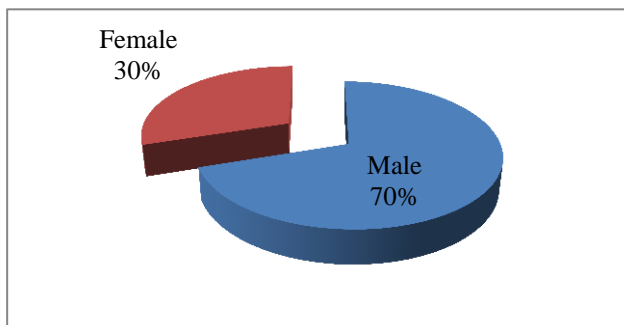


Figure 2: Gender distribution among study population.

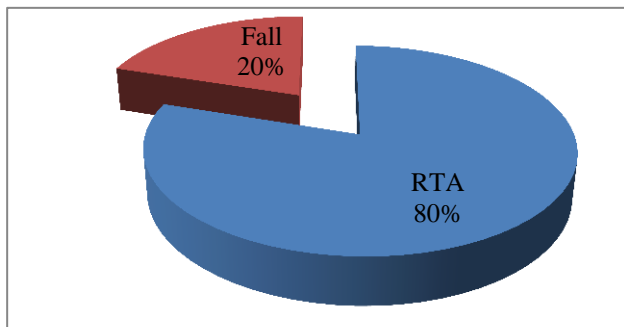


Figure 3: Mechanism of injury (MOI) distribution among study population.

The clinical outcome of 20 patients at 1 year follow up shows excellent results in 12 (60%) patients, very good in 2 (10%) patients, good in 1 (5%) patient, fair in 1(5%) patient and poor in 4 (20%) patients. 70% (14 of 20) of

patients could walk unassisted by the end of final follow up.

Radiographic grading of the fracture reduction immediately post-operatively revealed that 12(60%) patients were graded as excellent, 5(25%) as good and 3 (15%) as poor (Figure 4). The average union time for fracture healing was 9 weeks and 3 days.

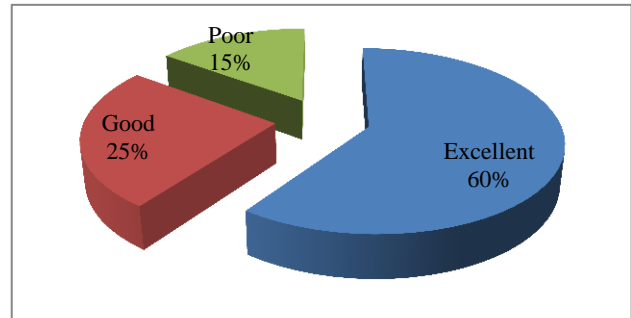


Figure 4: Radiological outcomes assessed by Matta et al immediately postoperative.

Average duration of surgery was 140 minutes and the average amount of blood loss during surgical procedure was 736 ml. 12 patients out of 20 needed blood transfusion during and/or post- operatively depending on pre and/or postoperative haemoglobin.

Out of 20 patients, intraoperative complications occurred in only one patient as a result of bleeding due to injury to corona mortis vessels. Haemostasis was achieved by compression packing and ligation of vessels. In late complications, 4 (20%) patients out of 20 had developed mild to moderate arthritic changes (Table 2).

Table 2: Complications.

Complications	No. of patients
Corona mortis vessels injury	1
Arthritic change	4

DISCUSSION

Since the ancient times management of acetabular fractures has been done through anterior, posterior, extensile or combined approaches where emphasis was given on improving the visualisation of the fractures and their anatomical reduction. The commonly used ilioinguinal approach for anterior and transverse fracture fixation, carries a disadvantage of a higher complication rate owing to complex anatomy in the nearby surgical region and a steep surgical learning curve.

The purpose of this study was to present our experience of internal fixation of the acetabular fractures using a modified Stoppa approach. In our study comprising of 20 patients, 15 (75%) patients had good to excellent clinical outcomes and 5(25%) patients had fair to poor results.

Out of these 5 patients, 2 patients had poor results due to impaction injury in spite of achieving good anatomical reduction, 2 patients developed early arthritic changes because of inadequate fracture reduction while 1 patient had implant failure in spite of good anatomical reduction. A similar study by Jakob et al showed that 17 (85%) patients had good to excellent results and 3 (15%) patients had poor results.¹² In another study by Sagi et al 51 (91%) of patients had good to excellent result.¹³ A study of Cole and Bolhofner et al also showed similar results with excellent to good clinical outcomes in 89% of patients and fair or poor outcome in 11% of patients.¹⁴

In our study the radiological outcome was excellent in 12 (60%) patients, good in 5 (25%) patients and poor in 3 (15%) patients. A similar study Kim et al shows excellent results in 17 (77%) patients, good in 4 (18%) patients and poor results seen in only one (4.5%) patient.¹⁵ A study by Jakob et al shows anatomic and satisfactory reduction achieved in 13 out of 14 patients of acetabular fracture.¹²

Three fractures with posterior column involvement (1 anterior with posterior column, 1 T-type and 1 anterior column-posterior hemitransverse), additional lateral window was used for fixation. These patients subsequently had less than satisfactory functional outcomes.

In our study the complication rates were very low. Out of 20 patients, only one patient had intraoperative complication as a result of bleeding due to injury to corona mortis vessels which was managed by packing and ligation of vessels. One patient had loss of reduction with implant failure due to early full weight bearing against advice. All 3 patients who had poor anatomical reduction according to Matta et al and one with implant failure developed mild to moderate arthritic changes later. Letournel and Judet et al reported infection in 3 (2.1%) patients, 8 (6%) patients with iliac and sciatic nerve palsies and 2 (2.1%) patients with external iliac vein injuries and deep vein thrombosis (DVT) in remaining 1 patient.¹⁶

CONCLUSION

In view of our results, we conclude that Modified Stoppa approach has an overall superior anatomical reduction and implant fixation associated with a decreased rate of complications as compared to widely used ilioinguinal approach. In view of the findings of our study, we highly recommend the use of Modified Stoppa approach for fixation of acetabular fractures.

ACKNOWLEDGEMENTS

We thank all faculties, my colleagues, my parents and the patients for the constant support and motivation. We would also like to thank MGM hospital for allowing us to this study

Funding: No funding sources

Conflict of interest: None declared

Ethical approval: The study was approved by the institutional ethics committee

REFERENCES

1. Letournel E. Acetabular fracture; classification and management. *Clin Orthop.* 1980;151:81-106.
2. Letournel E. The treatment of acetabular fracture through the ilioinguinal approach. *Clin Orthop Relat Res.* 1993;(292):62-76.
3. Matta JM. Fracture of the acetabulum; accuracy of reduction and clinical results in patients managed operatively within and clinical results in patients managed operatively within 3 weeks after the injury. *1996;78(11):1632-45.*
4. Min BU, Nam SY, Kang CS. Complication of surgical treatment in patients with acetabular fractures. *J Korean Hip Soc.* 2000;12(3):253-60.
5. Kim HY, Yang DS, Park CY, Choy WS. Newly modified Stoppa approach for acetabulum fracture. *International orthopaedics (springer).* 2013;37:1347-53.
6. Rives J, Stoppa R, Fortesa L, Nicaise H. Dacron patches and their place in surgery of groin hernia: 65 cases collected from a complete series of 274 hernia operations. *Ann Chir.* 1968;22(3):159-71.
7. Stoppa RE, Rives JL, Warlaumont CR, Palot JP, Verhaeghe, Delattre JF. The use of Dacron in the repair of hernia of the groin. *Surg Clin North Am.* 1984;64(2):269-85.
8. Hirvensalo E, Lindahl J, Kiljunen V. Modified and new approaches for pelvic and acetabulum surgery. *Injury.* 2007;38(4):431-41.
9. Cole JD, Bolhofner BR. Acetabular fracture fixation via modified Stoppa approach limited intrapelvic approach. Description of operative technique and preliminary treatment results. *Clin orthop Relat Res.* 1994;(305):112-23.
10. Stoppa RE. The treatment of complicated groin and incisional hernias. *World J Surg.* 1989;13:545-54.
11. Court-Brown CM, Heckman JD, McQuen MM, Ricci WM, Tornetta III P, Mckee MD. *Rockwood and Green. Volume 1. Edition 8. Chapter 32. 1065-1067.*
12. Jakob M, Drosner R, Zobrist R, Messmer MA, Regazzoni P. A less invasive anterior intrapelvic approach for the treatment of acetabulum fracture and pelvic injuries. *J Trauma.* 2006;60(6):1364-70.
13. Sagi HC, Afsari A, Dziadosz D. The anterior intra pelvic (modified Rives Stoppa) approach for fixation of acetabulum fracture. *J orthop trauma* 2010;24(5):263-70.
14. Kim HY, Yang DS, Park CK, Choy WS. Modified Stoppa approach for surgical treatment of acetabulum fracture. *Clin Orthopaedics Surg.* 2015;7:29-38.
15. Cole JD, Bolhofner BR. Acetabular fracture fixation via a modified stoppa limited intra pelvic approach;

description of operative technique and preliminary treatments results. *Clin Orthop Relat Res.* 1994;305:112-23.

16. Letournel E, Judet R. *Fractures of the acetabulum.* Berlin Springer – Verlag; 1974.

Cite this article as: Kadam R, Dagar PS, Challani A, Jadhav A, Pestonji J. Functional outcome of acetabular fracture fixation by modified Stoppa's approach. *Int J Res Orthop* 2019;5:177-81.