

## Original Research Article

# Treatment of supra condylar fractures of humerus in children, a SKIMS medical college study

Jawed Ahmed Bhat\*, Arshad H. Wani, Abid Din, Reyaz Dar, Naseer Ah Mir

Department of Orthopaedics, SKIMS Medical College, Srinagar, Jammu and Kashmir, India

**Received:** 11 December 2019

**Revised:** 18 June 2020

**Accepted:** 30 June 2020

### \*Correspondence:

Dr. Jawed Ahmed Bhat,

E-mail: [hananbhat1997@gmail.com](mailto:hananbhat1997@gmail.com)

**Copyright:** © the author(s), publisher and licensee Medip Academy. This is an open-access article distributed under the terms of the Creative Commons Attribution Non-Commercial License, which permits unrestricted non-commercial use, distribution, and reproduction in any medium, provided the original work is properly cited.

### ABSTRACT

**Background:** Supracondylar fractures of the humerus account for sixty percent of all fractures around the elbow in children. Delayed presentation of these fractures is very common even in developed countries. The aim of the present study was to evaluate the clinical, radiological and functional results following closed reduction (C/R) and percutaneous pinning of widely displaced supracondylar fractures of humerus. An objective of this study was to study supracondylar fractures of humerus in children in Skims medical College.

**Methods:** A total 86 patients with displaced extension type supracondylar fractures (gartland type III) of humerus were managed by closed reduction and percutaneous fixation at Skims medical college after achieving optimal and satisfactory reduction. There were 52 boys and 28 girls. Average age was 6.69 years (range 2-12).

**Results:** A total 86 patients were successfully treated with C/R and cross pinning. 6 patients were lost to follow-up. 80 patients with a minimum follow-up period of 12 months formed the basis of this study.

**Conclusions:** C/R and pinning is effective method despite delayed presentation. Strict anatomical reduction and stable fixation minimises the risk of developing cubitus varus deformity.

**Keywords:** Closed reduction, Fractures, Humerus, Kirschner wire, Supra condylar, Volkman's ischaemic contracture

### INTRODUCTION

Fractures of the elbow are very common and supracondylar fractures account for about 60% of these fractures.<sup>1</sup> Closed reduction and pinning are still the choicest of treatment for these injuries.<sup>2,3</sup>

The delay in the treatment of these fractures could be multifactorial. Methods used for treating such injuries varies from closed reduction and use of splint, traction with or without delayed internal fixation.<sup>4,5</sup> Closed reduction and pinning, open reduction and internal fixation.<sup>6-9</sup> Late presentation makes treatment difficult because of excessive swelling. Complications like iatrogenic nerve injury, VIC, Cubitus varus, elbow stiffness and myositis ossificans are always there.<sup>10-13</sup>

Some studies have refuted the fears of increased perioperative complication rate with delayed elective surgery but there is no study which has evaluated the long-term outcome of these patients.<sup>6,14-16</sup>

The aim of the present study was to evaluate the clinical, radiological and functional results following closed reduction and percutaneous pinning of widely displaced supracondylar fractures of humerus.

### METHODS

A total 86 patients with displaced extension type S.C fractures (gartland type III17) of humerus were treated at SKIMS medical college from September 2006 to September 2016 .C/R under G/A with fluoroscopic control

and crossed percutaneous pinning using 2 Kirschner wire (K wires) was used in fifty-eight patients and 28 needed open reduction and internal fixation. Patients were followed for 12 months. On presentation, age, sex, side of injury, any swelling and time since injury were determined. Thorough clinical examination was done. Creamer wire splintage was done and limb elevated. X-rays of opposite elbow were done to measure normal Bauman’s angle for that patient and for assessment of fracture reduction.

All the patients were operated under G/A within 6 hours.

Percutaneous fixation was done with technique originally described by Swenson et al. Following fracture reduction, elbow was immobilized in hyperflexion using adhesive strapping to facilitate intraoperative radiography and pinning.<sup>18</sup> When gross swelling of elbow made palpation of medial epicondyle difficult, a mini open technique was used for placement of medial wire as described by Green et al.<sup>19</sup> Once K wires were passed (Figure 2), the elbow was extended, radial pulse palpated and carrying angle and stability of reduction were assessed. The K wires were left outside the skin after being bent at right angles. An above elbow slab was applied in 45 degrees flexion. K wires were removed at 3-4 weeks after obtaining X-rays to assess union and myositis ossificans. At each follow-up, the carrying angle, ROM of both elbows and DNV were recorded. Outcome was graded according to Flynn’s criteria.<sup>20</sup>

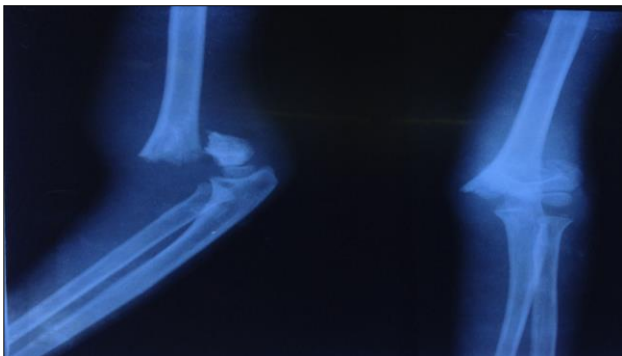


Figure 2: Pre-operative radiograph.

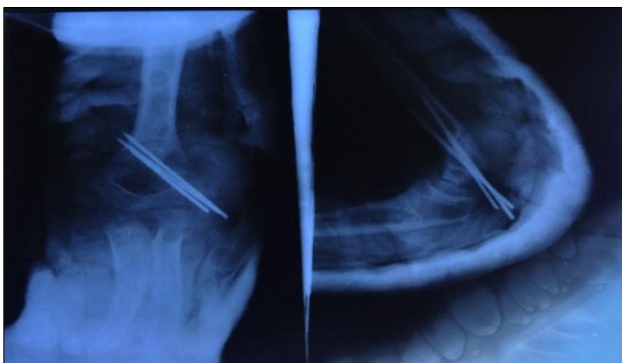


Figure 2: Post-operative radiograph.

**RESULTS**

There were 52 boys and 28 girls. Average age was 6.69 years (range 2-12).

Table 1: Age distribution.

	Frequency	%
<b>Age in years</b>		
1-5	29	36.25
5-10	36	45.00
>10	15	18.75
<b>Mode of trauma</b>		
<b>Mechanism</b>		
Fall on outstretched hand	62	77.5
Fall from tree	14	17.5
Road traffic accident	4	5.0

Gender distribution were 52 males and 28 females (Figure 3).

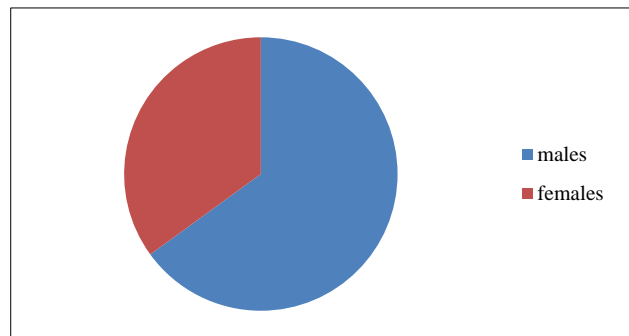


Figure 3: Gender distribution.

Table 2: Displacement of fractures.

Location	Frequency	%
<b>Posteromedial</b>	63	78.75
<b>Posterolateral</b>	12	15.0
<b>Posterior</b>	5	6.25

Fall on outstretched hand was mechanism of injury, in 62 patients. 14 patients sustained trauma from fall from tree and 4 from road traffic accidents. 56 patients had fractures of dominant extremity. 63 patients had posteromedial displacement, 12 patients had displacement post-eolaterally and 5 posterior displacement (Figure 1). The average delay in presentation was 19.5 hours (12 hours-5 days). 7 patients had 3-4 attempts at reduction before presenting to this hospital. History of message was present in 5 patients. 8 patients had neurological complication at presentation. 6 patients presented with interosseous nerve palsy and 2 patients had radial nerve palsy. Grade 1 open wound was seen in 4 patients, 8 patients presented with absent radial pulse but capillary pulsation was adequate in all. Pulse was restored in 7 patients following closed reduction. In one the radial pulse didn’t appear after C/R and capillary circulation was deteriorated, the brachial

artery was explored through anteromedial approach and radial circulation was restored.

A total 86 patients were successfully treated with C/R and cross pinning. 6 patients were lost to follow-up. 80 patients with a minimum follow-up period of 12 months formed the basis of this study. Open reduction through medial or lateral approach was used in twenty-eight patients. The mean delay in presentation in these patients was 19.5 hours. In all these patients, there was buttonholing of the proximal fragment through the brachialis muscle which prevented C/R, average anesthesia time was 50 minutes (range 24-64 minutes). Seventy patients were treated with 2 crossed K wires. In 10 patients with unstable fractures 2 lateral K wires were employed in addition to medial K wires. In five patients, a small medial incision was used over medial epicondyle to retract ulnar nerve and help in passing the medial pin. With this technique authors had no iatrogenic nerve damage. The mean hospitalization time was 24 hours. All fractures united. The average duration of plaster and pin fixation was 21 days (20 days -28 days).

## DISCUSSION

Closed reduction and percutaneous pinning under C arm are now accepted standard treatment of displaced supra condylar fractures of humerus.<sup>2,12,21-23</sup> Late presentation is quite common in this hospital because it caters north, south and central Kashmir.

Numerous complications have been encountered in SC fractures and their management. Many authors have recommended emergent treatment of these fractures to reduce complications.<sup>24,25</sup>

The results of present study indicate that majority of these SC fractures can be treated effectively with C/R and perfect pinning. A major concern with delayed treatment is inability to achieve satisfactory C/R because of swelling, thus produce higher chances of conversion to open reduction. The rate of conversion to open reduction has been reported in literature as ranging from less than 3% to up to 46%.<sup>22,26-28</sup> In this series of eighty-six patients closed reduction was successful in fifty-eight cases and only twenty-eight patients required open reduction. Gupta et al reported 6% rate of open reduction when only Gartland type 3 fractures were considered with a delay of >12 hours. Mehlman et al reported a conversion rate of 3% for delayed treatment group <8 hours in that study.

Archibeck et al reported entrapment of brachialis muscle as a cause of 90% of irreducible SC fractures.<sup>29</sup> There was no correlation between an increase in time to surgical intervention and longer operative time or need to open the fracture site, nor was there an indication that delay in surgical time resulted in a longer hospital stay or increase in unsatisfactory results. Similar observations were made by previous studies but none of them reported long term functional outcome of patients. Pin tract was seen in four cases which healed well with antibiotics and k wire

removal. Infection rate of 2-6.6% have been reported with percutaneous fixations.<sup>27,30,31</sup> Percutaneous pinning enabled us to immobilize the elbow in <90 degrees of flexion in PO period, facilitating venous outflow and significantly reducing the risk of compartment syndrome.<sup>32</sup> In addition, it prevents tenting of ulnar nerve.<sup>3,33</sup> Lect et al reported similar observation and suggested that vascular injury at the time of trauma is a bigger predisposing factor for development of compartment syndrome than delay in surgical intervention. Although modern pinning techniques have reduced the incidence of cubitus varus deformity, this continues to be most common complication following SC fracture of the humerus.<sup>4,15,34,35</sup> The cause of deformity is coronal rotation or tilting or a combination of both of the distal fragment.<sup>14,36,37</sup> In all patients, Bauman's angle was restored to within 4 degrees of an injured side. None had cubitus varus at a minimum follow-up of 1 year. This study agrees with other studies, which have reported that cubitus varus is caused by inadequate reduction.

There was no loss of reduction during follow-up. Both clinical and experimental data have shown that 2 crossed pins placed from medial and lateral condyles provide greater resistance to rotational displacement of fracture fragment.<sup>3,36-40</sup> The primary concern with cross pinning is the risk of injury to ulnar nerve by medial pin. The frequency of this complication in reported series ranges from 0 to 5%.

In this series 93.7% had excellent results. In five cases poor results were observed owing to the fact that these patients presented late and had undergone massage and repeated manipulations which added to initial soft tissue injury.

Strength of this study was that this study was done by a central hospital under supervision of one consultant and limitations of the study were sample size was small and follow-up period was short.

## CONCLUSION

Closed reduction and pinning are effective method despite delayed presentation. Strict anatomical reduction and stable fixation minimizes the risk of developing cubitus varus deformity.

*Funding: No funding sources*

*Conflict of interest: None declared*

*Ethical approval: The study was approved by the institutional ethics committee*

## REFERENCES

1. Saroff DA. Time to treatment: the question of beneficial surgical delays'. Bone Joint Surge Am. 2001;83(11):1755-6.

2. Jones KG. Percutaneous pin fixation of fractures of the lower end of the humerus. *Clin Orthop Relat Res*. 1967;50:53-69.
3. Swenson AL. The treatment of supracondylar fractures of the humerus by kirschner wire transfixion. *J Bone Joint Surg Am*. 1948;30(4):993-7.
4. D'Ambrosia RD. Supracondylar fractures of humerus-prevention of Cubitus varus. *J Bone Joint Surg Am*. 1972;54(1):60-6.
5. Dunlop J. Transcondylar fractures of the humerus in childhood. *J Bone Joint Surg Am*. 1939;21(1):59-73.
6. Gupta N, Kay RM, Leitch K, Femino JD, Tolo VT, Skaggs DL. Effect of surgical delay on perioperative complications and need for open reduction in supracondylar humerus fractures in children. *J Pediatr Orthop*. 2004;24(3):245-8.
7. Ong TG, Low BY. Supracondylar humeral fractures-a review of the outcome of treatment. *Singapore Med J*. 1996;37(5):508-11.
8. Palmer EE, Niemann KM, Vesely D, Armstrong JH. Supracondylar fracture of the humerus in children. *J Bone Joint Surg Am*. 1978;60(5):653-6.
9. Royce RO, Dulkowsky JP, Kasser JR, Rand FR. Neurologic complications after K-wire fixation of supracondylar humerus fractures in children. *J Pediatr Orthop*. 1991;11(2):191-4.
10. Alcott WH, Bowden BW, Miler PR. Displaced supracondylar fractures of humerus in children: long-term follow-up of 69 patients. *J Am Osteopath Assoc*. 1977;76(12):910-5.
11. Harris IE. Supracondylar fractures of the humerus in children. *Orthopedics*. 1992;15(7):811-7.
12. Jacob RL. Supracondylar fracture of the humerus in children. *IMJ III Med J*. 1967;132(5):696-701.
13. Paradis G, Lavallee P, Gagnon N. Supracondylar fractures of humerus in children. Technique and results of crossed percutaneous K-wire fixation. *Clin Orthop Relat Res*. 1993;297:231-7.
14. Iyengar SR, Hoffinger SA, Townsend DR. Early versus delayed reduction and pinning of type III displaced supracondylar fractures of the humerus in children: a comparative study. *J Orthop Trauma*. 1999;13(1):51-5.
15. Leet AI, Frisancho J, Ebrahimzadeh E. Delayed treatment of type 3 supracondylar humerus fractures in children. *J Pediatr Orthop*. 2002;22(2):203-7.
16. Mehlmann CT, Strub WM, Roy DR. The effect of surgical timing on the perioperative complications of treatment of supracondylar humeral fractures in children. *J Bone Joint Surg Am*. 2001;83(3):323-7.
17. Gartland JJ. Management of supracondylar fractures of the humerus in children. *Surg Gynecol Obstet*. 1959;109(2):145-54.
18. Wilkins KE. The management of severely displaced supra-condylar fractures of the humerus. *Tech Orthop*. 1989;4(3):5-24.
19. Green DW, Widmann RF, Frank JS, Gardner MJ. Low incidence of ulnar nerve injury with crossed pin placement for pediatric supracondylar humerus fractures using a mini-open technique. *J Orthop Trauma*. 2005;19(3):158-63.
20. Flynn JC, Mathews JG, Benoit RL. Blind pinning of displaced supracondylar fractures of the humerus in children: sixteen years' experience with long term follow-up. *J Bone Joint Surg Am*. 1974;56(2):263-72.
21. Aronson DD, Prager BI. Spracondylar fractures of the humerus in children. A modified technique for closed pinning. *Clin Orthop Relat Res*. 1987;(219):174-84.
22. Cramer KE, Devito DP, Green NE. Comparison of closed reduction and percutaneous pinning versus open reduction and percutaneous pinning in displaced supracondylar fractures of the humerus in children. *J Orthop Trauma*. 1992;6(4):407-12.
23. Kumar R, Kiran EK, Malhotra R, Bhan S. Surgical management of the severely displaced supracondylar fracture of the humerus in children. *Injury*. 2002;33(6):517-22.
24. Minkowitz B, Busch MT. Supracondylar humerus fractures. Current trends and controversies. *Orthop Clin North Am*. 1994;25(4):581-94.
25. Segal D. Pediatric orthopaedic emergencies. *Pediatr Clin North Am*. 1979;26(4):793-802.
26. Hart GM, Wilson DW, Arden GP. The operative management of the difficult supracondylar fracture of the humerus in the child. *Injury*. 1977;9(1):30-4.
27. Mehlman CT, Crawford AH, McMillion TL, Roy DR. Operative treatment of supracondylar fractures of the humerus in children: the cincinnati experience. *Acta Orthop Belg*. 1996;62 Suppl 1:41-50.
28. Peters CL, Scott SM, Stevens PM. Closed reduction and percutaneous pinning of displaced supracondylar humerus fractures in children: description of a new closed reduction technique for fractures with brachialis muscle entrapment. *J Orthop Trauma*. 1995;9(5):430-4.
29. Archibeck MJ, Scott SM, Peters CL. Brachialis muscle entrapment in displaced supracondylar humerus fractures: a technique of closed reduction and report of initial results. *J Pediatr Orthop*. 1997;17(3):298-302.
30. Boyd DW, Aronson DD. Supracondylar fractures of the humerus: a prospective study of percutaneous pinning. *J Pediatr Orthop*. 1992;12(6):789-94.
31. Cheng JC, Lam TP, Shen WY. Closed reduction and percutaneous pinning for type III displaced supracondylar fractures of the humerus in children. *J Orthop Trauma*. 1995;9(6):511-5.
32. Prietto CA. Supracondylar fractures of the humerus. A comparative study of Dunlop's traction versus percutaneous pinning. *J Bone Joint Surg Am*. 1979;61(3):425-8.
33. Rasool MN. Ulnar nerve injury after K-wire fixation of supracondylar humerus fractures in children. *J Pediatr Orthop*. 1998;18(5):686-90.
34. Gruber MA, Hudson OC. Supracondylar fractures of humerus in childhood. End-result study of open reduction. *J Bone Joint Surg Am*. 1964;46:1245-2.

35. Labelle H, Bunnell WP, Duhaime M, Poitras B. Cubitus varus deformity following supracondylar fractures of the humerus in children. *J Pediatr Orthop.* 1982;2(5):539-46.
36. Kallio PE, Foster BK, Paterson DC. Difficult supracondylar elbow fractures in children: analysis of percutaneous pinning technique. *J Pediatr Orthop.* 1992;12(1):11-5.
37. Sutton WR, Greene WB, Georgopoulos GA, Dameron JT. Displaced supracondylar humeral fractures in children. a comparison of results and costs in patients in patients treated by skeletal traction versus percutaneous pinning. *Clin Orthop Relat Res.* 1992;(278):81-7.
38. Davis RT, Gorczyca JT, Pugh K. Supracondylar humerus fractures in children. Comparison of operative treatment methods. *Clin Orthop Relat Res.* 2000;(376):49-55.
39. Haddad RJ, Saer JK, Riordan DC. Percutaneous pinning of displaced supracondylar fractures of elbow in children. *Clin Orthop Relat Res.* 1970;71:112-7.
40. Nacht JL, Ecker ML, Chung SM, Lotke PA, Das M. Supracondylar fractures of the humerus in children treated by closed reduction and percutaneous pinning. *Clin Orthop Relat Res.* 1983;177:203-9.

**Cite this article as:** Bhat JA, Wani AH, Din A, Dar R, Mir NA. Treatment of supra condylar fractures of humerus in children, a SKIMS medical college study. *Int J Res Orthop* 2020;6:996-1000.