

## Original Research Article

# Results of Sever- L' Episcopo procedure for obstetric brachial plexus palsy

Karthi Sundar V.<sup>1\*</sup>, Anil Kumar S.V.<sup>2</sup>

<sup>1</sup>Department of Orthopaedics, Saveetha Medical College Hospital, Thandalam, Tamil Nadu, India

<sup>2</sup>Department of Orthopaedics, Sri Devaraj Urs Medical College, Kolar, India

**Received:** 01 December 2016

**Accepted:** 17 December 2016

### \*Correspondence:

Dr. Karthi Sundar V,

E-mail: [karthisundarv@gmail.com](mailto:karthisundarv@gmail.com)

**Copyright:** © the author(s), publisher and licensee Medip Academy. This is an open-access article distributed under the terms of the Creative Commons Attribution Non-Commercial License, which permits unrestricted non-commercial use, distribution, and reproduction in any medium, provided the original work is properly cited.

### ABSTRACT

**Background:** The reported incidence of obstetric brachial plexus palsy (OBPP) varies from 0.3 to 2.5 per 1000 live births resulting in internal rotation deformity and weak abduction of the involved side shoulder.

**Methods:** To retrospectively analyse the functional results of the Sever- L' Episcopo procedure for OBPP with a minimum follow-up of 2 years to a maximum of 13 years using modified Mallet scoring system for shoulder.

**Results:** A significant improvement in the range of abduction and the restoration of external rotation of shoulder was achieved with Sever- L'Episcopo procedure.

**Conclusions:** The results of secondary reconstruction of a dysfunctional shoulder by means of a Lattismus dorsi & Teres major transfer as described by Sever- L'Episcopo is definitely beneficial. However this procedure will improve, but will not normalize, function. Apart from functional improvement this procedure corrects a deformity thereby easing the psycho-social stigma associated with it.

**Keywords:** Sever- L'Episcopo procedure, Obstetric brachial plexus palsy

### INTRODUCTION

Obstetric brachial plexus palsy (OBPP) was first described by Smellie in 1779.<sup>1</sup> Erb in 1874 was the first to describe the typical upper root palsy and localize the lesion to the junction of the C5 and C6 root with the upper trunk of the plexus in an adult.<sup>2</sup> The reported incidence of OBPP varies from 0.3 to 2.5 per 1000 live births.<sup>3</sup> The numbers are widely believed to decrease which is attributed to the extended indications for caesarean section and technical improvements in the field of Obstetric practice. Most of the patients spontaneously recover and those who don't have internal rotation deformity and weak abduction of the shoulder.

### METHODS

Thirty-one patients underwent the Sever-L' Episcopo procedure for OBPP between 1987 and 2004. All the

children were operated upon by the same surgeon in a single centre, the Institute of Orthopaedics and Accident Research Surgery. Among them twenty-eight of them turned up for the follow-up. There were 20 boys and 8 girls in our series. Their age ranged from 2 to 9 years at the time of surgery. Nineteen were affected in the right side and 9 in their left upper extremity. Our children included 8 whole arm type and the rest 20 were classical upper arm type of involvement.

The criteria of selection for the Sever- L'Episcopo procedure were:

- The absence of established bony changes in the Shoulder joint,
- A good range of motion, atleast passive and
- Age group between 2 and 8 years of age. One child of 9 years was operated because in that particular case there were no bony changes.

The average follow-up was 6 years and 6 months, range from 2 to 13 years. Eighty percent of the children had some form of physiotherapy in the form of passive stretching and electrical stimulation. All the patients were

assessed for the functional outcome as well as for the parent's satisfaction at the latest follow-up. The modified Mallet scoring<sup>4</sup> was done for all children as given in Table 1.

**Table 1: Modified Mallet scoring system for shoulder.**

Mallet Score	Functional status
1	Stiff shoulder or a flail arm.
2	Active abduction of 30 degrees or less, no active external rotation, and inability to place the hand behind the neck and the mid portion of the back. The hand is brought to mouth with arm in abduction (the trumpeter sign)
3	Active abduction of 30 to 90 degrees, active external rotation of 20 degrees or less, difficulty in placing the hand behind the neck and cephalad to sacrum. The hand can be brought to mouth with slight abduction (the trumpeter sign).
4	Active abduction of atleast 90 degrees, active external rotation of more than 20 degrees, and ability to place the hand behind neck and over thoracolumbar region of back without difficulty. The hand can be brought to mouth without abduction of arm.
5	Clinically normal Shoulder
<i>If one does not meet all five criteria for a grade, he is assigned a lower grade</i>	

Statistical analysis of our functional results was performed using student 't' distribution series. The 'P' values of difference in the pre-operative and the post-operative range of both abduction and external rotation were evaluated.

#### **Operative technique**

The patient is anaesthetized via endotracheal intubation. The patient is positioned supine with shoulder at the edge of the table and with a sand bag under it. The shoulder and arm are prepared and draped in such a manner that the arm is freely moved and the shoulder is exposed both anterior and posteriorly. Through a 3 cm skin incision along the anterior border of Deltoid, the incision is carried on through the superficial and deep fasciae to expose the Delto-pectoral groove. The cephalic vein, if encountered in the way is usually pushed medially or can be cut and ligated if it will provide a better exposure. The tendinous insertions of Teres major and Lattismus dorsi muscle are identified. The dissection is very blunt at this plane of dissection due to the proximity of the contents of the quadrangular space. The tendons of Teres major and Lattismus dorsi muscles, often found conjoined, are tagged and cut at its insertion to the medial lip and floor of the intertubercular sulcus of humerus respectively.<sup>5,6</sup>

Another 3 cm skin incision is made along the posterior border of the deltoid muscle and the incision is carried through the superficial and deep fasciae to expose the long head of triceps, which is strongly retracted laterally and the tagged tendon ends of teres major and lattismus dorsi muscles are retrieved to the posterior as the assistant pushes them through the anterior incision. The retrieved tendons are sutured to an osteoperiosteal flap in the posterolateral aspect of humerus as close to the short head of Triceps as possible. While the tendons are being sutured the shoulder is held in maximum external

rotation. Then both the anterior and the posterior wounds are closed in layers. Subcuticular skin closure is preferred to give a good cosmesis.<sup>5,6</sup>

Post operatively the upper limb is immobilized in a spica cast with the Shoulder in 90 degrees abduction, 90 degrees external rotation and the Elbow in 90 degrees flexion and full supination as shown in Figure 1.<sup>5,6</sup> A window is cut in the spica to enable the suture removal at the 10<sup>th</sup> postoperative day. Then the spica is removed after 3 weeks following the operation. The posterior part of the removed plaster shell is used as a night splint for a further period of 3 weeks. The Shoulder is put into active exercises and passive stretching as soon as the spica is removed. It is ensured that the child is strictly following the exercise and stretching regime.<sup>5,6</sup> Unlike in adults the physiotherapist has to be very patient. The patient is reviewed every week for the first 3 months. After 3 months the child is seen every month up to 1 year followed by once every year.

#### **RESULTS**

In our series of cases the average postoperative abduction was 114.75 degrees, as against pre-operative value of 65.25 degrees for the upper arm type of palsy as in Figure 2. We compared the results of upper and the whole arm types separately as the overall functional outcome varied widely because of the wrist and hand involvement in the whole arm types. The average abduction was improved from 15 degrees to 30 degrees in children with the whole arm type of palsy as given in Table 2.

The average internal rotation contracture in children with upper arm type was -7.75 degrees, which improved to 22.5 degrees after the surgery as in Figure 3. However in the children with whole arm type of the average postoperative rotation was 11.25 degrees against pre-

operative average internal rotation deformity of -15.625 degrees. The poor improvement in external rotation is attributed to few cases where the internal rotation

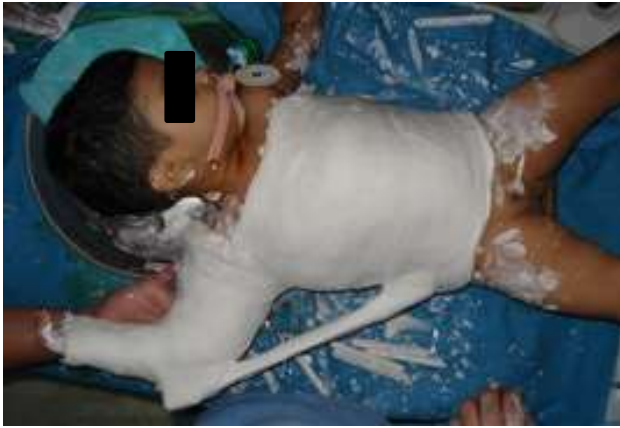deformity recurred in spite of a good immediate post-operative range.

**Table 2: Preoperative and postoperative abduction and external rotation.**

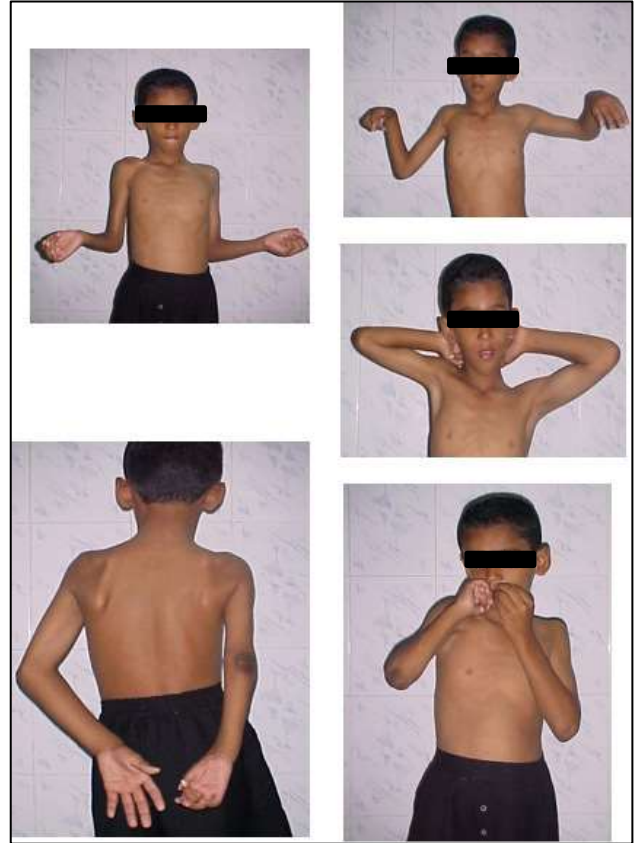
Type of palsy	Pre-op Abd.	Post-op Abd.	Pre-op Ext. rot.	Post-op Ext. rot.	Mallet score
<b>Upper arm</b>	65.25	114.75	-7.75	22.25	2.87
<b>Whole arm</b>	15	30	-15.625	11.25	1.5

One of our children had superficial wound infection, which completely healed after a prolonged course of antibiotics. The internal rotation contracture persisted in one of the children with whole arm type of palsy but still less severe compared with the pre-operative deformity.

All the children in our series were evaluated by modified Mallet scoring system. The average scores were 2.87 and 1.5 for upper and whole arm type respectively.



**Figure 1: Post op immobilization in spica cast.**



**Figure 3: 5 years follow up in whole arm type of OBPP.**



**Figure 2: 9 years follow up in upper arm type OBPP.**

Statistical analysis of our functional results was done using student ‘t’ distribution series. The ‘p’ values of difference in the pre-operative and the post-operative range of both abduction and external rotation were evaluated. The ‘p’ values were 0.00006 and 0.015 for the abduction and external rotation respectively for the children affected with upper arm type of involvement. These values are significant as they are well below 0.05. The ‘p’ values were not significant in the children affected with whole arm type.

**DISCUSSION**

The most common disability after OBPP is limitation of external rotation of the shoulder with weakness of abduction. The results of the L’ Episcopo procedure was very satisfactory not only in the functional aspect but it also had a huge impact in the residual deformity of the limb. Apart from the functional improvement the degree

of parent satisfaction was very high illustrated by the fact that 85% of them said that they would advise the surgical procedure for fellow patients. Also the mean improvement in the abduction and external rotation is comparable with various results of similar studies in literature.

One striking thing noted in the literature is that several authors had adopted some slight modifications from the classical Sever- L' Episcopo tendon transfer as like in Strecker's series where he has sutured the tendons of Lattismus dorsi and Teres major to the posterior fibres of the Deltoid hoping to improve the abduction as well apart from external rotation. Kirkos et al followed Merle d' Aubigne technique where he sutured the tendons to humeral stump of the divided tendon of pectoralis major instead of osteoperiosteal flap in the classical procedure.<sup>7</sup> Holfer et al in their series sutured the divided tendons of Lattismus dorsi and Teres major to the greater tuberosity of the Humerus. Still, there are only minor differences between the various modifications and all address the muscle imbalance between the internal and external rotators of Shoulder. We therefore believe that the long-term results of the surgical techniques can be compared.

Kirkos et al, in their series of similar transfers achieved a mean post-operative abduction of 77 degrees.<sup>7</sup> Their mean follow-up was 30 years. They have also demonstrated in their study that the overall improvement in the range of motion tends to decline over the longer period despite a better range in the short and medium term follow-ups. The mean external rotation in their patients was 10.5 degrees in the latest follow up. In the short and mid-term follow-ups it has been 36.5 and 16 degrees respectively. The mean external rotation in the Strecker et al series was 78 degrees and in that of Covey et al was 29 degrees.<sup>8,9</sup> Also it was very difficult to objectively compare the results in literature as each author has adopted some slight modifications from the classical Sever- L' Episcopo tendon transfer as like in Strecker's series where he has sutured the tendons of Lattismus dorsi and Teres major to the posterior fibres of the Deltoid hoping to improve the abduction as well apart from external rotation.

## CONCLUSION

The results of secondary reconstruction of a dysfunctional shoulder by means of a Lattismus dorsi & Teres major transfer as described by Sever- L'Episcopo is definitely beneficial. However this procedure will improve, but will not normalize, function. At the time of latest follow-up virtually most of the children in our series were living useful lives with near normal function. They had results comparable with any other series in

literature. Apart from functional improvement this procedure corrects a deformity thereby easing the psycho-social stigma associated with it, especially in our part of the country. This opinion is reiterated in our study, as parents of over 85% of the children in our series said that they would recommend this surgical procedure for fellow children affected by similar condition. Indications from the literature are that the incidence of OBPP is likely to rise or remain steady. Thus, Sever- L'Episcopo procedure definitely deserves a role in the armamentarium of the reconstructive surgeon treating patients with shoulder deformity & weakness in OBPP.

*Funding: No funding sources*

*Conflict of interest: None declared*

*Ethical approval: The study was approved by the institutional ethics committee*

## REFERENCES

1. Smellie W. A Collection of Cases and Observations in Midwifery (Volume 2). London: D Wilson; 1754; 446-448.
2. Erb W. Ueber eine eigenthümliche localisation von Lähmung gen implexus brachialis. Verhandlungen des naturhistorischen vereins von Heidelberg. 1874;2:130-7.
3. Birch R. Obstetric brachial plexus palsy. J Hand Surg. 2002;27:3-8.
4. Waters PM, Bae DS. Effect of tendon transfers and intra articular soft tissue balancing on glenohumeral development in brachial plexus birth palsy. J Am Academy Orthop Surg. 1997;5:205-14.
5. L' Episcopo J. Tendon transplant in obstetrical paralysis. Am J Surg. 1934;25:122.
6. L' Episcopo J. Restoration of muscle balance in treatment of obstetric paralysis; New York State. J Med. 1939;39:357.
7. Strecker WB, McAllister JW, Schoenecker PL, Dailey LA, Sever-L'Episcopo transfers in obstetrical palsy: a retrospective review of twenty cases. J Paed Orthop. 1990;19:442-4.
8. Covey DC, Riordan DC, Milstead ME, Albright AJ. Modification of L' Episcopo procedure for brachial plexus birth palsies. J Bone Joint Surg (British vol). 1992;74:897-901.
9. Kirkos JM, Kyrkos MJ, Kapetanous GA, Haritidis JH. Long term results of anterior release and tendon transfers around shoulder. J Bone Joint Surg Br. 2005;87:231-5.

**Cite this article as:** Karthi Sundar V, Anil Kumar SV. Results of Sever- L' Episcopo procedure for obstetric brachial plexus palsy. Int J Res Orthop 2017;3:50-3.