

Original Research Article

A comparative study of functional outcome of treatment of intra-articular fractures of distal end radius fixed with external fixator vs. volar plate

Gagandeep Mahi*, Lokesh Kumar Yogi

Department of Orthopaedics, Government Medical College and Hospital, Aurangabad, Maharashtra, India

Received: 02 June 2019

Revised: 24 July 2019

Accepted: 30 July 2019

***Correspondence:**

Dr. Gagandeep Mahi,

E-mail: drgaganmahi@gmail.com

Copyright: © the author(s), publisher and licensee Medip Academy. This is an open-access article distributed under the terms of the Creative Commons Attribution Non-Commercial License, which permits unrestricted non-commercial use, distribution, and reproduction in any medium, provided the original work is properly cited.

ABSTRACT

Background: Distal end radius fractures constitute 75% of all forearm fractures. Maintenance of the articular congruity is an ardent prerequisite for successful recovery, following distal end radius fractures. The available options include immobilization with plaster, external fixation, prefabricated splintage using ligamentotaxis, K-wire fixation, and open reduction internal fixation with various plates. The aim of the study was to analyze and compare the functional outcome and possible complications associated with fixation of two different surgical modalities: External fixator and Volar Plate in the treatment of intra-articular fractures of distal end radius.

Methods: A prospective comparative study was conducted in 26 patients who were admitted and operated between September 2017 to September 2018 and had fulfilled the inclusion /exclusion criteria. They were allocated into 2 groups-group A and B, 13 patients each for external fixator and open reduction and internal fixation with volar T plate, respectively.

Results: The results were assessed using the modified Green O' Brien Scoring. In Group-A of patients treated with External fixator we had 6 excellent, 3 good, 3 fair results and 1 poor results. Whereas in Group-B of ORIF with Volar plating we had 7 excellent, 3 good, 2 fair results and 1 poor results.

Conclusions: In our study, volar plate fixation showed superiority as it provides better long term functional outcome owing to more adequate restoration of radio-ulnar variance and distal end radius parameters.

Keywords: Distal end radius fracture, External fixation, Volar plate, Modified Green and O'Brien score

INTRODUCTION

The intra-articular radius fractures are mainly found in young patients with polytrauma or elderly patients with fragile osteoporotic bones. Along with the high comminution of the articular surface and metaphysis these fractures are commonly associated with ligament injuries.¹ Distal end radius fractures represent approximately 16 % of all fractures.²

A vast array of surgical techniques have been advocated but open reduction and internal fixation with a volar plate

system is currently the preferred treatment of distal radius fracture resulting in good reduction and providing immediate stability. An added advantage over other modalities being that the patients can start early range of motions, potentially reducing wrist stiffness. The stability is achieved by compression of plate to bone or buttressing the volarly displaced fragment(s) by bicortical screws. In many cases, compression of plate to bone is unnecessary, thus preserving the periosteal blood supply.³

The very ligaments, retinaculae, tendons, and periosteum around the fracture, which are the surgical barriers for open reduction of the fracture fragments, at the same time help achieve reduction of the fracture by ligamentotaxis.⁴ The older days treatment with plaster of Paris cast was done. It immobilizes the wrist in flexed position, as opposed to the normal functional position of the hand. This results in inadequate rehabilitation in most of the cases.

The main aim of this study is to evaluate the results obtained by the treatment of distal end radius fractures by external fixation; and open reduction and internal fixation with volar plate in terms restoration of anatomy of distal end radius (radial length, palmar tilt, and radial angulation) and to know the effectiveness in allowing early functionality and prevention of deformity and disability due to malunion.

METHODS

This study was performed between September 2017 to September 2018 on patients with distal radius fractures who came to GMCH, Aurangabad, Maharashtra. The patient criteria for inclusion in this study were age >20

years with closed intra-articular distal end radius fracture. Patients with bilateral distal radius fractures, open fractures of distal radius and associated systemic injuries were excluded from the study.

The patients were randomized into two groups. The external fixation technique was chosen for 1st and volar plates were chosen for 2nd group. All surgical procedures were performed in our institute using standard protocols under general or regional anesthesia. A manual tourniquet was used in all cases in order to provide bloodless field during surgery. The general external fixation technique used two 2.5 mm Schanz pins in the second metacarpal and two 3.5 mm pins in the radius proximal to the fracture. The pins were interconnected and tightened with solid connecting rod and link joints.

Reduction was achieved via manual traction and closed reduction method in all cases. Sterile betadine dressing of the pin tract site was performed. A below-elbow plaster of Paris slab was applied in all patients for 1 week. The external fixator was removed in all patients after 8 weeks. K wires were used intraoperatively as and when needed to achieve more stability of fracture fragments.

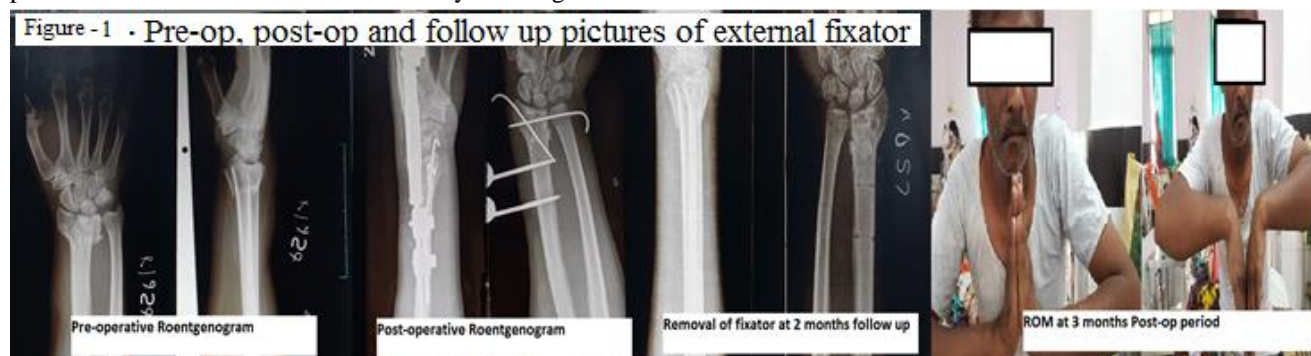


Figure 1: Preoperative, postoperative, post implant removal and follow-up pictures of a group A patient.

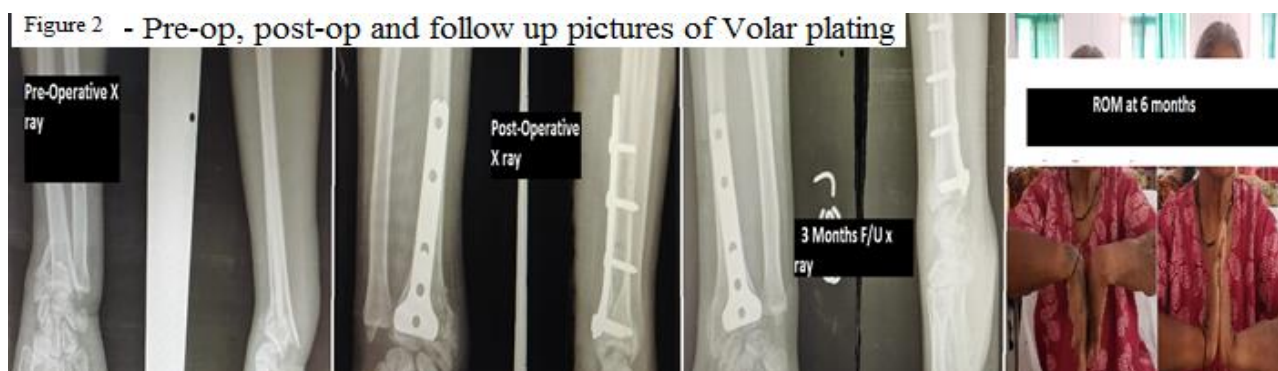


Figure 2: Preoperative, postoperative and follow-up pictures of a group B patient.

The patients of both groups were discharged 2 days after surgery after checking the suture line under proper antibiotic coverage (3rd generation cephalosporin for 3 days) and active finger movements were advised. The patients were recalled for suture removal and to see the

reduction in fracture radiologically after 10 days. Acceptable criteria for fracture reduction were radial inclination of >15°, radial shortening of <5 mm compared to the contralateral side, sagittal tilt between 15° dorsal and 20° volar tilt and intra-articular step-off of <2 mm.

All the patients were followed at 2 weeks, 4 weeks and 24 weeks for the outcome parameters after surgery and assessed for pain, grip strength, wrist range of motion (ROM) and activity, and scored according to the Green and O'Brien scoring system. Scores <65 were considered poor, and scores between 65 and 79, between 80 and 89, and between 90 and 100 were considered fair, good and excellent, respectively (Figures 1 and 2).

RESULTS

26 patients (16 males and 10 females) with intra-articular distal radius fractures were recruited into the study. They were allocated into two groups 13 patients each for external fixator and open reduction & internal fixation with volar T plate. External fixator done in 13 patients in which 9 were males and 4 were females. Volar T plate done in 13 patients in which 7 were males and 6 females (Table 1).

Table 1: Sex wise distribution of patients as per procedure done.

Procedure done	No. of patients	%
External fixator (n=13)		
Male	9	50
Female	4	
Volar plate (n=13)		
Male	7	50
Female	6	

Age-wise distribution of patients: From age 21 to 80 years divided into six groups, here age groups 31-40 years and 51-60 years were the two major groups who presented with distal end radius intra-articular fractures. (Table 2 and 3).

Table 2: Age wise distribution of patients

Age groups (years)	No of patients	%
21-30	4	15.38
31-40	7	26.92
41-50	5	19.23
51-60	7	26.92
61-70	2	7.69
71-80	1	3.84

Table 4: Modified Green O'Brien score in group A and group B.

Study group	Number of patients in group	Pain (mean)	Functional status (mean)	ROM (mean)	Grips strength (mean)	Avg. score (mean)
External fixator (Group A)	13	21.92	21.15	20.38	20.77	84.23
Volar plating (Group B)	13	21.15	21.53	21.15	22.69	86.53

Mean surgery time was 38.46 minutes (range 30-45 minutes) in the external fixation group and 60.76 minutes (range 50-80 minutes) in the volar plate fixation group. Reduction in fracture was achieved in all patients in both groups and no patient required revision surgery.

Follow-up data could be obtained for 26 patients after 6 months. Clinical scoring was done based on modified Green O'Brien score. Modified Green O'Brien Scoring system which is an examiner rated assessment based on pain, functional status, range of motion, and grip strength.

Each of the 4 parameters is given a weighting of 25 points, giving a total score of 100. With excellent being 90 to 100, good 80 to 89, fair 65 to 79, and poor <65 (Table 4).

Table 3: Mode of injuries.

Mode of injury	No. of patients	%
RTA (n=15)		
Male	14*	57.70
Female	1	
Fall (n=11)		
Male	2	42.30
Female	9**	

*Mode of injury in males was found to be RTA in 87.50% whereas in females RTAs amounted to only 10 % of the cases.

**Mode of injury in males as fall was only seen in 12.50% whereas in female fall as mode of injury amounted to a whopping 90 % of the cases.

In Group A of patients treated with external fixator we had 6 (46.15%) excellent, 3 (23.07%) good, 3 (23.07%) fair results and 1 (7.69%) poor results. whereas in Group-B of ORIF with Volar plating we had 7 (53.84%) excellent, 3 (23.07%) good, 2 (15.38%) fair results and 1 (7.69%) poor results.

Complications

Wrist joint arthritis was major post-operative complication noted following the surgery with two cases noted in external fixator group and one case noted in volar plating group. Extensor pollicis longus tendon irritation described as grating sensation while doing movements of thumb was noted in one patient amongst the volar plating group (Table 5).

Table 5: Complications related to group A and group B.

Procedure	Complications	Number
Group A	Wrist joint arthritis	2
	Pin track infection	0
	Non-union	0
	EPL tendon irritation	0
Group B	Wrist joint arthritis	1
	Infection	0
	Non-union	0
	EPL tendon irritation	1

DISCUSSION

Different types of fractures occur due to the anatomy of the distal radius and the effects of multitude of forces in different directions. More than often, it's not feasible to have a successful outcome using a single line of approach and materials for different types of fractures. While mechanical parameters are important in selection of implants, the strategic placement of the selected materials appear to be more important than the characteristics of these materials, more so in intra-articular fractures.⁵

The best treatment option for different types of fractures can be determined by comparing different methods. External fixation is versatile in managing both intra- and extra-articular fractures with fairly acceptable functional results. Reasons for using external fixation include the continuity of reduction under fluoroscopic control, improved reduction by ligamentotaxis and the ability to protect the reduction until healing occurs. The other advantages of external fixation are the relative ease of application, minimal surgical exposure, and reduced surgical trauma.⁶

To limit complications when external fixation is used, limiting the duration of fixation is an option. Three prospective studies meeting the inclusion criteria were studied. Collectively, these studies do not comment upon a length of immobilization in a fixator; thus, we chose not to define a specific duration in the recommendation. The first study demonstrated no significant difference in groups treated with external fixation for 5 weeks, compared with 3 weeks of external fixation and 2 weeks of additional casting.⁷

The results were reported using a non-validated patient outcome score; hence, no clear effect could be demonstrated by the early discontinuation of the external fixator. Two additional studies that used a non-validated patient outcome score showed a statistically significant association between poorer outcomes with prolonged external fixation.^{8,9}

The locking plate minimizes the compressive forces exerted on the bone to achieve stability, which may prevent periosteal compression and associated

impairment of blood supply. In unstable intra-articular fractures, meticulous re-establishment of inter-articular integrity of the wrist and maintaining the radial length are often not possible with closed methods. In a meta-analysis study IF reduced the incidence of total surgical complications and pin-track infections after one year of follow-up. The number of complications for the palmar locking-plate fixation ranged from 0% to 10%.¹⁰ Schmelzer-Schmied also considered it was better than that of external fixation.¹¹

The incidence of extensor pollicis longus rupture was higher after IF, possibly because the hardware lies in direct contact with the extensor tendons. Dobretz reported this complication in up to 12% of cases when using the palmar locking plate.¹²

Furthermore, three studies with moderate strength of recommendation were included in this discussion.¹³⁻¹⁵ Each study investigated different surgical treatment methods: volar plate, trans styloid fixation, or external fixation. In the two internal fixation studies, therapy was started approximately at 1 week; in the external fixation study, mobilization was begun at 3 weeks. In two studies, the control group was either casted or immobilized with a fixator. In the volar plating study, the control group patients were fitted with a thermoplastic splint that they were instructed to remove for showering; therefore, these patients are not a reliable control group. The outcome measures used were pain and function (DASH) and/or complications. None of the outcomes was significantly different between early and late motion. These data support the recommendation that patients do not need to begin early wrist motion after stable fracture fixation.

A prospective study of 55 patients evaluating the rate of functional improvement after treatment with volar locking plates demonstrated similar rates of recovery between elderly patients and younger patients.¹⁶ A retrospective analysis of 24 distal radius fractures in patients treated with a volar fixed-angle plate showed good results with no significant loss of reduction.¹⁷

Ginn et al published results from a surgical technique in which the plate is applied in a minimally invasive fashion.¹⁸ Using this technique, Hanel et al reported superior results in a study comprised of 62 patients with 41 of them returning to their pre-accident level of employment.¹⁹ Richards et al evaluated bridge plating in elderly patients and demonstrated equally promising results.²⁰

In the present study, 69.22 % of patients treated with external fixation and 76.91 % of patients treated with volar plating had an excellent or good result. In conclusion, in our study, after fairly acceptable radiological reduction was achieved in all patients, volar plating has slight superiority over external fixator techniques at final outcome at 6 months follow-up. Patients aged >50 years had better results at the end of 6

months when treated with external fixation. Therefore, we recommend volar plating in treating displaced intra-articular distal end radius fractures.

CONCLUSION

Both External fixator and volar plate fixation provide good functional outcomes for distal end radius intra-articular fractures. Although external fixator provides early restoration of wrist function and wrist flexion, in our study volar plate fixation provides better restoration of radio-ulnar variance, better wrist supination & pronation and has shown superiority over external fixator techniques in terms of final outcome at 6 months follow-up.

Funding: No funding sources

Conflict of interest: None declared

Ethical approval: The study was approved by the institutional ethics committee

REFERENCES

1. Forward DP, Lindau TR, Melsom DS Intercarpal ligament injuries associated with fractures of the distal part of the radius. *J Bone Joint Surg Am.* 2007;89:2334-40.
2. Leung F, Tu YK, Chew WY, Chow SP. Comparison of external and percutaneous pin fixation with plate fixation for intra-articular distal radial fractures. A randomized study. *J Bone Joint Surg Am.* 2008;90(1):16-22.
3. Richards RR. Fractures of the shafts of the radius and ulna. In: Bucholz RW, Heckman JD, editors. *Rockwood and Green's fractures in adults.* 5th edition. Philadelphia, USA: Lippincott Williams and Wilkins; 2001: 869-917.
4. Simic PM, Weiland AJ. Fractures of the distal aspect of the radius: Changes in treatment over the past two decades. *Instr Course Lect.* 2003;52:185-95.
5. Gradl G, Gradl G, Wendt M, Mittlmeier T, Kundt G, Jupiter JB. Non-bridging external fixation employing multiplanar K-wires versus volar locked plating for dorsally displaced fractures of the distal radius. *Arch Orthop Trauma Surg.* 2013;133(5):595-602.
6. Kapoor H, Agarwal A, Dhaon BK. Displaced intra-articular fractures of distal radius: a comparative evaluation of results following closed reduction, external fixation and open reduction with internal fixation. *Injury.* 2000;31:75-9.
7. Haddad M, Jacoby B, Snerum L, Hede J, Overgaard S. External fixation of distal radial fractures: 3 or 5 weeks of external fixation. *Int Orthop.* 2000;24:224-6.
8. Kaempffe FA, Wheeler DR, Peimer CA, Hvisdak KS, Ceravolo J, Senall J: Severe fractures of the distal radius: Effect of amount and duration of external fixator distraction on outcome. *J Hand Surg Am.* 1993;18:33-41.
9. Kaempffe FA, Walker KM. External fixation for distal radius fractures: Effect of distraction on outcome. *Clin Orthop Relat Res.* 2000;380:220-25.
10. McQueen MM, Hajducka C, Court-Brown CM. Redisplaced unstable fractures of the distal radius: a prospective randomized comparison of four methods of treatment. *J Bone Joint Surg Br* 1996;78:404-9.
11. Schmelzer-Schmied N, Widloch P, Martini AK, Daecke W. Comparison of external fixation, locking and non-locking palmar plating for unstable distal radius fractures in the elderly. *Int Orthop.* 2009;33:773-8.
12. Dobretz H, Kutscha-Lissberg E. Osteosynthesis of distal radial fractures with a volar locking screw plate system. *Int Orthop.* 2003;27:1-6.
13. McQueen MM, Hajducka C, Court-Brown CM: Redisplaced unstable fractures of the distal radius: A prospective randomised comparison of four methods of treatment. *J Bone Joint Surg Br* 1996;78:404-9.
14. Allain J, le Guilloux P, Le Mouël S, Goutallier D: Trans-styloid fixation of fractures of the distal radius: A prospective randomized comparison between 6- and 1-week post-operative immobilization in 60 fractures. *Acta Orthop Scand.* 1999;70:119-23.
15. Lozano-Calderón SA, Souer S, Mudgal C, Jupiter JB, Ring D: Wrist mobilization following volar plate fixation of fractures of the distal part of the radius. *J Bone Joint Surg Am.* 2008;90:1297-304.
16. Chung KC, Squitieri L, Kim HM. Comparative outcomes study using the volar locking plating system for distal radius fractures in both young adults and adults older than 60 years. *J Hand Surg Am.* 2008;33:809-19.
17. Orbay JL, Fernandez DL. Volar fixed-angle plate fixation for unstable distal radius fractures in the elderly patient. *J Hand Surg Am.* 2004;29:96-102.
18. Ginn TA, Ruch DS, Yang CC, Hanel DP. Use of a distraction plate for distal radial fractures with metaphyseal and diaphyseal comminution. *Surgical technique. J Bone Joint Surg Am.* 2006;88(1):29-36.
19. Hanel DP, Lu TS, Weil WM. Bridge plating of distal radius fractures: the Harborview method. *Clin Orthop Relat Res.* 2006;445:91-9.
20. Richard MJ, Katolik LI, Hanel DP, Wartinbee DA, Ruch DS. Distraction plating for the treatment of highly comminuted distal radius fractures in elderly patients. *J Hand Surg Am.* 2012;37:948-56.

Cite this article as: Mahi G, Yogi. A comparative study of functional outcome of treatment of intra-articular fractures of distal end radius fixed with external fixator vs. volar plate. *Int J Res Orthop* 2019;5:949-53.