

## Original Research Article

# Chronic insertional achilles tendon ruptures treated by suture anchor repair and augmentation with flexor hallucis longus tendon transfer

Athar Ahemad M. A.\*, Naser Mohd Abdul, Mushir Ali Syed

Department of Orthopaedics, Indian Institute of Medical Sciences and Research, Warudi, Jalna, Maharashtra, India

**Received:** 15 January 2018

**Revised:** 01 February 2018

**Accepted:** 02 February 2018

### \*Correspondence:

Dr. Athar Ahemad M. A.,

E-mail: [dratharahmed@gmail.com](mailto:dratharahmed@gmail.com)

**Copyright:** © the author(s), publisher and licensee Medip Academy. This is an open-access article distributed under the terms of the Creative Commons Attribution Non-Commercial License, which permits unrestricted non-commercial use, distribution, and reproduction in any medium, provided the original work is properly cited.

## ABSTRACT

**Background:** Different surgical procedures have been used for treatment of chronic ruptures of the Achilles tendon with varying results. This study assesses the functional outcomes and complications of chronic insertional tears of Achilles tendon.

**Methods:** 10 patients with chronic ruptures of the Achilles tendon were followed for a mean period of 10.3 months. Only ruptures at or near (within 1 cm) insertion were included. They were treated by direct repair of tendon to calcaneum by suture anchor. Flexor hallucis longus (FHL) tendon transfer fixed to calcaneal tunnel with an interference screw was used to augment the repair.

**Results:** Outcome was assessed by AOFAS Ankle-Hindfoot (AHS) score. The mean preoperative score of 41.2 improved to 85.4 at final follow-up out of a total 100 points. We achieved excellent results in 80% and good outcome in 20% cases. No re-ruptures were noted.

**Conclusions:** In insertional chronic ruptures of Achilles tendon, FHL transfer to calcaneum with interference screw fixation and repair of Achilles tendon with suture anchor is a reliable technique with good outcome and is recommended.

**Keywords:** Achilles tendon, Flexor hallucis longus, Tendon transfer, Suture anchor

## INTRODUCTION

Achilles tendon is the most commonly ruptured tendon in the body.<sup>1</sup> A rupture that is diagnosed 4 to 6 weeks after injury is considered to be chronic.<sup>2</sup> If left untreated, the tendon heals elongated, making the patient unable to push off. Activities like jogging, walking fast or climbing and descending stairs are restricted. Posterior heel pain or functional impairment can be indications for delayed reconstruction. Conservative methods may be ineffective in such cases due to gap formed between retractile tendon stumps.

A variety of surgeries are described for reconstruction of chronic Achilles tendon rupture like V-Y plasty or

gastrocnemius-soleus fascia turn down graft and local tendon transfers (FHL, FDL, PB) to bridge the gap.<sup>3</sup> Flexor hallucis longus (FHL) transfer was first done by Hansen in 1991 to augment the Achilles tendon defect.<sup>4</sup>

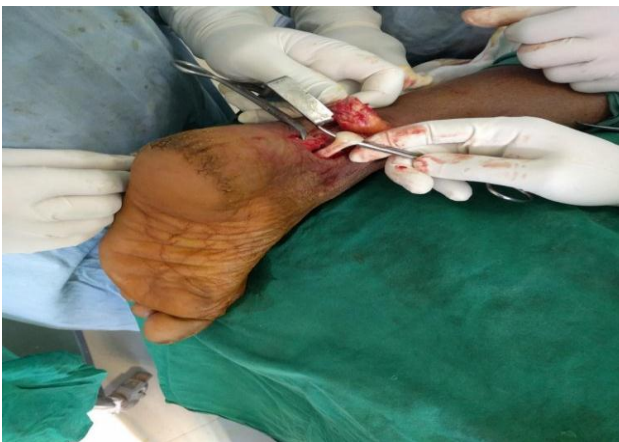Here, we present a series of 10 patients having chronic insertional ruptures of Achilles tendon operated in our institution over a period of 2 years. They were treated by direct repair of Achilles tendon to calcaneum using suture anchors. As augmentation, FHL was harvested through same incision and fixed into a bone tunnel in calcaneum with an interference screw.<sup>5</sup> This study aims to assess the postoperative outcome and complications associated with this procedure and return of patient to pre-injury level of activity. As a side note, any disturbance of hallux function due to FHL transfer was also investigated.

## METHODS

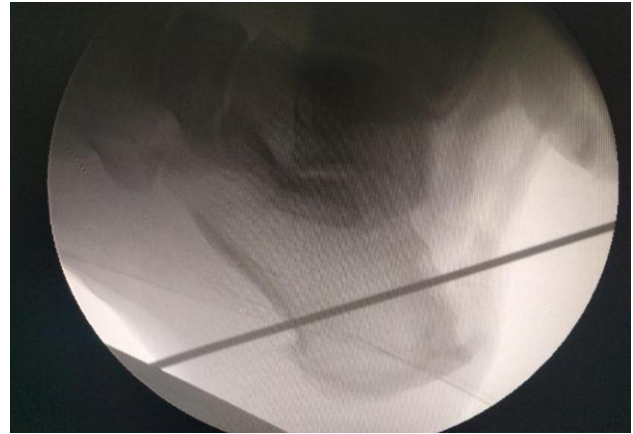This is a study of 10 patients consecutively operated at our institution from Jan 2015 to Feb 2017. Criteria used for inclusion of patients were restricted to: a) chronic Achilles tendon ruptures diagnosed at least 4 weeks after trauma; b) insertional ruptures at bone tendon junction or within 1 cm of insertion; c) Achilles tendon ruptures which were treated by repair with suture anchors and FHL tendon transfer fixed with interference screws. All patients were diagnosed by standard clinical examination techniques.

### Surgical technique

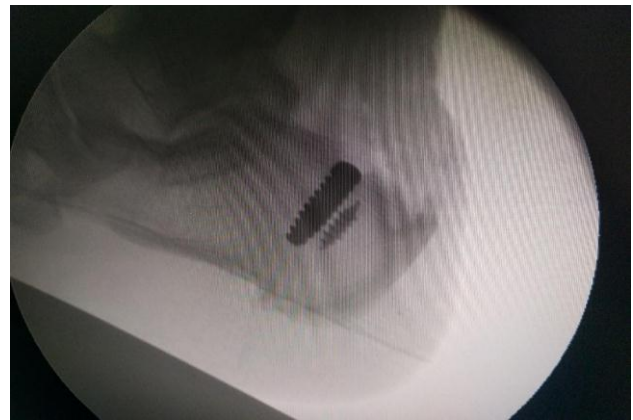The Achilles tendon was exposed by a posteromedial incision extending upto 1 cm below the calcaneal insertion. Paratenon was carefully incised and sural nerve was identified and retracted. Tendon ends were debrided to remove calcifications. If there was a prominent posteromedial calcaneal tuberosity, it was excised. FHL was dissected out protecting the neurovascular bundle (Figure 1). The FHL tendon was pulled up as far as possible with simultaneous plantar flexion of ankle and first toe. It was transected at the level of calcaneum. A bone tunnel was drilled in the calcaneum starting at the superior calcaneal tuberosity and going in an anteroinferior direction and exiting at the plantar aspect of heel (Figure 2). A Krackow stitch is taken at the end of FHL tendon. The tendon is pulled into the calcaneal tunnel and securely fixed with an interference screw of same size as the tunnel diameter. Then a suture anchor is deployed at the insertion site of Achilles tendon (Figure 3). Suture threads of the anchor are passed through proximal end of Achilles tendon and tied. The Achilles tendon repair was not in excessive tension (Figure 4). If a large gap was present at rupture site, it was dealt with by pie crusting of the gastrosoleus fascia. This was enough to bring the Achilles tendon down to the calcaneal insertion. Paratenon is meticulously closed over the repair followed by skin closure.



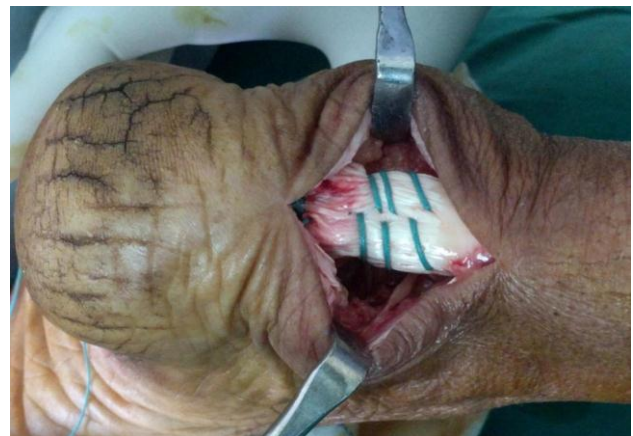**Figure 1: Photo showing the Achilles tendon tear and the FHL tendon pulled out which is flexing the great toe.**



**Figure 2: Image showing the beath pin passed in the intended direction of calcaneal tunnel.**



**Figure 3: IITV image showing an interference screw in the calcaneum to fix the FHL tendon. Behind this, suture anchor for Achilles tendon repair can be seen.**



**Fig. 4: Operative photograph of Achilles tendon repair with suture anchor. Normal heel cord contour is restored.**

The patients were evaluated by American Orthopaedic Foot Ankle Society (AOFAS) Ankle-Hindfoot scale.<sup>6</sup> It is a 100 point score with 40 points for pain, 50 points for function and 10 for alignment. Functional evaluation by

AOFAS ankle-hind foot scale was done in i. Pre-injury status by evaluating contralateral normal side; ii) Preoperative status; iii) Postoperative state at maximum followup. Overall result was graded as excellent if return of function at final followup was >85% of pre-injury score; good if 70 to <85% of pre-injury level; moderate if 55 to <70 and poor if score was <55% of pre-injury score.

In addition, the time of single leg heel raise patient could sustain at latest followup was measured.

## RESULTS

**Table 1: Age and gender wise distribution of cases.**

| Particulars           | No. of cases |
|-----------------------|--------------|
| <b>Gender</b>         |              |
| Male                  | 6            |
| Female                | 4            |
| <b>Age (in years)</b> |              |
| 41 to 50              | 2            |
| 51 to 60              | 7            |
| 61 to 70              | 1            |

There were 10 patients with 10 chronic insertional Achilles tendon ruptures. The left Achilles tendon was ruptured in 6 patients and right in 4. The mean age of this patient group was 54.7 years and it included 6 males and 4 females (Table 1).

**Table 2: Distribution of patients based on the injury-surgery interval in weeks.**

| Injury-surgery interval | No. of cases | Percentage (%) |
|-------------------------|--------------|----------------|
| <b>4 weeks</b>          | 2            | 20             |
| <b>5 weeks</b>          | 2            | 20             |
| <b>6 weeks</b>          | 3            | 30             |
| <b>8 weeks</b>          | 1            | 10             |
| <b>9 weeks</b>          | 1            | 10             |
| <b>10 weeks</b>         | 1            | 10             |

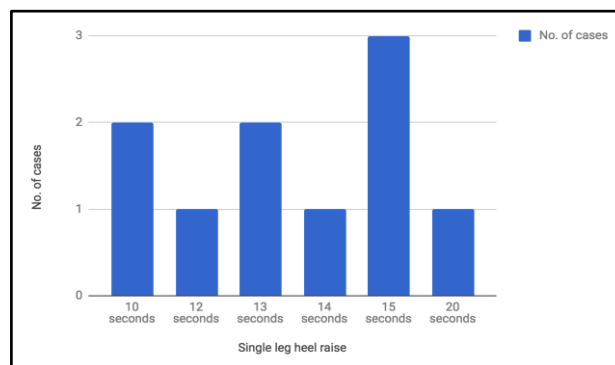
The average time interval from trauma to surgery was 6.3 weeks suggesting the chronicity of injury at the time of surgery (Table 2).

No patient was lost to followup. The mean length of followup was 10.3 months (range 9-13 months).

At the last followup, the patients were able to do single leg heel raise for an average 13.7 seconds indicating a good return of push-off power during walking (Figure 5).

In the preoperative period, the mean AHS score was 41.2 out of 100 points showing that patients had considerable pain and disability due to Achilles tendon tear. The preinjury AHS score (mean=91.8) was calculated from the contralateral normal side with the assumption that both the sides were similar prior to injury. The mean

postoperative AHS score was 85.4 at final followup. There was statistically significant improvement from preop to postop score ( $p < 0.001$ ). A paired t test was used to compare the two scores. ( $t = 14.40$ ,  $df = 9$ , std. error of difference = 3.069) (Table 3).



**Figure 5: Distribution of patients based on single leg heel raise in seconds.**

**Table 3: Mean AHS score.**

| Phase                 | Mean AHS score | SD    | P value                             |
|-----------------------|----------------|-------|-------------------------------------|
| <b>Pre-operative</b>  | 41.2           | 9.37  | $p < 0.001$<br>(highly significant) |
| <b>Post-operative</b> | 85.4           | 5.146 |                                     |

**Table 4: Distribution of patients based on the outcome.**

| Result           | No. of cases | Percentage (%) |
|------------------|--------------|----------------|
| <b>Excellent</b> | 8            | 80             |
| <b>Good</b>      | 2            | 20             |

As far as overall outcome is concerned, 8 patients (80%) had excellent and 2 had good (20%) result. This means that all patients regained preinjury level of daily function in our study (Table 4).

None of the patients complained (of their own accord) of loss of power in the hallux and this did not hinder in their daily activities. Nevertheless, all had absent active plantar flexion on examination of great toe.

### Complications

There were no major complications. One patient had delayed wound healing and another had a superficial infection which resolved with change of antibiotics. One other patient had a hypertrophic scar.

## DISCUSSION

Our study has demonstrated good to excellent functional outcome in all patients. Similar good results have been published by Hartog and Wegrzyn and Yeoman et al

which also used FHL tendon transfer.<sup>7-9</sup> Mulier et al have shown poorer results and higher infection rates with gastrocnemius turn down flaps as compared to tendon transfer techniques.<sup>10</sup>

All the ruptures in our study were insertional i.e. at the calcaneal insertion or within 1 cm of insertion leading to a very short distal stump. Hence, it necessitated a direct repair of proximal segment of Achilles tendon to the calcaneum via titanium suture anchor. In this situation, bone-tendon healing occurs which is slow and unreliable.<sup>11</sup> So, the FHL transfer also works as a backup strategy in case of failure of suture anchor repair of Achilles tendon.

As the fixation of FHL tendon into the calcaneal tunnel with an interference screw is very secure, the patient can start weight bearing mobilization after 2 weeks only. This is reflected in our good postoperative AHS scores. We did not immobilize the ankle in excessive plantar flexion but only in gravity equinus equal to the opposite side.<sup>12</sup>

It is important to meticulously repair the paratenon with polyglactin 2-0 since it facilitates the healing response and avoids wound healing problems. No repeat rupture was seen in any of the cases. In chronic rupture reconstruction, a 3.7% re-rupture rate is recorded.<sup>13</sup> FHL tendon transfer probably protects the Achilles tendon repair from undue stress.

FHL is the strongest plantar flexor of the ankle after triceps surae.<sup>14</sup> Its line of contraction more closely resembles the Achilles tendon. Both fire in phase during stance phase of the gait. So, tendon re-education is not required in the postoperative period. Moreover, the FHL tendon is in anatomical proximity to the Achilles tendon, so it can be harvested through the same incision. Peroneus brevis transfer can disturb the balance between ankle invertors and evertors. Thus, it is an inferior substitute.

FHL tendon can also be harvested at master knot of Henry or from the great toe. In this study, the use of interference screw fixation requires a very short length of tendon making redundant the need for a second incision.

A potential problem with FHL transfer is loss of active plantar flexion of first toe which was observed in all of our cases. However, patients did not complain about any functional impairment in daily activities due to the same.<sup>15</sup>

Good recovery of plantar flexion strength was observed. All the patients were able to stand tip toe and maintain single leg heel raise for an average 13.7 seconds. FHL augmentation adds substantially to the overall strength of the reconstruction.

Although it is study of a small number of patients (10) but chronic insertional tears of Achilles tendon are

relatively uncommon and our inclusion criteria are narrow.

There were no major complications in our study and reliable good outcomes were found in all patients with successful rehabilitation to pre-injury level of activity.

*Funding: No funding sources*

*Conflict of interest: None declared*

*Ethical approval: Not required*

## REFERENCES

1. Maffulli N. Rupture of the Achilles tendon. *J Bone Joint Surg Am.* 1999;81:1019-36.
2. Maffulli N, Ajis A, Longo UG, Denaro V. Chronic rupture of tendo Achilles. *Foot Ankle Clin North Am.* 2007;12:583-96.
3. Abraham E, Pankovich AM. Neglected rupture of the Achilles tendon: treatment by V-Y tendinous flap. *J Bone Joint Surg Am.* 1975;57:253-5.
4. Hansen ST. Trauma to the heel cord. In: Jahss MH, ed. *Disorders of the foot and ankle*, 2<sup>nd</sup> edn. W.B. Saunders, Philadelphia, 1991: 2357.
5. DeCarbo WT, Hyer CF. Interference screw fixation for flexor hallucis longus tendon transfer for chronic achillectendonopathy. *J Foot Ankle Surg.* 2008;47(1):69-72.
6. Kitaoka HB, Alexander IJ, Adelaar RS, Nunley JA, Myerson MS, Sanders M. Clinical rating systems for the ankle, hindfoot, midfoot, hallux and lesser toes. *Foot Ankle.* 1994;15:349-53.
7. Den Hartog BD. Surgical Strategies: delayed diagnosis or neglected Achilles tendon ruptures. *Foot Ankle Int.* 2008;29:456-63.
8. Wegrzyn J, Luciani JF, Phillipot R, Brunet-Guedj E, Moyon B, Besse JL. Chronic Achilles Tendon rupture reconstruction using a modified flexor hallucis longus transfer. *Int Orthop.* 2010;34:1187-92.
9. Yeoman T, Brown MJC, Pillai A. Early postoperative results of neglected tendo-Achilles rupture reconstruction using short flexor hallucis longus tendon transfer: A prospective review. *The Foot.* 2012;22:219-23.
10. Mulier T, Pienaar H, Dereymaeker G, Reynders P, Broos P. The management of chronic Achilles tendon ruptures: gastrocnemius turn down flap with or without flexor hallucis longus transfer. *Foot Ankle Surg.* 2003;9(3):151-6.
11. Luis P, Zhang P, Chan K, Qin L. Biology and augmentation of tendon- bone insertion repair. *J Orthop Surg Res.* 2010;21(5):59.
12. El-Tantawy A, Azzam W. FHL tendon transfer in the reconstruction of extensive insertional Achilles tendinopathy in elderly: an improved technique. *Eur J Orthop Surg Traumatol.* 2015;25:583-90.
13. van der Linden-van der Zwang HMJ, Nelissen RGH, Sienten JB. Results of surgical vs non-

surgical treatment of Achilles tendon rupture. *Int Orthop.* 2004;28:370-3.

14. Silver RL, dela Garza J, Rang M. The myth of muscle balance. A study of relative strengths and excursions of normal muscles about the foot and ankle. *J Bone Joint Surg Br.* 1985;67:432-7.
15. Hahn F, Maiwald C, Horstmann T, Vienne P. Changes in plantar pressure distribution after

Achilles tendon augmentation with flexor hallucis longus transfer. *Clin Biomech.* 2008;23(1):109-16.

**Cite this article as:** Athar AMA, Abdul NM, Syed MA. Chronic insertional achilles tendon ruptures treated by suture anchor repair and augmentation with flexor hallucis longus tendon transfer. *Int J Res Orthop* 2018;4:227-31.