

Original Research Article

Is deep venous thrombosis a common complication in patients treated with Ilizarov external fixator?

Sandeep Reddy, Harshad M. Shah, Naveen Kumar L.*, Rahul P., Vimal Kumar K. H.

Department of Orthopaedics, MS Ramaiah Medical College, Bengaluru, Karnataka, India

Received: 09 August 2017

Accepted: 31 August 2017

***Correspondence:**

Dr. Naveen Kumar L.,

E-mail: drnaveenkumarlokesh@gmail.com

Copyright: © the author(s), publisher and licensee Medip Academy. This is an open-access article distributed under the terms of the Creative Commons Attribution Non-Commercial License, which permits unrestricted non-commercial use, distribution, and reproduction in any medium, provided the original work is properly cited.

ABSTRACT

Background: Determining the incidence of deep venous thrombosis (DVT), a prospective study, in patients treated with Ilizarov external fixators for lower extremity fractures, fracture non unions or deformity correction.

Methods: A Prospective, observational and cross sectional study. 49 Patients with complex lower extremity injuries, deformities and non-union of fractures were treated with Ilizarov external fixator application, were assessed clinically and radiological (Venous Doppler) at regular intervals- 6 days post-surgery then at 6 weeks, 12 weeks and between 4 to 6 months post-operative. None were given chemoprophylaxis for the prevention of DVT and everyone were assessed pre operatively with a questionnaire and wells criteria was taken for assessment of high risk for developing venous thrombosis. There were 41 men and 8 women, 85.75% of the study group is of age 30 to 60 years.

Results: Only 1 of 49 patients developed radiological evident DVT within 6 days of surgery. Patients who underwent application of Ilizarov external fixator electively for deformity correction, osteomyelitis and non-union showed no clinical or radiological evident signs of DVT.

Conclusions: The incidence of DVT and PTE is minimal when patients without chemoprophylaxis underwent lower limb Ilizarov external fixator application for acute trauma and electively for deformity correction, treatment of non-union and osteomyelitis. However further comparative and randomized studies need to be done to confirm our results.

Keywords: Ilizarov external fixator, Lower limb, DVT, Chemoprophylaxis

INTRODUCTION

Deep vein thrombosis (DVT) is potential complications of lower limb orthopaedic surgery with incidence rate varying significantly with large range as reported. Very few studies have been done on the incidence of DVT in patients treated with ring external fixators for lower limb trauma surgeries and no data exists on patients treated for Non unions or deformity correction with ring fixators in Indian population. With the use of other form of external fixators in complex lower limb fractures, incidence of DVT as reported by Sems et al is 2.1% and very low as reported by Ferguson et al.^{1,2}

The American association of orthopaedic surgeons (AAOS) provides specific guidelines for Chemo thrombo prophylaxis for prevention of DVT in patients undergoing hip and knee arthroplasty and for hip fractures. The National Institute of Health and Clinical Excellence (NICE), United Kingdom suggests chemo prophylaxis be given to patients undergoing orthopaedic surgery other than lower limb arthroplasty and fixation of hip fractures only if risk factors for DVT/PE are present.^{3,4}

Not many studies done regarding incidence of DVT in patients who were treated electively with the use of ring external fixators for lower limb deformity correction and

non-union in Indian population. With this study we intend to find the rate of DVT in that undergoing elective/emergency treatment with ring External Fixators and to assess the need of chemoprophylaxis.

METHODS

The study was done at Ramaiah Medical College, Bengaluru, India, from January 2016 to December 2016 in patients who underwent ring external fixator application for the treatment of lower limb fracture nonunion, comminuted intra-articular knee or ankle fractures(open or closed) and deformity corrections. The total study group was 49 with mean age of 43.3 ranging from 17 years to 80 years.

Patients, who were treated with other form of external fixators, those who have undergone non orthopaedic surgeries prior to this surgery, patients on antiplatelet medications and those with previous history of DVT were excluded from the study.

A questionnaire was given to patients prior to surgery, to calculate the risk of developing deep venous thrombosis using wells criteria.

In post-operative period patients were mobilized the morning after the surgery and majority of them were permitted to bear weight fully. They were clinically assessed for signs of DVT and were explained at the time of discharge about the symptoms of DVT and asked them to report immediately to OPD if they experienced any. Every patient was assessed radiologically with venous doppler scan by a single examiner at the time of discharge, 6 weeks and 12 weeks post operatively, an interval of 6 weeks and then finally after approximately 6 months from the day of surgery..

RESULTS

From January 2016 until December 2016 over a period of 1 year, 49 patients underwent application of Ilizarov fixator by the senior author. Age, sex, indication for surgery, type of surgery, Well’s criteria for risk of DVT, bone to which the frame was applied was noted down.

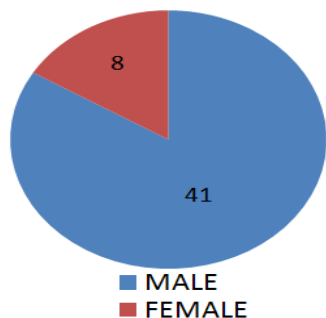


Figure 1: Sex distribution.

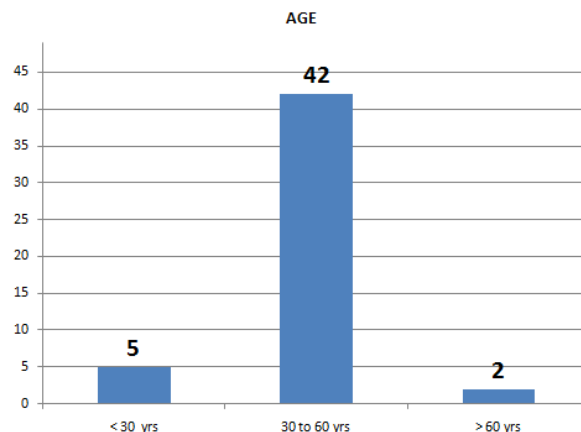


Figure 2: Age distribution.

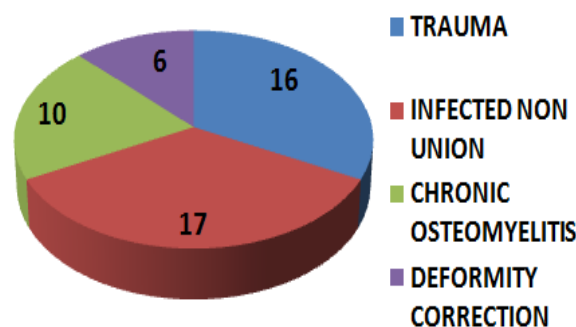


Figure 3: Indication for Ilizarov external fixator application.

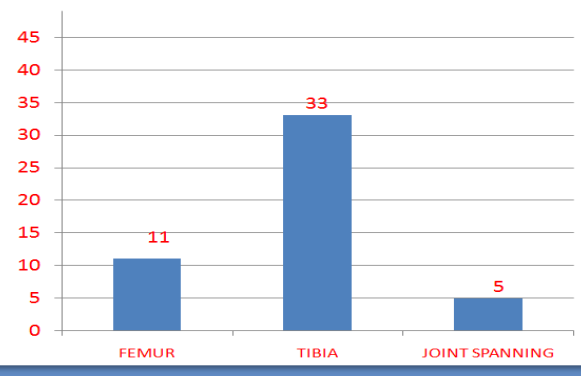


Figure 4: Site of external fixator application.

39 patients were of age group between 30-60 years (Figure 1), with 8 women and 41 men (Figure 2). 16 of the patients underwent Ilizarov fixation for intra articular fractures around knee and ankle. 17 patients with infected non-union, 6 with deformity/contractures and 10 with osteomyelitis (1 patient had septic arthritis) underwent the Ring external fixator application (Figure 3).

Ring fixator to femur was applied in 11 patients, to Tibia in 33 and in 5 of them it was knee joint spanning (Figure 4). 2 patients underwent arthrodesis of the knee joint for

septic arthritis and fixed flexion deformity. In 4 cases ankle was immobilized with a joint spanning fixation. No individual underwent ring fixator application bilaterally. We found no bleeding complications however pin track infection was the most common complication reported.

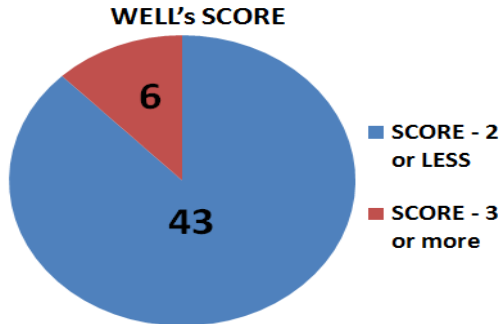


Figure 5: Well's score.

43 patients had wells criteria of 2 or less and were considered of having lower risk of developing DVT (Figure 5). Two patients were above 70 years of age and age itself was considered as a risk factor for the development of DVT and was closely monitored for any symptoms. 1 individual was affected by DVT at the rate of 1/49 i.e. 2.4%.⁵ He was treated with anti-thrombotic therapy for a period of 4 weeks and during his subsequent follow up venous doppler studies at 6, 12 weeks and between 4 to 6 months, no evidence of DVT was found.

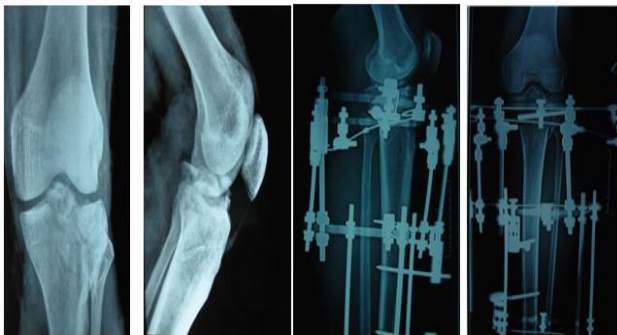


Figure 6: X-rays pre and post-operative.

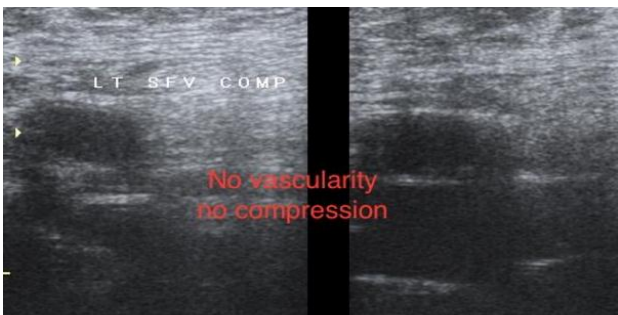


Figure 7: Venous doppler scan of the patient showing DVT.

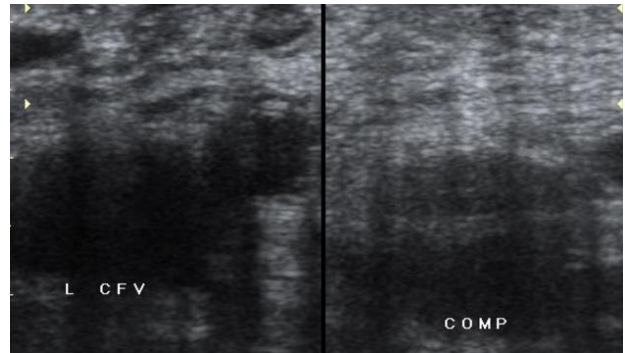


Figure 8: Normal venous doppler scan.

Case

A 50-year-old male smoker and hypertensive had left Tibia plateau fracture (Figure 6). The fracture fixation was done on 23rd march of 2016 two days post trauma. He developed DVT a week later confirmed by venous doppler scan while the fixator was still in situ (Figure 7) in contrast to normal venous doppler scan without DVT (Figure 8). He was treated with Enoxaparin 40 units subcutaneously for 1 week then Rivaraxoban 10mg orally for a period of 21 days. In his subsequent follow up Doppler study at the time of 6 weeks, 12 weeks and after 6 months no evidence of DVT was found.

DISCUSSION

Following hip and knee arthroplasty the incidence of clinically significant and radiologically detected DVT has been reported from 0.33 to 40% and 30 to 56% and fatal PE 0.04–0.22%.⁶⁻⁸ Ultra Sound Doppler has the sensitivity of 63%–94% to detect deep venous thrombosis as quoted in a meta-analysis.⁹ There is a clear guideline on the preventive aspect of this complication as given by both AAOS and NICE.^{3,4}

Significantly there is less number of studies on incidence of DVT post external fixator application and very rare when single type - Ilizarov external fixator is considered to treat various orthopaedic challenges.^{1,10,11} Sems et al reported 2.1% (3 out of 143) of the study population found to have DVT following ultrasound doppler screening post operatively.¹ Roberts et al in attempt to find the incidence of DVT when external fixator is applied electively reported only 1 out of 258 patients (0.39%) had DVT and 71 of them has received chemo prophylaxis.¹⁰ There is no set of protocols by any big institutes or associations that can be followed to prevent DVT in patients being treated with application of external fixators for short and long duration.

The Incidence of DVT in our study is about 2.4% in patients treated with Ilizarov's external fixator system who have not received chemo prophylaxis and comparable to other studies.^{1,2,10} The incidence of radiological and clinically evident DVT in patients with

Well's score of 3 or more is 16.6% which is much lower as compared to people undergoing arthroplasty or internal fixation for hip.¹¹ No radiological evidence of DVT was found in patients who underwent ring external fixator application electively for the treatment of non-union, osteomyelitis and deformity correction.

In a study by Sharma et al, of 112 patients undergoing internal fixation for hip fractures 22 developed DVT with i.e. 19.6% when no chemoprophylaxis was given and in a meta-analysis done by Sen et al, they say the incidence of DVT reported varies from 0 to 71% due to the inconsistency in the modality of diagnosis and strongly recommends antithrombotic prophylaxis for all the patients who are undergoing lower limb surgeries for trauma.^{12,13} Agarwal et al and Nair et al too proposed the need of anticoagulation prophylaxis for all the patients as the rate of incidence is not so uncommon in Indian population, in spite of starting on chemoprophylaxis the incidence is as high as 34.44% and 3.25% respectively.^{14,15}

Ours is a pilot study with sample size of 49 patient's age, gender and other matching has not been done. The current study is an observational study and not an experimental study. We have not done a comparative analysis to find the incidence in those who have received chemoprophylaxis with the same method of fixation or in those patients who underwent other form of external fixator application barring Ilizarov's ring Fixator. The most specific screening tool for detection of vascular thrombo embolism (VTE) is D-Dimer assay- if the values are normal it invariably rules out DVT and it has not been assessed in our study.¹⁶

CONCLUSION

The incidence of venous thromboembolism i.e. DVT and PTE is minimal when patients without chemoprophylaxis underwent lower limb Ilizarov external fixator application for acute trauma or nil in patients undergoing ring fixator electively for deformity correction, osteomyelitis or in the treatment of non-union, however due to the limitations of the study as mentioned before further comparative and randomized studies need to be done to confirm our results.

Funding: No funding sources

Conflict of interest: None declared

Ethical approval: The study was approved by the institutional ethics committee

REFERENCES

1. Sems SA, Levy BA, Dajani K, Herrera DA, Templeman DC. Incidence of deep venous thrombosis after temporary joint spanning external fixation for complex lower extremity injuries. *J trauma.* 2009;66:1164–6.

2. Ferguson JY, Sutherland M, Pandit HG, McNally M. The rate of symptomatic venous thromboembolism in patients undergoing elective Ilizarov surgery and the cost of chemical prophylaxis. *Bone Joint J.* 2014;96-B:426–30.
3. American Association of Orthopaedics Surgeons. Preventing venous thromboembolic disease in patients undergoing elective hip and knee arthroplasty evidence-based guideline and evidence report.
4. National Institute of Health and Clinical Excellence UK. Venous thromboembolism: reducing the risk for patients in hospital.
5. Spencer FA, Emery C, Joffe SW, Pacifico L, Lessard D, Reed G. Incidence rates, clinical profile, and outcomes of patients with venous thromboembolism. The Worcester VTE study. *J Thromb Thrombolysis.* 2009;28(4):401-9.
6. Kim YH, Oh SH, Kim JS. Incidence and natural history of deep vein thrombosis after total hip arthroplasty. *J Bone Joint Surg Br.* 2003;85(5):661–5.
7. Clayton RAE, Gaston P, Watts AC, Howie CR. Thromboembolic disease after total knee replacement: experience of 5100 cases. *J Knee.* 2009;16:18–21.
8. Howie C, Hughes H, Watts AC. Venous thromboembolism associates with hip and knee replacement over a ten-year period. *J Bone Joint Surg Br.* 2005;87-B(12):1675–80.
9. Goodacre S, Sampson F, Thomas S, van Beek E, Alex Sutton. FSystematic review and meta-analysis of the diagnostic accuracy of ultrasonoFigurey for deep vein thrombosis. *BMC Medical Imaging.* 2005;5:6.
10. Roberts DJS, Panagiotidou A, Sewell M, Calder P, Goodier D. Incidence of DVT and Pulmonary embolism with the elective use of external fixator. *Strategies Trauma Limb Reconst.* 2015;10(2):67-71.
11. Wells PS, Hirsh J, Anderson DR, Lensing AW, Foster G, Kearon C, et al. Accuracy of clinical assessment of deep-vein thrombosis. *Lancet.* 1995;345(8961):1326-30.
12. Sharma H, Maini L, Agrawal N, Upadhyay A. Incidence of deep vein thrombosis in patients with fractures around the hip joint: a prospective study. *Indian J Orthop.* 2002;36:5.
13. Sen RK, Tripathy SK, Singh AK. Is routine thromboprophylaxis justified among Indian patients sustaining major orthopedic trauma? A systematic review. *Indian J Orthop.* 2011;45(3):197-207.
14. Nair V, Kumar R, Singh BK, Sharma A, Joshi GR. Comparative study of extended versus short term thromboprophylaxis in patients undergoing elective total hip and knee arthroplasty in Indian population. *Indian Journal Orthop.* 2013;47:161-7.
15. Agarwala S, Bhagawat AS, Wadhvani R. Pre and Postoperative DVT in Indian patients – Efficacy of

LMWH as a prophylaxis agent. *Indian J Orthop*. 2005;39:55-8.

16. Stein PD, Hull RD, Patel KC, Olson RE, Ghali WA, Brant R, et al. D-dimer for the exclusion of acute venous thrombosis and pulmonary embolism: a systematic review. *Ann Intern Med*. 2004;140(8):589-602.

Cite this article as: Reddy S, Shah HM, Naveen KL, Rahul P, Vimal KKH. Is deep venous thrombosis a common complication in patients treated with Ilizarov external fixator? *Int J Res Orthop* 2017;3:1180-4.