

Case Report

Can an open displaced tibial fracture be treated without surgery? a treatment discussion: a case report

Sara Elisa Diniz*, Joao Vale, Pedro Neves

Department of Orthopaedics, Centro Hospitalar do Porto – Hospital de Santo António, Largo Prof Abel Salazar, Portugal

Received: 20 January 2021

Revised: 16 February 2021

Accepted: 04 March 2021

*Correspondence:

Dr. Sara Elisa Diniz,

E-mail: saradiniz4@gmail.com

Copyright: © the author(s), publisher and licensee Medip Academy. This is an open-access article distributed under the terms of the Creative Commons Attribution Non-Commercial License, which permits unrestricted non-commercial use, distribution, and reproduction in any medium, provided the original work is properly cited.

ABSTRACT

The authors present a case of a 70-year-old female with left tibial open fracture (Gustillo-Anderson type II) with previous history of trauma of the same limb, from which resulted a Morel-Lavallée injury complicated with extensive tissue necrosis. Considering the sequel condition of soft tissues (scarring and extensive fibrosis), conservative treatment was taken and successful result was achieved. In this case the biggest concern was not the traumatic tissue damage caused by the fall, but the poor quality of tissues already existent before this event. Although surgical treatment is the gold standard in these cases, we must analyze case by case the risk benefit of each procedure and choose the one we believe is the best for the patient.

Keywords: Open fracture, Tibial fracture, Soft tissues, Surgery, Conservative treatment

INTRODUCTION

Open injuries are relatively frequent and mainly occur in long bones.¹ Its subcutaneous location favors a higher incidence in tibia, with reported rates varying from 12% to 47%.² There is a bimodal distribution of tibial open fractures with higher prevalence in young males after major trauma (motor vehicular or work accidents) and old female patients after minor trauma (often indirect).^{2,3} These fractures may be particularly challenging to treat, due to a number of conditions: (a) minimal soft tissue coverage, (b) poor blood supply and (c) severe soft-tissue compromise in a considerable number of cases (Gustillo-Anderson type III).^{1,4} These factors are followed by some prognostic implications such as higher risk of infection, bone nonunion or wound complications.^{1,4}

Surgeons are often required to make decisions about the bone and soft tissue acute management and therefore it is important to have in mind all the available means of treatment.¹ With this case it is intended to discuss about the chosen treatment and other possible options.

CASE REPORT

The authors present a case of a 70-year-old female with left tibial open fracture (gustillo-anderson type II) after a fall from standing height (Figure 1). The radiographs showed a transverse metaphyseal fracture, with 15 mm displacement in anterior-posterior (AP) view and about 80% of fracture edges apposition. In lateral view it wasn't displaced (Figure 2).

This patient had previous history of major trauma (hit by a car), two years before, from which resulted a Morel-Lavallée injury and ankle fracture dislocation in this same left limb. It complicated with extensive tissue necrosis of the knee, leg and ankle, with the need for 7 soft tissue surgeries (soft tissue debridement and skin grafts). Given this situation, ankle fracture was treated conservatively at that time. Besides this traumatic event, only hypertension and dyslipidemia background are important to refer.

In the emergency room the orthopedic team proceeded to wound irrigation with sodium chloride (around 6 L) and antiseptic (iodopovidone) solution. Prophylactic antibiotic (cephazolin 2 g EV) and thromboprophylaxis (enoxaparin sodic 40 mg/0.4 ml) were initiated.

Considering tissue sequelae (scarring, extensive fibrosis and no underneath subcutaneous tissue) (Figure 1), conservative treatment was chosen. It was performed reduction of the extruded bone edge and primary closure of the wound. The limb was immobilized with a long leg plaster cast with an anterior window at the wound level. After this initial approach, the patient was hospitalized for antibiotics (cephazolin 1 g EV every 8 hours), thromboprophylaxis (enoxaparin sodium 40 mg/0.4 ml SC once per day) and soft tissue surveillance. The hospitalization lasted 3 weeks, during which there was good clinical evolution, no fever or wound complications.

The patient was discharged with indications for crutch walking and non-weight bearing. For the first month, radiological control (AP and lateral radiographs) was done weekly and after that, monthly in outpatient clinic. After 4 weeks, radiographs revealed an additional 4 mm lateral displacement, and 3 mm tibial shortening (Figure 3), remaining stable since then. At 3 months, a computed tomography (CT) scan was performed, showing some signs of fracture healing (Figure 4). The cast and indications for non-weight bearing were maintained and at 6 months a new CT scan was done, revealing fracture consolidation (Figure 5). The cast was changed to an articulated knee orthosis, the patient started walking with partial weight bearing at this stage and began physical therapy. One year after the injury, the patient has minimal pain, needs one crutch for walking, has a 0-90° knee range of motion and no soft tissues complications (Figure 6).

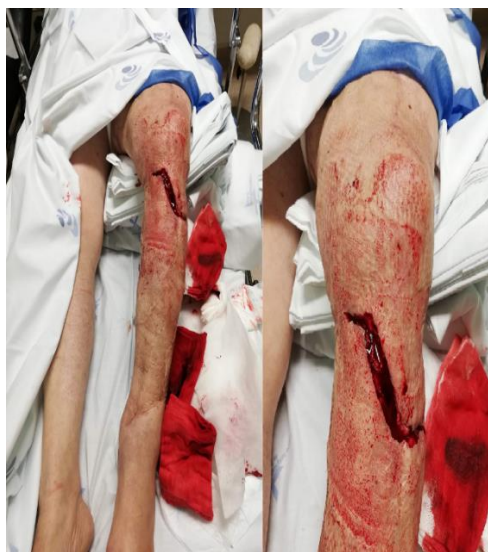

Figure 1: Emergency room: Left tibial open fracture (gustillo-anderson type- II with bone extrusion and poor quality of soft tissues (scarring and fibrosis)).

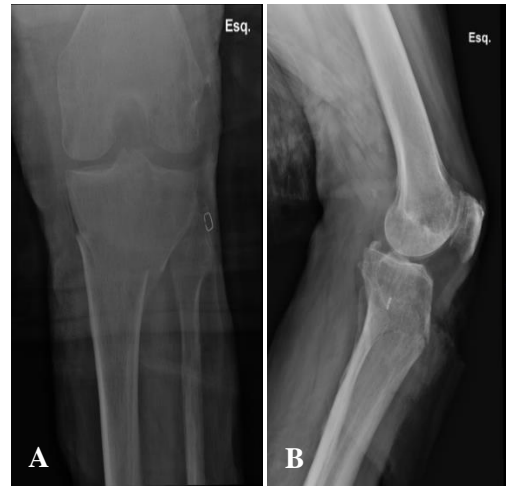

Figure 2: (A) AP radiograph showing 15 mm fracture displacement (B) Lateral radiograph showing a fracture without displacement.

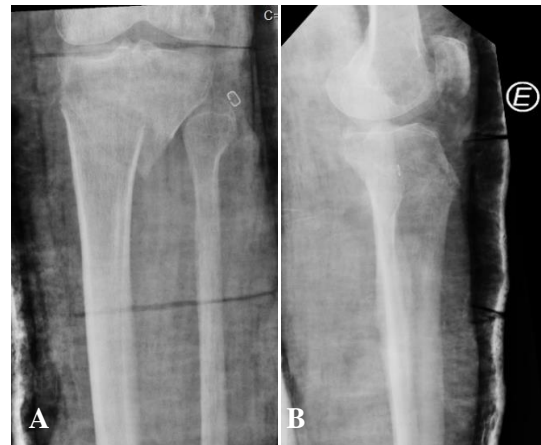

Figure 3: (A) AP radiograph 4 weeks later, it revealed an additional 4 mm lateral displacement, and 3 mm tibial shortening; (B) Lateral radiograph 4 weeks later.

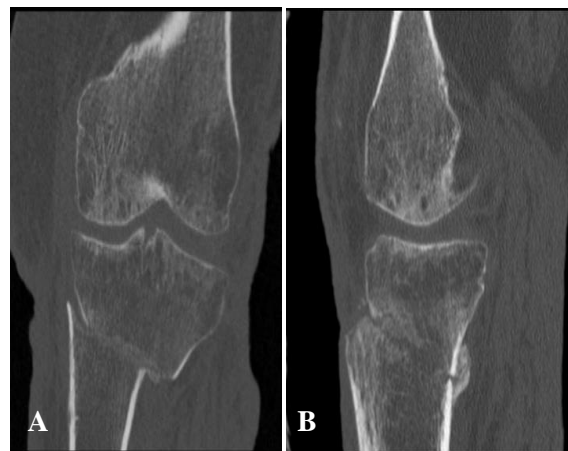

Figure 4: (A) AP, CT Scan 3 months later, showed some signs of fracture healing; (B) Lateral, CT Scan 3 months later, showed some signs of fracture healing.

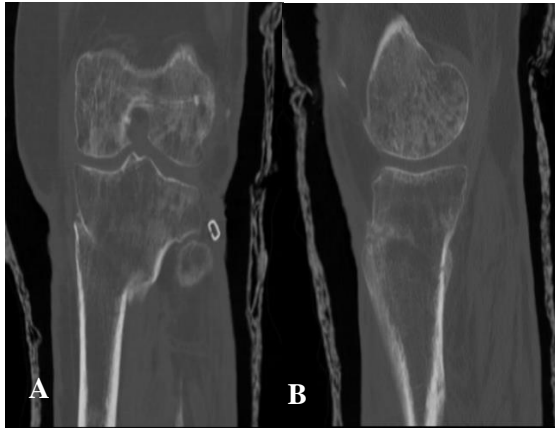


Figure 5: (A) AP, CT scan 6 months later, revealing fracture consolidation; (B) Lateral, CT scan 6 months later, revealing fracture consolidation.

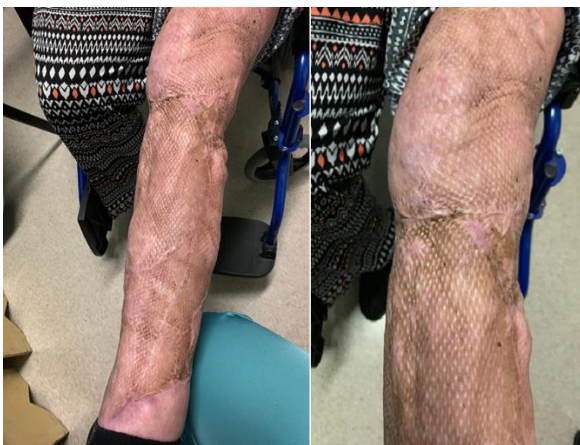

Figure 6: Soft tissues appearance 1 year later without wound complications.

DISCUSSION

Although there are some debatable topics, this is a relevant case, given the decisions taken and the special patient's circumstances. Generally speaking, the management of an open tibial fracture requires prompt history and physical examination, systemic antibiotics, local debridement and irrigation, temporary or definitive fixation, and less frequently, soft-tissue coverage and/or vascular repair.^{5,6} Potentially life-threatening injuries were ruled out on a primary detailed evaluation. This patient presented an open fracture, Gustillo-Anderson type II (9 cm wound).⁶ Systemic antibiotic prophylaxis (Cephalosporin) was initiated within 3 hours after trauma, in accordance with current scientific evidence to prevent Gram-positive infection.⁵ Although combined gram-positive and gram-negative coverage for these less-severe open fractures has been proposed by other investigators, it is not widely used.⁷

A debridement with antiseptic and sodium chloride solution was then performed in the emergency room. Early accurate irrigation and debridement is the most

important surgical procedure for open lower limb fractures to prevent bacterial inflow and growth,^{6,9} aiding healing and promoting comfort.¹⁰ Despite there is no theoretical advantages^{6,9} and may even be toxic to host cells,⁷ antiseptics were additionally used. The use of antiseptics is debatable, given the clean wound and prior skin sequelae. The irrigation was done by low-pressure, gravity tubing, avoiding bacterial seeding into the fracture focus like advised in literature.⁷ Routine wound cultures are no longer recommended,¹⁰ because they fail to identify the organism in most cases,⁷ so these weren't collected.

Relatively to fracture fixation, the ideal method of definite treatment is still under debate. There are many ways of provisional or definitive fracture stabilization including external fixation, plates and screws and locking nails.⁶ The patient presented a metaphyseal transverse tibial fracture. Osteosynthesis with plate and screws allows anatomic reductions, however was soon excluded because of consequent tissue aggression. Intramedullary nailing is less aggressive to tissues, but it isn't an appropriate fixation method to metaphyseal fracture. It is effective in diaphyseal fractures, being biomechanically superior to others.⁷ Although widely used in the past, long plaster is not usually recommended.^{6,11} This patient had a very conditionate tissue elasticity with plenty of scar tissue around the knee, leg and ankle and, besides that, the fracture had only a small displacement in the coronal plane. Assuming a compromise solution, the wound was closed, a long limb plaster cast was applied and the patient was hospitalized for surveillance. External fixation would be a good alternative even as a definitive treatment,¹⁰ however, pin infection would be dramatic in this patient. Nevertheless, it could have been a viable option.

Most guidelines recommend 24 hours of antibiotics following type I and II Gustillo fractures.⁵ Patzakis and Wilkins found no additional benefit on the risk of infection prolonging the duration of antibiotics beyond 3 days.¹² Extension of this period for 48h postoperatively is a safe and effective prophylactic option, so it was decided to complete 48 hours of antibiotic.¹³

Another relevant question is the decision to proceed to a primary wound closure after an open fracture. The existent literature supports that, in appropriately selected subjects (no contamination), there is a lower risk of deep infections and nonunion when compared with delayed closure.¹⁴ This patient presented a non-contaminated wound and extensive scar tissue that might become a problem to close secondarily, so a primary wound closure was performed. One important topic to discuss is hospitalization time. A 3-week hospitalization may be excessive, thinking in a matter of costs and potential medical complications, namely opportunistic infections. Initial close surveillance is essential due to the incidence of compartment syndrome, which can be as high as 91% in open tibial fractures.¹⁰ It was a low energy trauma, in an old woman with a slight displacement, which reduces

the risk of compartment syndrome. However, poor elasticity of the tissues and extensive fibrosis could increase the risk. After finished antibiotic treatment, decreased edema without neurovascular findings, favorable wound and analytical evolution, the patient was safely discharged and maintained follow-up in an outpatient clinic. It is discussable the 3-week hospitalization.

Another important topic is the immobilization with a long leg plaster cast for 6 months. This cast was removed only when there were clear signs of consolidation. Despite the prolonged cast wear, one year later, the patient has a 0-90° knee range of motion needing only one crutch to walk. When image features of fracture healing appeared, immobilization could have been changed to a hinged brace, ensuring joint mobility with safety too. This was a successful case, with some debatable topics. It will remain the question “Would soft tissues have evolved well with surgical treatment?”. It is known that a good soft-tissue coverage promotes a good blood supply, prevents infections, and expedites healing and early mobilization.^{4,15,16} The biggest problem was not the traumatic tissue damage caused by the fall, but the poor quality of tissues already existent before this event.

CONCLUSION

A type I or II gustillo-anderson fracture, with a slight fracture displacement, in a compliant patient and especially, with a scarring and extensive fibrosis of the limb may be successfully treated with a cast and close surveillance. In this particular case, it was intended to discuss all the steps, showing that, although there are guidelines to follow, each case must be individually analyzed. Although surgical treatment is gold standard in these cases, we must analyze case by case the risk-benefit of each procedure and choose the one we believe is the best for the patient.

Funding: No funding sources

Conflict of interest: None declared

Ethical approval: Not required

REFERENCES

- Mundi R, Chaudhry H, Niroopan G, Petrisor B, Bhandari M. Open Tibial Fractures: Updated Guidelines for Management. *J Bone Joint Surg Rev.* 2015;3(2),1.
- Rockwood, Charles A. In: Bucholz RW, Heckman JD, CourtBrown CM, eds. *Rockwood and Green's fractures in adults.* 6th ed. United States, Philadelphia: Lippincott Williams & Wilkins. 2014.
- Court-Brown CM, Bugler KE, Clement ND, Duckworth AD, McQueen MM. The epidemiology of open fractures in adults: A 15-year review. *Injury.* 2012;43(6),891–7.
- Thakore RV, Francois EL, Nwosu SK, Attum B, Whiting PS, Siuta MA et al. The Gustilo–Anderson classification system as predictor of nonunion and infection in open tibia fractures. *Europ J Traum Emerg Surg.* 2016;43(5):651–6.
- Duyos OA, Beaton-Comulada D, Davila-Parrilla A, Perez-Lopez JC, Ortiz K, Foy-Parrilla C et al. Management of Open Tibial Shaft Fractures. *J Am Acad Orthopaed Surg.* 2017;25(3):230–8.
- Griffin M, Malahias M, Khan W, Hindocha S. Update on the management of open lower limb fractures. *Open Orthop J.* 2012;6:571-7.
- Zalavras CG. Prevention of Infection in Open Fractures. *Infectious Disease Clinics of North America,* 2017;31(2):339–52.
- Gustilo RB, Merkow RL, Templeman D. The management of open fractures. *J Bone Joint Surg* 1990;72-A:299-304.
- Anglen JO. Comparison of soap and antibiotic solutions for irrigation of lower limb open fracture wounds. A prospective randomized study. *J Bone Joint Surg Am.* 2005;87:1415-22.
- Halawi MJ and Morwood MP. Acute Management of Open Fractures: An Evidence-Based Review. *Orthopedics.* 2017;38(11),1025–33.
- Nanchahal J, Nayagam S, Khan U, Moran C, Barrett S, Sanderson F, et al, Standards for treatment of open fractures of the lower led. British Association of Reconstructive and Aesthetic Surgeons, United Kingdom, UK: Royal society of medicine press. 2009;1-108.
- Patzakis MJ, Wilkins J. Factors influencing infection rate in open fracture wounds. *Clin Orthop Relat Res.* 1989;243:36-40.
- Hauser CJ, Adams CA, Eachempati SR. Prophylactic Antibiotic Use in Open Fractures: An Evidence-Based Guideline. *Surgical Infections.* 2006;7(4):379–405.
- Scharfenberger AV, Alabassi K, Smith S, Weber D, Dulai SK, Bergman JW, et al. Primary Wound Closure After Open Fracture: A Prospective Cohort Study Examining Nonunion and Deep Infection. *J Orthopaed Traum.* 2017;31(3):121–6.
- VandenBerg J, Osei D, Boyer MI, Gardner MJ, Ricci WM, Spraggs-Hughes A. Open Tibia Shaft Fractures and Soft-Tissue Coverage: The Effects of Management by an Orthopedic Trauma/Microsurgical Team. *J Orthopaed Trau.* 2017;31(6):339–44.
- Nambi GI, Salunke AA, Thirumalaisamy SG, Babu VL, Baskaran K, Janarthanan T, et al. Single stage management of Gustilo type III A/B tibia fractures: Fixed with nail and covered with fasciocutaneous flap. *Chin J Traumatol.* 2017;20(2):99–102.

Cite this article as: Diniz S, Vale J, Neves P. Can an open displaced tibial fracture be treated without surgery? a treatment discussion: a case report. *Int J Res Orthop* 2021;7:667-70.