

Original Research Article

Assessment of the outcome of fracture proximal humerus transdeltoid versus deltopectoral approach with PHILOS

Rajeev Anand, Amit Dwivedi*, Apoorve Agarwal, Fenil Shah

Department of Orthopaedics, Santosh Medical College and Hospital, Ghaziabad, Uttar Pradesh, India

Received: 09 October 2020

Revised: 30 October 2020

Accepted: 31 October 2020

*Correspondence:

Dr. Amit Dwivedi,

E-mail: dramitdwivedi@yahoo.in

Copyright: © the author(s), publisher and licensee Medip Academy. This is an open-access article distributed under the terms of the Creative Commons Attribution Non-Commercial License, which permits unrestricted non-commercial use, distribution, and reproduction in any medium, provided the original work is properly cited.

ABSTRACT

Introduction: Fracture proximal humerus accounts for 4 percent of all fractures. Out of all the humerus fractures, proximal fractures accounts for 26%. According to the Neer's classification, 2, 3- and 4-part fracture are difficult to achieve stable fixation. In this study, we want to assess whether the different surgical approach, deltopectoral and transdeltoid approach, used for the stabilization of the fracture proximal humerus effects on the outcome of the surgery.

Method: A total of 30 patients with fracture proximal humerus 2, 3 and 4-part were included in this study and were divided into 2 groups. In group 1, 15 patients were taken and were operated by deltopectoral approach, while in group 2, 15 patients were taken and operated by transdeltoid approach. All the fixation was done by PHILOS.

Result: In group 1, out of 3 patients having 2-part fracture, 2 had excellent result and 1 had fair result. Out of 4 patients having 3-part fracture, 3 had good outcome and 1 had fair result. Out of 6 patients having 4-part fracture, 1 had good outcome. In group 2, out of the 3 patients having 2-part fracture, 1 had excellent outcome and 2 had good outcome. Out of the 4 patients having 3-part fracture, 1 had excellent outcome, 3 had good outcome. Out of the 6 patients having 4-part fracture, 3 had good result.

Conclusions: Deltopectoral approach is recommended for calcar reconstruction that provides better visibility of medial calcar reduction while transdeltoid approach is recommended for greater tuberosity reduction that provides better visibility of greater tuberosity.

Keywords: Proximal humerus fracture, PHILOS, Transdeltoid approach, Deltopectoral approach

INTRODUCTION

Fracture proximal humerus are the most common cause of morbidity mainly in elderly patients due to associated osteoporosis.¹ 80-85% of the fracture humerus are treated conservatively, while only 10-15% of displaced and complex fractures are treated operatively. Fracture proximal humerus accounts for 4 percent of all fractures. Out of all the humerus fractures, proximal fractures accounts for 26%. With advancement in the procedures ranging from pinning to replacement surgeries and with better implants, head preserving surgeries with the help of locking plates (PHILOS) have increased.²⁻⁴ PHILOS

provides good angular fixation especially for osteoporotic bones. For the exposure of the proximal humerus, mainly two approaches are used, deltopectoral and transdeltoid approach.^{5,6} In this study, we want to assess whether the different surgical approach used for the stabilization of the fracture affects the outcome of the surgery.^{7,8}

METHODS

A total of 30 patients having fracture proximal humerus, admitted in orthopedic department of Santosh medical college and hospital from July 2019 to September 2020 were included in this retrospective study. Out of 30

patients, 22 were male and 8 were female. All were operated by open reduction and internal fixation with PHILOS. The patients were divided into two groups according to the approach preference of the surgeon. 15 patients were included in group 1, which were operated by deltopectoral approach, while other 15 patients were included into group 2, which were operated by the transdeltoid approach. The patients were classified according to the Neer's proximal humerus fracture classification.

Inclusion criteria included patients having age 30-55 years, fracture type 2, 3 and 4 (Neer's classification of proximal humerus).

Exclusion criteria excluded patients having age <30 and <55 years, fracture type 1, infected wound and patient not fit surgery.

In group 1, the mean age of patients was 45 years. Out of the 15 patients, 3 patients had 2-part fracture, 3 had 3-part fracture and 6 patients had 4-part fracture of the proximal humerus.

In group 2, the mean age was 48 years. Out of the 15 patients 3 had 2-part fracture, 3 had 3-part fracture and 6 had 4-part fracture of the proximal humerus.

In deltopectoral approach, the incision was started from coracoid process anteriorly extending laterally to the shaft of humerus, subcutaneous tissue dissected and the deltopectoral groove was identified, the deltoid muscle was retracted laterally and the pectoralis major muscle along with the cephalic vein were retracted medially and the fracture site was exposed.

In transdeltoid approach, the incision was started from the tip of the acromion process and extended distally. The fascia over the deltoid muscle was incised along the line of skin incision, the deltoid was splitted and the fracture site was approached.

The patients were followed up at 4 weeks, 3 months, 6 months and 1 year.

RESULTS

Functional outcome was accessed according to constant scoring system.

In group 1, out of 4 patients having 2-part fracture, 2 had excellent result and 1 had good result and 1 had fair result. Out of 5 patients having 3-part fracture, 1 had excellent outcome, 3 had good outcome and 1 had fair result. Out of 6 patients having 4-part fracture, 1 had good outcome, 4 had fair outcome and 1 had poor result. 1 patient had a stitch line infection.

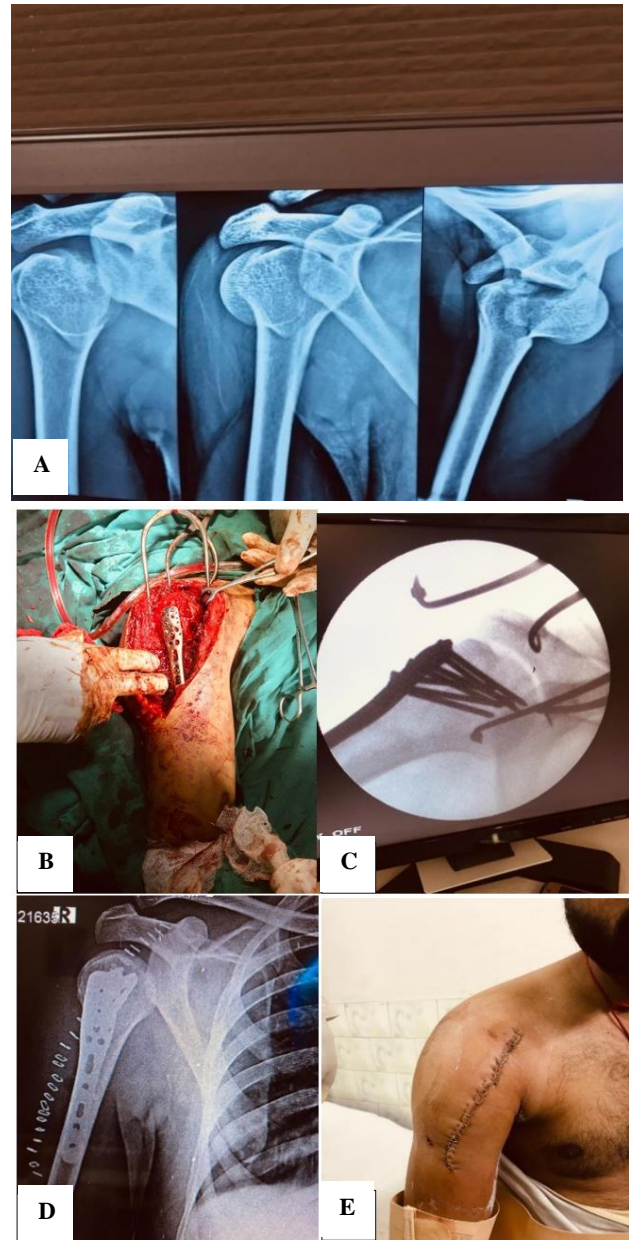


Figure 1 (A-E): Pre-operative and post-operative X-rays along with intra-operative pictures of a male patient with proximal humerus fracture operated by deltopectoral approach.

Table 1: Result of patients of group 1.

Group 1	Number of patients		
	2-part fracture (n=4)	3-part fracture (n=5)	4-part fracture (n=6)
Excellent	2	1	0
Good	1	3	1
Fair	1	1	4
Poor	0	0	1

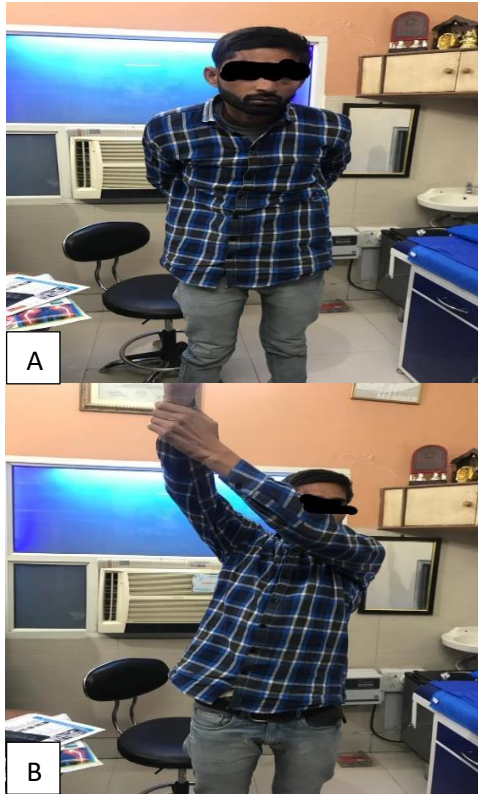


Figure 3 (A-B): Functional outcome of a male patient operated by transdeltoid approach.

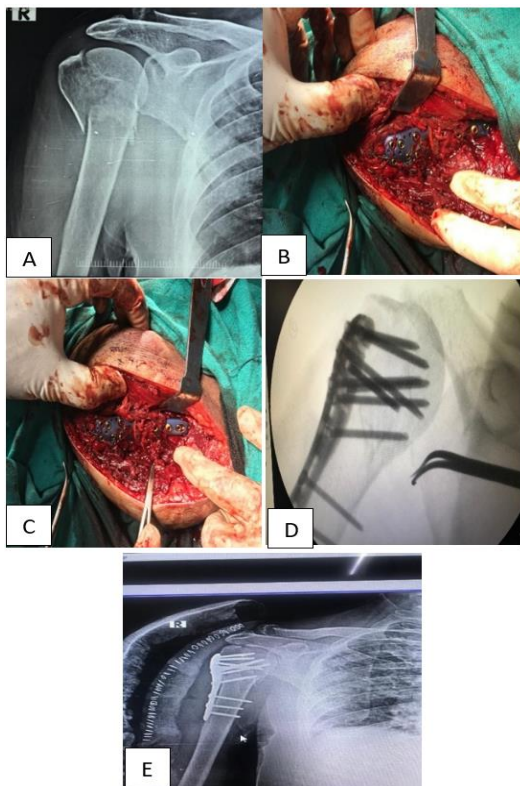


Figure 4 (A-F): Pre-operative and post-operative X-rays along with intra-operative pictures of a male patient with fracture proximal humerus operated by transdeltoid approach.

Table 2: Result of patients of group 2.

Group 2	Number of patients		
	2-part fracture (n=4)	3-part fracture (n=5)	4-part fracture (n=6)
Excellent	2	1	0
Good	2	3	3
Fair	0	1	2
Poor	0	0	1

In group 2, out of the 4 patients having 2-part fracture, 2 had excellent outcome and 2 had good outcome. Out of the 5 patients having 3-part fracture, 1 had excellent outcome, 3 had good outcome and 1 patient had fair outcome. Out of the 6 patients having 4-part fracture, 3 had good result, 2 had fair outcome and 1 had poor outcome. 1 patient had a loss of reduction of the fracture.¹⁰

DISCUSSION

Deltopectoral approach is traditionally used for management of proximal humeral fractures. Deltopectoral approach involves retraction of deltoid laterally while pectoralis muscle medially, permits direct visualization of fracture. Deltopectoral approach is practically more useful for lesser tuberosity fracture and in fractures with anterior dislocation; however, in complex displaced fractures, in which greater tuberosity migrates postero-superiorly, are sometime difficult to manage with deltopectoral approach. Author felt difficulty in reducing widely displaced tuberosities with deltopectoral approach. In posterior fracture, dislocations deltopectoral approach provides poor access for reduction and proved to be inferior as compared to deltoid-splitting approach. However, reduction of medial calcar under direct visualization provides good functional outcome in deltopectoral approach. Blood loss and operative time is more when compare to deltoid splitting approach.

In deltoid-splitting approach, deltoid fibers are splitted in anterior and middle half to allow exposure of fracture and lateral aspect of shaft. Posterosuperior migration of tuberosity and posterior fracture dislocation are efficiently managed through this approach. Fractures extending distally in shaft can also be managed through this approach effectively by extending incision distally. Axillary nerve exploration is required for managing such fractures.

For the fracture proximal humerus involving calcar and lesser tuberosity, classical deltopectoral approach, in which deltoid muscle is retracted laterally and pectoralis major along with the cephalic vein are retracted medially, is more preferable. However, blood loss and the operating time by deltopectoral approach is more when compared to the transdeltoid approach.^{11,12}

Neer’s classification of proximal humerus fractures⁹

Fragments-anatomic neck, surgical neck, greater tuberosity, lesser tuberosity.

Table 3: NEER's classification of proximal humerus fracture.

Types of fracture	Variables
1-part fracture	No displacement or angulation less than 45 degree or separation less than 1 cm.
2-part fracture	Displacement of 1 fragment.
3-part fracture	Displacement of 2 individual fragments from remaining humerus.
4-part fracture	Displacement of all 4 fragments.

Fracture proximal humerus involving greater tubercle, which are more complex fractures, are difficult to reach by classical deltopectoral approach. In such fractures, transdeltoid approach, in which the deltoid muscle fibres are splitted along the line of the skin incision, and the fracture site is exposed.¹³ By this approach, the incision line can be extended distally if needed.¹⁴

CONCLUSION

Deltopectoral approach is recommended for calcar reconstruction that provides better visibility of medial calcar reduction while transdeltoid approach is recommended for greater tuberosity reduction that provides better visibility of greater tuberosity.

Funding: No funding sources

Conflict of interest: None declared

Ethical approval: The study was approved by the institutional ethics committee

REFERENCES

- Horak J, Nilsson BE. Epidemiology of fracture of the upper end of the humerus. Clin Orthop Relat Res. 1975;112:250-3.
- Sudkamp N, Bayer J, Hepp P, Voigt C, Oestern H, Kaab M et al. Open reduction and internal fixation of proximal humeral fractures with use of the locking proximal humerus plate. Results of a prospective, multicenter, observational study. J Bone Joint Surg Am. 2009;91:1320-8.
- Martetschlager F, Siebenlist S, Weier M, Sandmann G, Ahrens P, Braun K et al. Plating of proximal humeral fractures. Orthop. 2012;35:e1606-12.
- Maier D, Jager M, Strohm PC, Sudkamp NP. Treatment of proximal humeral fractures-A review of

- current concepts enlightened by basic principles. Acta Chir Orthop Traumatol Cech. 2012;79:307-16.
- Hoppenfeld S, de Boer Piet. Surgical Exposures in Orthopaedics: The Anatomic Approach, 4th ed. Shoulder. 2009;5-38.
 - Hepp P, Theopold J, Voigt C, Engel T, Josten C, Lill H. The surgical approach for locking plate osteosynthesis of displaced proximal humeral fractures influences the functional outcome. J Shoulder Elbow Surg. 2008;17:21-8.
 - Moonot P, Ashwood N, Hamlet M. Early results of three- and four-part fractures of proximal humerus using the PHILOS plate system. J Bone Joint Surg Br. 2007;89:1206-9.
 - Wild JR, De Mers A, French R, Shipps MR, Bergin PF, Musapatika D et al. Functional outcomes for surgically treated 3- and 4- part proximal humerus fractures. Orthop. 2011;34:e629-33.
 - Neer CS 2nd. Displaced proximal humeral fracture. I. Classification and evaluation. J Bone Joint Surg Am. 1970;52:1077-89.
 - Agudelo J, Schurmann M, Stahel P, Helwig P, Morgan SJ, Zechel W et al. Analysis of efficacy and failure in proximal humerus fractures treated with locking plates. J Orthop Trauma. 2007;21:676-81.
 - Wu CH, Ma CH, Yeh JJ, Yen CY, Yu SW, Tu YK. Locked plating for proximal humeral fractures: Differences between the deltopectoral and deltoid-splitting approaches. J Trauma. 2011;71:1364-70.
 - Isiklar Z, Kormaz F, Gogus A, Kara A. Comparison of deltopectoral versus lateral deltoid split approach in operative treatment of proximal humeral fractures. J Bone Joint Surg Br. 2010;92:352.
 - Court-Brown CM, Garg A, McQueen MM. The epidemiology of proximal humeral fractures. Acta Orthop Scand. 2001;72:365-71.
 - Robinson CM, Murray IR. The extended deltoid-splitting approach to the proximal humerus: Variations and extensions. J Bone Joint Surg Br. 2011;93:387-92.

Cite this article as: Anand R, Dwivedi A, Agarwal A, Shah F. Assessment of the outcome of fracture proximal humerus transdeltoid versus deltopectoral approach with PHILOS. Int J Res Orthop 2021;7:25-8.