

## Original Research Article

# Functional outcome of antegrade interlocking intramedullary nailing for humeral shaft fractures

Rajagopal H. P., Madan Mohan M.\*, Anoop Pilar, Keith Behram Tamboowalla

Department of Orthopaedics, St. John's Medical College Hospital, Sarjapur Road, Bangalore, Karnataka, India

**Received:** 22 August 2017

**Accepted:** 02 September 2017

**\*Correspondence:**

Dr. Madan Mohan M.,

E-mail: [drmadanmmohan@yahoo.co.in](mailto:drmadanmmohan@yahoo.co.in)

**Copyright:** © the author(s), publisher and licensee Medip Academy. This is an open-access article distributed under the terms of the Creative Commons Attribution Non-Commercial License, which permits unrestricted non-commercial use, distribution, and reproduction in any medium, provided the original work is properly cited.

### ABSTRACT

**Background:** Humeral shaft fractures which account for approximately 1-3% of all fractures and 20% of humeral fractures have potential to cause significant disability in the young which is often temporary and in the old often permanent disability. The use of locked intramedullary nailing for the treatment of humeral shaft fractures is gaining popularity because of its biomechanical and biological advantages.

**Methods:** We present a descriptive retrospective review of 20 consecutive patients with acute humeral shaft fractures treated using an antegrade interlocking nail. Fracture union, functional outcome measured with Constant–Murley shoulder score and American shoulder and elbow surgeons (ASES) shoulder score and complications were assessed.

**Results:** Patient age ranged from 20 to 74 years (average, 36 years) and average follow-up was 30.7 months (range, 12–48 months). There were 13 male patients and 7 female patients. Fracture of the middle third was most common accounting to 80% (16/20) of the fractures. Fracture union was achieved in 90% (18/20) of our cases. 2 patients had nonunion for which secondary surgeries were needed. According to Constant–Murley score, shoulder function was excellent in 70% (14/20) and good in 25% (5/20). Average ASES score was 93.3%. None of the patients had radial nerve palsy postoperatively.

**Conclusions:** Gentle progressive reaming, correct entry point, minimal damage to rotator cuff, properly embedding the tip of the nail, good apposition of fracture fragments, static locking will help make antegrade intramedullary nailing, a dependable solution for the treatment of humeral shaft fractures and in achieving successful union with preserved/good shoulder and elbow function.

**Keywords:** Closed reamed interlocking nail, Humeral shaft fractures, Antegrade

### INTRODUCTION

The humeral shaft cylindrical in shape, the expanse between the proximal insertion of the pectoralis major and the distal metaphyseal flare of the humerus, adds resistance to both torsional and bending forces and provides strength. Adequate soft tissue envelope favors good prognosis in healing of uncomplicated fractures.

Humeral shaft fractures account for approximately 1-3% of all fractures and 20% of humeral fractures with a bimodal distribution with peaks in young male patients, 21–30 years of age, and a larger peak in older females

from 60–80 years of age.<sup>1</sup> Most humeral diaphysis fractures are simple patterns of the mid-diaphysis

These fractures have potential to cause significant disability in the young which is often temporary and in the old often permanent disability.

Plating or intramedullary nailing are the main surgical options available for the definitive primary management of closed humeral shaft fractures and have their respective proponents with no consensus.

A statically locked nail (a nail with interlocking screws at either end for rotational stability) provides good rigidity against torsional forces, maintains length and preserves soft tissues at the fracture site. Shoulder pain and healing problems are complications reported.<sup>2-6</sup>

The objective of this investigation was to evaluate the clinical outcome with the use of an antegrade interlocking intramedullary nail for the humeral fractures.

## METHODS

Between 2012 and 2017, 20 consecutive patients with acute humeral shaft fractures who presented to emergency department of our institution, treated using an antegrade interlocking nail formed the study group, for this descriptive retrospective review. Closed diaphyseal unilateral humeral fractures, in patients older than 18 years were included. Open fractures, age under 18 years, pathological fractures and fractures associated with neurovascular injury were excluded.

All patients were treated with antegrade intramedullary interlocking nail through deltoid splitting anterolateral approach using standard technique. Entry point was identified under image intensification in the cartilage on medial slope of the notch next to greater tuberosity. The fibers of the supraspinatus tendon are carefully split and sutured after nail insertion. Fracture reduction was done by gentle manipulation and longitudinal traction. Gentle progressive reaming at increments of 0.5 mm was done over guidewire. Nails of diameter 7-8 mm, locked statically were used. All patients were advised on postoperative shoulder and elbow exercises. All received 3 doses of perioperative prophylactic antibiotics as per institution protocol.

Each patient's demography including mechanism of injury, associated injuries, time to radiographic union, shoulder and elbow function, patient satisfaction and complications including infection, iatrogenic nerve injury, delayed union and nonunion were recorded. All fractures were classified according to the AO (Arbeitsgemeinschaft für Osteosynthesefragen) classification. Clinical union was defined as absence of pain at the fracture site with return to full activities. Fracture healing was assessed by sequential plain radiographs obtained every six weeks, until evidence of fracture healing was confirmed. Radiological union was defined as cortical bridging of at least three of four cortices, and nonunion as failure of radiological union at six months, requiring surgical intervention. Constant–Murley shoulder score, and the American shoulder and elbow surgeons (ASES) score were used to assess functional outcomes. All patients were followed for a minimum of 12 months.

## RESULTS

Overall, 7 (35.0%) females, and 13 (65.0%) males, with an average age 36 years (range 20–74) were included in

the study group (Table 1). Right humerus was involved in 11 (55.0%) and left in 9 (45.0%). 16 of the fractures were in the middle third, 3 (13.5%) in the distal third and 1 in the proximal third (Table 2). AO type 12-A3 was the commonest type in this study. All were closed injuries. None of the patients had concomitant injury of the radial nerve. Mean hospital stay was 5 days (range 03–12). 10 patients were operated on the same day, 8 after 2 days and 2 after 5 days due to associated injuries. Mean duration of surgery was 52.3 minutes (range 40–74). Only one superficial wound infection at the entry point was encountered which got cured with minimal debridement and antibiotic therapy. No patients had complications of deep infection, radial nerve palsy, or implant failure in this series. 18 fractures (90%) healed after the initial procedure with an average time to union of 90 days (range 84–120) (Figures 1 and 2). At the final examination, the patients had a mean Constant–Morley score of 90.5 points (range 86–100 points) (Table 3). Average ASES score was 93.3%.

**Table 1: Study group.**

<b>Patients (fractures)</b>	20 (20)
<b>Sex (male/female)</b>	13 :07
<b>Age (average, range)</b>	36 years (20–74 years)
<b>Duration of follow-up (average, range)</b>	30.7 months (12–48 months)
<b>Fracture mechanism:</b>	
1. Fall on outstretched arm	4 (20%)
2. RTA	15 (75%)
3. Fall from height	1 (05%)

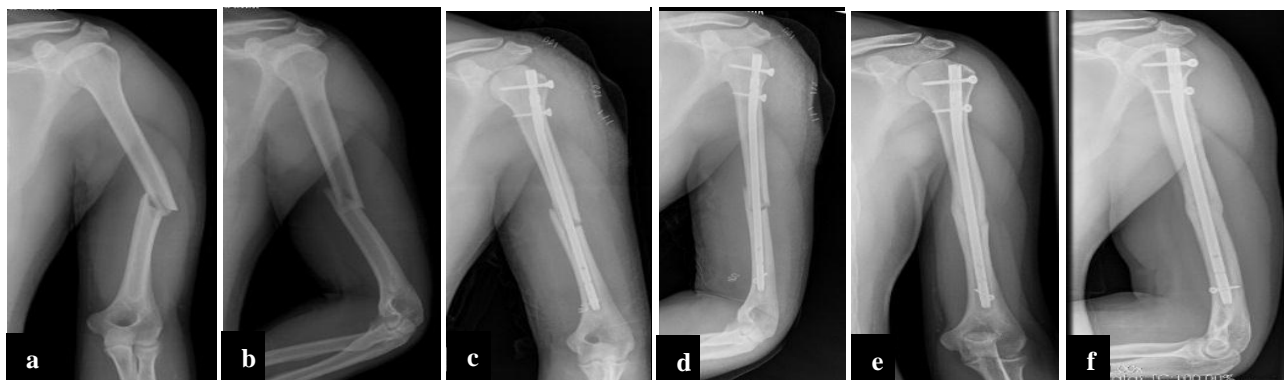
RTA- road traffic accident.

**Table 2: Fracture distribution according to the location and AO classification.**

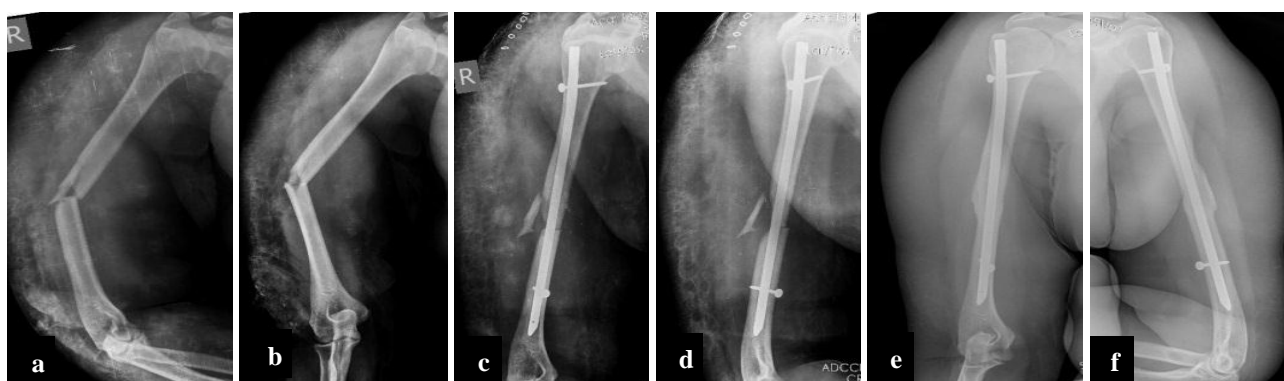
Fracture type	Proximal third	Middle third	Distal third	Total
<b>12-A1</b>	-	-	-	-
<b>12-A2</b>	1	3	1	5
<b>12-A3</b>	-	10	1	11
<b>12-B1</b>	-	-	-	-
<b>12-B2</b>	-	1	1	2
<b>12-B3</b>	-	-	-	-
<b>12-C1</b>	-	-	-	-
<b>12-C2</b>	-	2	-	2
<b>12-C3</b>	-	-	-	-
<b>Total</b>	1	16	3	20

**Table 3: Functional outcome after grading according to Constant–Murley shoulder score.**

Outcome	Number of patients (%)
<b>Excellent</b>	14 (70)
<b>Good</b>	5 (25)
<b>Fair</b>	1 (5)
<b>Poor</b>	0 (0)



**Figure 1: (a, b) Preoperative radiographs of oblique humeral shaft fracture (12-A2) in 22-year-old male patient fixed with intramedullary antegrade humeral nail; (c, d) Postoperative radiographs;(e, f) Bone consolidation at follow-up assessment at 10 months.**



**Figure 2: (a, b) Preoperative radiographs of 12-B2 type fracture in 44-year-old female patient; (c, d) Postoperative radiographs following locked intramedullary nailing; (e, f) Radiographs 46 months postoperatively showing good bone consolidation.**

## DISCUSSION

The shoulder joint (glenohumeral joint) the major joint connecting the upper limb to the trunk has an exceptional multiplanar range of motion significant tolerance to deformity after union. Function of the upper extremity is not affected even when there is up to 20° of anterior angulation, 30° of varus angulation, 15° of malrotation, and 3 cm of shortening of the humerus, which is the guide to continued conservative management.<sup>1</sup>

Majority of uncomplicated humeral shaft fractures can be managed non-operatively, with an expected union rate of more than 90% and continues to be the mainstay of treatment still.<sup>1</sup> Methods include functional bracing, hanging-arm casts, modified Velpeau dressings, coaptation splints, shoulder spica casts, and abduction-type splints. Sarmiento et al in 1977 described functional cast bracing with a moldable splint which allowed early return to activity, acceptable functional outcomes, and minimal morbidity.<sup>7</sup> Westrick et al in a retrospective cohort study of 296 patients with humeral shaft fractures found nonunion rate was significantly higher in the non-operative group (23.2% vs. 10.2%).<sup>8</sup>

Difficulty in immobilization due to the very much mobile scapulohumeral joint and distraction at fracture site by effects of gravity leading to delayed union and non-union, prolonged immobilization leading to joint stiffness, muscle weakness, less tolerance to acceptable deformity, impatient patients eager to return to early function and surgeons reluctance towards more labor-intensive methods of conservative management are cited for increasing trend for surgical management.<sup>9,10</sup>

Primary surgical management of humeral shaft fracture include plate fixation (open reduction and internal fixation [ORIF]), intramedullary nailing (IMN) or by external fixation. Accepted indications for surgery include open, segmental or pathological fractures, an adjacent floating joint, fractures with associated neurovascular injuries and inability to obtain and maintain adequate alignment.<sup>1,11</sup> External fixation is generally utilized as temporary fixation of open fractures or poly-trauma patients.

Direct fracture visualization allowing anatomical reduction and rigid fracture fixation are the cited advantages and an extensive open surgery with stripping

of soft tissues from the bone, increased blood loss, disruption of the periosteal blood supply, a longer operating time, risk of injury to radial nerve, and difficulty with complex fracture patterns and in osteoporotic bones, the possible need for plate removal at a later date are described as negative features for plate fixation.<sup>1,10,12</sup>

IMN stabilization offers an approach requiring less extensive dissection, minimal soft tissue disruption preserving the fracture hematoma, less blood loss, shorter operative times, and a lower incidence of serious complications such as radial nerve palsy. Recently many authors in prospective randomized studies, comparing IMN versus locking compression plates in treatment of humeral Shaft Fracture found intraoperative blood loss, operative time, hospital stay and average union time) were significantly lower in patients treated with IMN and no significant difference between the two groups in terms of union rate, shoulder function or complications.<sup>13-17</sup>

Shoulder pain and restriction of shoulder movements and risk of delayed union have been suggested as disadvantages of antegrade intramedullary fixation.<sup>18-20</sup>

Impairment of shoulder function with antegrade IMN could be due to rotator cuff violation, and subacromial impingement. Baltov et al in their retrospective review of 105 patients treated with antegrade approach reported telescopic effect in 5 (4.5%) patients with osteoporosis, incomplete embedding of the nail at surgery, leading to sub acromial impingement in 12 (10.8%) cases, and in 5 (4.5%) patients impingement of the head of proximal interlocking screw as complications leading to shoulder discomfort.<sup>5</sup> Verdano et al in a retrospective cohort of 48 patients investigating the clinical and sonographic impact on the rotator cuff (RC) of the use of the anterolateral approach for nailing found no significant clinical/sonographic impact on the rotator cuff.<sup>21</sup> In this series according to Constant–Murley score, shoulder function was good to excellent in 95%(19/20). Average ASES score was 93.3%. Many recent reports have reported similar shoulder dysfunction rates (rated according to ASES and or Constant–Murley scoring) less than 10% and have recommended medial entry point avoiding the avascular area of the cuff, meticulous surgical dissection, static locking of the nail to prevent backing out and complete embedding of the nail as technical tips to minimize cuff related problems and consequent shoulder dysfunction.<sup>17,22,23</sup>

Out of the 20 fractures, 18 united by the end of 6 months with an overall union rate of 90%. This result is comparable to the union rate achieved by Crates (94.5%), Fan (96.7%), Chapman (87%), Tsourvakas, (95.8%), Petsatodes (92.3%).<sup>6,13,18,22,23</sup> Reported nonunion rate in recent literature is 0-8%.<sup>17</sup> In our series, 2 patients had non-union. Gap at the fracture site was considered as the cause. Both healed with bone grafting. Good apposition of the fracture fragments, reaming where feasible, static

locking to add initial high biomechanical stiffness of the osteosynthesis allowing early mobilization, are recommended to reduce healing related complications.<sup>22</sup>

## CONCLUSION

Gentle progressive reaming, correct entry point, minimal damage to rotator cuff, properly embedding the tip of the nail, good apposition of fracture fragments, static locking will help make antegrade intramedullary nailing, a dependable solution for the treatment of humeral shaft fractures and in achieving successful union with preserved/good shoulder and elbow function.

*Funding: No funding sources*

*Conflict of interest: None declared*

*Ethical approval: The study was approved by the institutional ethics committee*

## REFERENCES

1. Spiguel AR, Steffner RJ. Humeral shaft fractures. *Curr Rev Musculoskelet Med.* 2012;5(3):177-83.
2. Rommens PM, Kuechle R, Bord T, Lewens T, Engelmann R, Blum J. Humeral nailing revisited. *Injury.* 2008;39:1319–28.
3. Farragos AF, Schemitsch EH, McKee MD. Complications of intramedullary nailing for fractures of the humeral shaft: a review. *J Orthop Trauma.* 1999;13:258–67.
4. Lin J, Shen PW, Hou SM. Complications of locked nailing in humeral shaft fractures. *J Trauma.* 2003;54(5):943–9.
5. Baltov A, Mihail R, Dian E. Complications after interlocking intramedullary nailing of humeral shaft fractures. *Injury.* 2014;45(Suppl 1):S9-15.
6. Crates J, Whittle AP. Antegrade interlocking nail of acute humeral shaft fractures. *Clin Orthop Relat Res.* 1998;350:40–50.
7. Sarmiento A, Kinman PB, Galvin EG, Schmitt RH, Phillips JG. Functional bracing of fractures of the shaft of the humerus. *J Bone Joint Surg Am.* 1977;59(5):596-601.
8. Westrick E, Hamilton B, Toogood P, Henley B, Firoozabadi R. Humeral shaft fractures: results of operative and non-operative treatment. *Int Orthop.* 2017;41(2):385-95.
9. Kulkarni SG, Varshneya A, Jain M, Kulkarni VS, Kulkarni GS, Kulkarni MG, et al. Antegrade interlocking nailing versus dynamic compression plating for humeral shaft fractures. *J Orthop Surg.* 2012;20(3):288–91.
10. Cole PA, Wijdicks CA. The operative treatment of diaphyseal humeral shaft fractures. *Hand Clin.* 2007; 23(4):437-48.
11. Carroll EA, Schweppe M, Langfitt M, Miller AN, Halvorson JJ. Management of humeral shaft fractures. *J Am Acad Orthop Surg.* 2012;20(7):423–33.



12. Walker M, Palumbo B, Badman B, Brooks J, Van Gelderen J, Mighell M. Humeral shaft fractures: a review. *J Shoulder Elbow Surg.* 2011;20(5):833-44.
13. Fan Y, Li Y, Zhang H, Liu J, Han X, Chang X, et al. Management of Humeral Shaft Fractures with Intramedullary Interlocking Nail Versus Locking Compression Plate. *Orthopedics.* 2015;38:825-9.
14. Kumar R, Singh P, Chaudhary LJ, Singh S. Humeral shaft fracture management, a prospective study; nailing or plating. *J ClinOrthop Trauma.* 2012;3(1):37-42.
15. Wali MGR, Baba AN, Latoo IA, Bhat NA, Baba OK, Sharma S. Internal fixation of shaft humerus fractures by dynamic compression plate or interlocking intramedullary nail: a prospective, randomised study. *Strategies Trauma Limb Reconstr.* 2014;9(3):133-40.
16. McCormack RG, Brien D, Buckley RE, McKee MD, Powell J, Schemitsch EH. Fixation of fractures of the shaft of the humerus by dynamic compression plate or intramedullary nail. A prospective, randomised trial. *J Bone Joint Surg Br.* 2000;82:336-9.
17. Changulani M, Jain UK, Keswani T. Comparison of the use of the humerus intramedullary nail and dynamic compression plate for the management of diaphyseal fractures of the humerus. A randomised controlled study. *Int Orthop.* 2007;31:391-5.
18. Chapman JR, Henley MB, Agel J, Benca PJ. Randomized prospective study of humeral shaft fracture fixation: intramedullary nails versus plates. *J Orthop Trauma.* 2000;14:162-6.
19. Flinkkilä T, Hyvönen P, Siira P, Hämäläinen M. Recovery of shoulder joint function after humeral shaft fracture: A comparative study between antegrade intramedullary nailing and plate fixation. *Arch Orthop Trauma Surg.* 2004;124:537-41.
20. Raghavendra S, Bhalodiya HP. Internal fixation of fractures of the shaft of the humerus by dynamic compression plate or intramedullary nail: a prospective study. *Indian J Orthop.* 2007;41:214-8.
21. Verdano MA, Pellegrini A, Schiavi P, Somenzi L, Concari G, Ceccarelli F. Humeral shaft fractures treated with antegrade intramedullary nailing: What are the consequences for the rotator cuff? *Int Orthop.* 2013;37(10):2001-7.
22. Tsourvakas S, Alexandropoulos C, Papachristos I, Tsakoumis G, Ameridis N. Treatment of humeral shaft fractures with antegrade intramedullary locking nail. *Musculoskelet Surg.* 2011;95(3):193-8.
23. Petsatodes G, Karataglis D, Papadopoulos P, Christoforides J, Gigis J, Pournaras J. Antegrade interlocking nailing of humeral shaft fractures. *J Orthop Sci.* 2004;9:247.

**Cite this article as:** Rajagopal HP, Madan Mohan M, Pilar A, Tamboowalla KB. Functional outcome of antegrade interlocking intramedullary nailing for humeral shaft fractures. *Int J Res Orthop* 2017;3:1127-31.