

## Original Research Article

# Comparative study of closed reduction vs. open reduction fixed with k-wiring in type 3 displaced supracondylar fractures in children

Mahesh D. V.\*, Deepak C. D., Abdul Ravoof, Shruthikanth

Department of Orthopaedics, Adichunchanagiri Institute of Medical Sciences, BG Nagara, Nagamangala Taluk, Mandya, Karnataka, India

**Received:** 29 May 2017

**Revised:** 26 July 2017

**Accepted:** 28 July 2017

**\*Correspondence:**

Dr. Mahesh D. V.,

E-mail: ra5555@rediffmail.com

**Copyright:** © the author(s), publisher and licensee Medip Academy. This is an open-access article distributed under the terms of the Creative Commons Attribution Non-Commercial License, which permits unrestricted non-commercial use, distribution, and reproduction in any medium, provided the original work is properly cited.

### ABSTRACT

**Background:** Among all the fractures in upper limb in children, supracondylar fractures of the humerus are more common injuries. In general the fractures of children are treated conservatively. But the management of supracondylar fractures has evolved over years from conservative to more aggressive approach operative techniques.

**Methods:** The study was conducted in children's presenting with type 3 Gartland supracondylar fractures to Adichunchanagiri Institute of Medical Sciences, B. G. Nagara between January 2014 to December 2016.

**Results:** The study consisted of 40 type 3 supracondylar fractures cases. Group A (closed reduction) had 25 cases, among them were 20 males and 5 were females. Group B (open reduction) had 15 cases among them 12 males and 3 female cases. The patients were between the age of 6 to 12 years. In Group A, 19 children were in the age group of 6-10 years where as Group B had 12 cases. In Group A, 6 were in the age group of 10-12 years and 3 cases in Group B. Among the 25 cases in Group A, 19 were left sided and 6 were right sided. In group B, 11 were left sided and 4 were right sided. All patients had achieved clinical and radiological union at 4 weeks.

**Conclusions:** Closed reduction and k-wiring had very good results for type 3 supracondylar fractures of humerus in children than conservative/open reduction methods. However for cases which we didn't get proper/satisfactory reduction in closed method, open method with triceps splitting approach was used.

**Keywords:** Type 3C supracondylar fractures, K-wiring, Closed reduction, Triceps splitting, Open reduction

### INTRODUCTION

Of all the fractures in the upper limb the supracondylar fracture of the humerus in children is not only the most common injury but results in serious complications if not treated appropriately. In general, fractures in children are treated conservatively. Surgical treatment is reserved for some physeal injuries, fractures associated with neurovascular compromise, open fractures and certain special circumstances like fractures around hip. The management of supra condylar fractures of humerus has evolved from a purely conservative approach to a more aggressive approach in recent years. Supra condylar

fractures need a precise treatment in order to obtain a satisfactory result because of low bone remodelling associated with these injuries. It is important to use a systematic procedure for acceptable outcome.<sup>1</sup>

Displaced and comminuted supracondylar fractures of humerus have always presented a challenge in their management.<sup>2</sup> Many methods have been proposed ranging from closed reduction and plaster cast immobilization, Dunlop's skin traction, skeletal traction, closed reduction and percutaneous pinning to open reduction and Kirschner wire fixation.<sup>3-5</sup> Treatment of this displaced fracture is fraught with many

complications including Volkmann's ischemic contracture, nerve injury, arterial injury, myositis - ossificans and cubitus varus deformity.<sup>6,7</sup>

Extension type fractures, which accounts for approximately 97-99% of supra condylar humeral fractures are usually due to fall on the out stretched hand with elbow in full in extension and management of undisplaced fractures is usually conservative, but the management of the completely displaced fracture is controversial.

**Objectives**

To compare the functional outcome of closed vs. open reduction and k-wiring of type III C (Gartland classification) supracondylar fracture humerus in children, accuracy of reduction and its radiological evaluation by Baumann's angle, to find out final range of movements of the elbow joint in terms of flexion and extension and to analyze the end results of surgery with respect to bony union.

**METHODS**

It is a comparative study of surgical management of supracondylar fractures treated by closed reduction vs. open reduction and K-wiring in children 6-12years. The patients admitted to the orthopedic department at Adichunchanagiri Institute of Medical Sciences, B. G. Nagar with supracondylar fractures during the period of January 2014 to December 2016 were selected. A sample size 40 patients operated during this period will be considered. All type 3C supracondylar fractures were screened selected accordingly.

**Selection criteria**

Inclusion criteria were children of age group between 5-15 years, type 3 {Gartland} displaced supracondylar humerus fractures and simple fractures.

Exclusion criteria were compound fractures, age group above 15 years and below 5 years, fractures associated with vascular injury and fractures associated with neurological injury.

**Table 1: Flynn's criteria.**

	Cosmetic factor carrying-angle loss (degrees)	Functional factor movement-loss (degrees)
Excellent	0 to 5°	0 to 5°
Good	5 to 10°	5 to 10°
Fair	10 to 15°	10 to 15°
Poor	>15°	>15°

**Statistical analysis:** Chi square test

**RESULTS**

Forty cases taken for this study have been categorized according to the age, sex, side of the limb. Group A (closed reduction) had 25 cases, among them were 20 males and 5 were females. Group B (open reduction) had 15 cases among them 12males and 3 female cases. The patients were between the age of 6 to 12 years. In Group A, 19 children were in the age group of 6-10 years where as Group B had 12. In Group A, 6 were in the age group of 10-12 years and 3 cases in Group B. Among the 25 cases in Group A, 19 were left sided and 6 were Right sided. In group B, 11 were left sided and 4 were right sided.

**Table 2: Case distribution among each group.**

Groups	Number of cases
<b>Group A(closed reduction)</b>	<b>25</b>
<b>Group B (open reduction)</b>	<b>15</b>

**Table 3: Sex distribution of each group.**

	Male	Female	Total
<b>Group A</b>	<b>20</b>	<b>05</b>	<b>25</b>
<b>Group B</b>	<b>12</b>	<b>03</b>	<b>15</b>

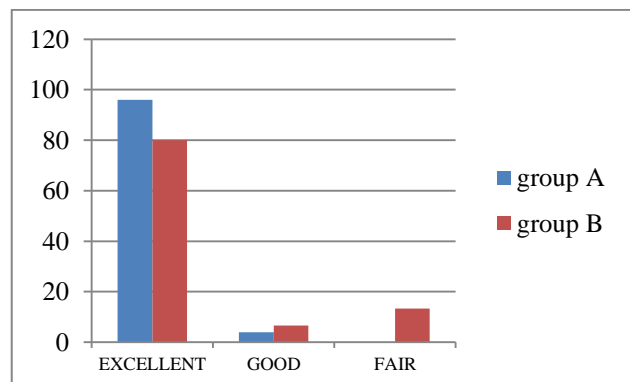
**Table 4: Age distribution of each group.**

	6-10 years	10-15 years
<b>Group A</b>	<b>19</b>	<b>06</b>
<b>Group B</b>	<b>12</b>	<b>03</b>

**Table 5: Side distribution in each group.**

	Left	Right
<b>Group A</b>	<b>19</b>	<b>06</b>
<b>Group B</b>	<b>11</b>	<b>04</b>

25 cases were operated using closed reduction and K-wiring under c-arm guidance. 15 cases were operated using open reduction with triceps splitting approach.



**Figure 1: Study results according to Flynn's criteria.**

In group A, of 25 cases, one had pin site infection which healed after k wires removal. One more case had elbow stiffness which improved with physiotherapy. In group B, out 15 cases, 3 cases had elbow stiffness. One case had superficial wound infection. Union rates were 4 weeks in both the groups.

In group A, 24 cases (96%) had excellent results and one had good results. In group B, 12 (80%) excellent results, one (6.6%) good results and fair results in 2 cases (13.3%).

## DISCUSSION

The observations of the present study were evaluated and compared with previous studies and analysis was as follows:

### *Age distribution*

The type 3 communitied supracondylar fractures of the humerus are commonly seen in children. The minimum age was 6.5 years (Group A), 7 years (Group B) and maximum age was 11.5 years in both.

### *Sex distribution*

There was male preponderance in the present study with 20 (80%) males and 5 (20%) females in Group A. In Group B, 12 (80%) cases were males 3 (20%) were females. The observations were similar to other studies.

### *Side affected*

Out of 25 patients in Group A, 19 (76%) were left and 6 (24%) cases were right supracondylar fractures. Out of 15 cases in Group B, 11 (73.4%) were left sided and 4 (26.6%) right sided. This shows higher preponderance in left than right side. The majority of the fractures were sustained due to fall from height.

### *Preoperative complications*

Two cases had superficial wound preoperatively over the operative site. 2 cases had upper respiratory infections due to which surgery was delayed.

### *Postoperative complications*

In group A, of 25 cases, one had pin site infection which healed after k wires removal. One more case had elbow stiffness which improved with physiotherapy. In group B, out 15 cases, 3 cases had elbow stiffness. One case had superficial wound infection.

### *Fracture union*

Out of 40 cases all went for good clinical and bony union. The average time of fracture union was 4 weeks.

### *Follow up protocol*

Patient was followed up every week. Postoperative X-rays were taken after 4 weeks. Fractures showed good union by 4 weeks and k-wires were removed. Later children were instituted with active movements till a week. If children didn't have good range of motion, Patient advised physiotherapy and reviewed regularly.

In a study by Mazda et al, a prospective study reported the results of 116 consecutive displaced extension supracondylar fractures of the elbow in children treated during the first two years after the introduction of the following protocol; closed reduction under general anesthesia with fluoroscopic control and lateral percutaneous pinning using two parallel pins or, when closed reduction failed, open reduction and internal fixation by cross-pinning. The protocol described resulted in good or excellent results in 96% of our patients, providing a safe and efficient treatment for displaced supracondylar fractures of the humerus even in less experienced hands.<sup>1</sup>

In a study by D'Ambrosia normal elbow motion resulted following each method of closed treatment but open reduction caused some loss in extension. Overhead threaded pin traction was safe and the swelling of the elbow rapidly decreased as gravity hastened venous and lymphatic drainage. Overhead pin traction prevented residual varus deformity possibly because it provided a position of mild pronation of the forearm. Closed reduction followed by a collar and Cuff also prevented residual varus deformity, possibly because of the neutral or pronated position of the forearm. In their opinion supinated position of the forearm should be avoided in the treatment of supracondylar fractures of the elbow in children.<sup>2</sup>

In a study by Flynn et al, percutaneous pinning after closed reduction of supracondylar fractures has got several advantages. Immediate fixation of these fractures reduces the duration of hospital stay. If the fracture is fixed immediately after closed reduction it can be splinted in a safe position without any fear of loss of reduction. This minimizes the risk of compartment syndrome and maximizes circulation.<sup>3</sup>

In a study conducted by Otsuka, they concluded that the treatment of type II and type III (Gartland's classification) supracondylar fractures of the humerus in children with closed reduction and percutaneous pinning has dramatically lowered the rate of complications from the injury. The incidence rates of malunion (cubitus varus) and compartment syndrome have both decreased.<sup>4</sup>

In a study conducted by Rijal, in their study concluded that percutaneous crossed K-wire pinning after closed manipulation in supracondylar extension type III fracture

of the humerus is a reliable and safe method of treatment and is recommended in all.<sup>5</sup>

In a study conducted by Sibinsk et al examined differences in the rate of open reduction, operating time, length of hospital stay and outcome between two groups of children with displaced supracondylar fractures of the humerus who underwent surgery either within 12 hours of the injury or later. The study confirmed that the treatment of uncomplicated displaced supracondylar fractures of the humerus can be early or delayed. In these circumstances operations at night can be avoided.<sup>6</sup>

In a study conducted by Devkota et al, found that closed reduction and percutaneous K- wire pinning in the management of supracondylar fractures of humerus in children is safe as regards avoidance of vascular complications, effective in obtaining good results and relatively economical regarding hospitalization. The disadvantage is the need for proficiency and the availability of C- arm fluoroscopy.<sup>9</sup>

In a study by Lewis et al, time of return of elbow motion after percutaneous pinning of pediatric supracondylar humerus fractures, observed loss of motion of 45° by 6 weeks and 22° by 12 weeks postoperatively, but there was substantial improvement with subsequent follow up. After closed reduction and percutaneous pinning of a displaced, uncomplicated, extension-type supracondylar humerus fracture, 94% of the child's normal elbow ROM should be expected by 6 months after pinning. Additional improvement may be anticipated to occur as much as 1 year after the injury.<sup>10</sup>

In a study conducted by Sial et al, in their study concluded that open reduction and crossed pin fixation is a sound and effective modality for the treatment of displaced supracondylar fractures with the advantages of decreased duration of hospital stay, anatomical reduction, stable fixation and early mobilization.<sup>11</sup>

## CONCLUSION

The study was conducted to show the results of surgical management of type 3 supracondylar fracture in children with closed reduction in Group A, open reduction in Group B and k-wiring. Supracondylar fractures of humerus are common in children. With type 3 supracondylar being more with high force like fall from height (26 cases-65%) being the most common mode of injury. Fractures were more common in the age group of 6-10 years (26 cases-80%) and average age was 8.7 years in Group A, 8.9 years in group B. Males were more commonly affected than female (in both the groups). In Group A, 24 cases (96%) had excellent results and one had results. In group B, 12 (80%) excellent results, one (6.6%) good results and fair results in 2 cases (13.3%). Closed reduction and K-wiring is a better modality for highly communitated supracondylar fractures in children. It

avoids stiffness of elbow, delayed soft tissue healing as compared to open methods. In group A, of 25 cases, one had pin site infection which healed after k wires removal. One more case had elbow stiffness which improved with physiotherapy. In Group B, out 15 cases 3 cases had elbow stiffness. One case had superficial wound infection. With correct anatomical knowledge, good reduction, strict adherence to AO principles and operative skills closed reduction and K-wiring for highly communitated supracondylar fractures is the better method of fixation.

*Funding: No funding sources*

*Conflict of interest: None declared*

*Ethical approval: The study was approved by the institutional ethics committee*

## REFERENCES

1. Mazda K, Boggione C, Fitoussi, GF. Penneçot Systematic pinning of displaced extension-type supracondylar fractures of the humerus in children J Bone Joint Surg. 2001;83:888-93.
2. Ambrosia RD. Supracondylar fractures of humerus – prevention of cubitus varus. J Bone J Surg Am. 1972;54:60–6 .
3. Flynn JC, Matthews JG, Benoit RL. Blind pinning of displaced supracondylar fracture of the humerus in children. Sixteen years' experience with long-term follow-up. J Boint J Surg Am. 1974;56:263–72.
4. Otsuka NY, Kasser JR. Supra condylar fractures of the humerus in children. J Am Acad Orthop Surg 1997;5(1):19–26.
5. Rijal KP, Pandey BK. Supracondylar extension type III fracture of the humerus in children: Percutaneous cross – pinning. Kathmandu University Med J. 2006;4(4):465–9.
6. Sibinski M, Sharma H, Bennet GC. Early versus delayed treatment of extension type-3 supracondylar fractures of the humerus in childrenJ Bone Joint Surg [Br]. 2006;88:380-1.
7. Walmsley P, Kelly MB, Robb JE, Annan IH. Porter Delay increases the need for open reduction of type-III supracondylar fractures of the humerus J Bone Joint Surg [Br]. 2006;88:528-30.
8. Devkota P, Khan JA, Acharya BM, Pradhan NMS, Mainali LP, Singh M, et al. Outcome of Supracondylar Fractures of the Humerus in Children Treated by Closed Reduction and Percutaneous Pinning. J Nepal Med Assoc. 2008;47(170):66–70.
9. Lewis EZ, Christopher JW, Nahid M, Charalampos Z. Time of Return of Elbow Motion after Percutaneous Pinning of Pediatric Supracondylar Humerus Fractures ,Clin Orthop Relat Res. 2009;467(8):2007–10.
10. Haque MR, Haque AM, Hamid F, Hossain MD. Displaced Supracondylar Fractures of the Humerus in Children: Treatment by Open Reduction and

Internal Fixation by Two Crossed Kirschner Wires.  
Dinajpur Med Col J. 2010;3(1):25–8.

11. Sanglim L, Moon SP, Chin YC, Dae GK, Ki HS, Tae WK. Consensus and Different Perspectives on Treatment of Supracondylar Fractures of the Humerus in Children. Clin Orthop Surg. 2012;4(1):91-7.

**Cite this article as:** Mahesh DV, Deepak CD, Ravoof A, Shruthikanth. Comparative study of closed reduction vs. open reduction fixed with k-wiring in type 3 displaced supracondylar fractures in children. Int J Res Orthop 2017;3:1010-4.