

Original Research Article

A study on management of paediatric supracondylar humerus fractures with lateral percutaneous Kirschner wire fixation

Wazir Fahad Jan^{1*}, Umer Mushtaq Khan², Haamid Rafiq Bhat³, Sumaya Zeerak⁴

¹Department of Orthopaedics, S.H.K.M., Government Medical College, Nalhar, Nuh, Haryana, India

²Department of Critical Care and Pain Medicine, Max Superspeciality Hospital, Delhi, India

³Department of Health, Delhi, India

⁴Department of Dermatology, Government Medical College, Srinagar, India

Received: 15 April 2019

Revised: 06 July 2019

Accepted: 17 July 2019

***Correspondence:**

Dr. Wazir Fahad Jan,

E-mail: fahadwzr@yahoo.com

Copyright: © the author(s), publisher and licensee Medip Academy. This is an open-access article distributed under the terms of the Creative Commons Attribution Non-Commercial License, which permits unrestricted non-commercial use, distribution, and reproduction in any medium, provided the original work is properly cited.

ABSTRACT

Background: Supracondylar fracture of the humerus in children is a common injury encountered in orthopaedic practice. Undisplaced fractures can be managed conservatively, however displaced fractures need proper reduction and adequate fixation for attainment of optimal functional and cosmetic outcomes. The purpose of this study was to evaluate the effectiveness of lateral percutaneous Kirschner (K) wire fixation in the management of displaced supracondylar fractures in relation to achievement of union and functional results.

Methods: This was a prospective observational study conducted on 70 patients of either sex with an average age of 5.98 years, presenting to the Orthopaedic Department of S.H.K.M. Government Medical College Hospital, Nalhar, Nuh, Haryana between February 2016 and February 2018, with displaced supracondylar fractures of humerus. All the patients were managed by closed reduction and percutaneous lateral K wire fixation. The patients were followed up for a period of 1 year. The patients were analyzed for union and functional results.

Results: All the fractures united with an average time of union of 3.8 weeks. Functional results were assessed using Flynn's criteria, which were excellent in 58 (82.86%), good in 7 (10%), fair in 3 (4.28%) and poor in 2 (2.86%) patients.

Conclusions: Thus results of our study demonstrate that the lateral percutaneous K wire fixation is a safe and effective method of treatment of displaced paediatric supracondylar humerus fractures.

Keywords: Supracondylar fracture, Kirschner wire, Percutaneous fixation

INTRODUCTION

Supracondylar fractures are the most frequent elbow injuries in children, reported to occur in 55% to 75% of patients with elbow fractures.^{1,2} The peak age of incidence of these fractures is between 5 and 7 years.^{3,4} Supracondylar fractures generally occur as a result of a fall onto the outstretched hand with the elbow in full extension.⁵ Increased ligamentous laxity has been correlated with the occurrence of supracondylar

fractures.⁶ Most distal humeral supracondylar fractures are displaced in extension,⁷ and flexion-type injuries are seen infrequently. These fractures represent a severe musculoskeletal injury and can cause severe complications like neurovascular compromise, compartment syndrome, Volkman's ischaemic contracture, malunion, angular deformities, myositis ossificans and loss of motion.⁸⁻²¹ Hence proper management of these fractures is essential to avoid these complications.

The treatment of supracondylar fractures is decided according to the classification system devised by Gartland.²² According to this classification system supracondylar fractures are classified into three types: type I- undisplaced, type II- displaced with intact posterior cortex and type III- displaced with no cortical contact. Type I fractures can be managed conservatively, while most of the type II and all type III fractures require proper reduction and fixation with Kirschner (K) wires.

In the present study we evaluated the effectiveness of effectiveness of lateral percutaneous K wire fixation in the management of displaced supracondylar fractures (type II and III) in relation to achievement of union and functional results.

METHODS

After approval by the institutional ethics committee and informed written consent, the study was started. This was a prospective observational study conducted on 70 patients of either sex with an average age of 5.98 years presenting to the Orthopaedic department of S.H.K.M. Government Medical College Hospital, Nalhar, Nuh, Haryana between February 2016 and February 2018, with displaced supracondylar fractures of humerus. The sex distribution was 38 males and 32 males.

Inclusion criteria

All the patients, i.e., children in the age group between 2 to 10 years, who had incurred displaced supracondylar humerus fractures (Gartland type II and type III) and injury to presentation interval up to 5 days were included.

Exclusion criteria

Patients in the age group <2 or >10 years, children with undisplaced supracondylar humerus fractures (Gartland type I), injury to presentation interval greater than 5 days, open fractures (Gustilo Anderson type II and III) and fractures associated with vascular injuries.

At presentation all the patients were thoroughly examined and neurovascular assessment was done. Standard anteroposterior and lateral radiographs of the elbow were obtained. Preliminary reduction was done and an above elbow plaster of Paris slab was applied. The patients were admitted and preoperative anaesthetic checkup was done.

The surgery was done as soon as possible usually within 24 hours of presentation. The surgical procedure was explained to the guardians of the patients and informed written consent was taken.

Procedure

After administration of general anaesthesia patients were placed in a supine position on the fluorescent operating table with the affected upper limb hanging by the side. With one assistant providing counter traction by grasping the proximal arm, longitudinal traction was given by grasping the forearm. Supination and pronation of the forearm was done to correct the rotational malalignment and translation of the distal fragment was carried out to correct the medio-lateral displacement. While maintaining traction, elbow was gently flexed, with gentle pressure on the olecranon with the thumb for correction of the posterior displacement of the distal fragment. Maximal flexion of the elbow and pronation of the forearm were done to lock the posterior and medial soft tissue hinges. Anteroposterior and lateral images of the elbow were taken by the image intensifier to confirm reduction. While maintaining reduction two lateral wires were inserted in such a fashion to exit above the medial epicondyle engaging both the fracture fragments. Proper placement of the K wires was confirmed under C arm. Wires were cut and bent in such a way, so that they do not migrate proximally. Radial pulse was checked. Antiseptic dressing was done and above elbow slab was applied. The patient was shifted out of the operation theatre.

Standard post-operative protocol was followed. On the first post-operative day dressing was changed, radiographs were taken and the patients were discharged. The patients were followed up weekly for the first month and monthly for one year. The wires and the plaster slab were removed after 3 weeks and the range of motion at elbow was started. The patients were followed up for one year and the data collected was subjected to analysis.

Statistical methods

The data was analysed with SPSS version 17.0 software. The demographic variables were assessed by number and percentage. Simple arithmetic mean was used for the description of the results of various values of time taken (in weeks) for union. Flynn's criteria were used for assessment of cosmetic and functional results (Table 1).

Table 1: Flynn's criteria for grading of functional and cosmetic results.

Results	Rating	Cosmetic factor: carrying angle loss (degrees)	Functional factor: motion loss (degrees)
Satisfactory	Excellent	0-5	0-5
	Good	5-10	5-10
	Fair	10-15	10-15
Unsatisfactory	Poor	>15	>15

RESULTS

This was a prospective observational study. The average age was 5.98 years. The study included 38 male and 32 female children. The mean time taken for union was 3.8 weeks.

The fractures of all the patients in this study united with an average duration of 3.8 weeks. Majority of the patients in our study at follow up had satisfactory functional and cosmetic outcomes according to Flynn's criteria. According to these criteria the results in our study were excellent in 58 (82.86%), good in 7 (10%), fair in 3 (4.28%) and poor in 2 (2.86%) patients. Of the two patients with poor results one patient had elbow stiffness which improved with continuous passive motion and physical therapy, while the other patient who developed cubitus varus deformity needed surgery in the form of corrective osteotomy. Three patients developed

superficial pin track infections which improved with antiseptic dressing and antibiotics.

Table 2: Age distribution.

Age in years	No. of patients	Percentage (%)
2-4	19	27.14
4-6	23	32.86
6-8	21	30.00
8-10	7	10.00
Total	70	100

Table 3: Sex distribution.

Gender	No. of patients	Percentage (%)
Male	38	54.28
Female	32	45.72
Total	70	100

Table 4: Observations of the study.

Parameters	Mean age of the patients in years	Mean time taken for union in weeks	Flynn's Grading in various patients, N (%)			
			Excellent	Good	Fair	Poor
Values of the parameters	5.98	3.8	58 (82.86)	7 (10)	3 (4.28)	2 (2.86)

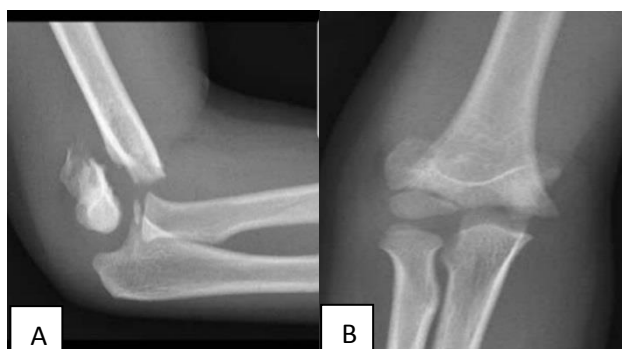

Figure 1: Radiograph of the elbow showing Gartland type III fracture. (A) Lateral view, (B) anteroposterior view.

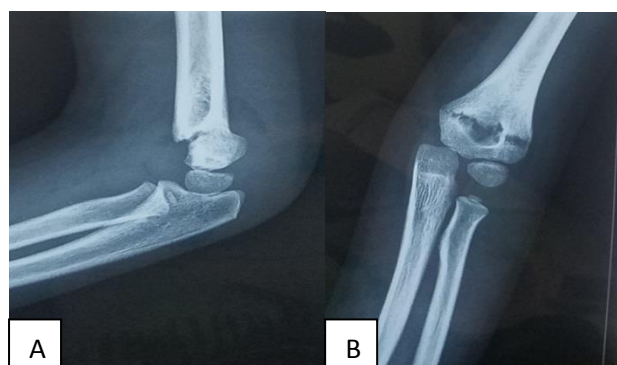


Figure 2: Radiograph of the elbow showing Gartland type II fracture. (A) Lateral view, (B) anteroposterior view.

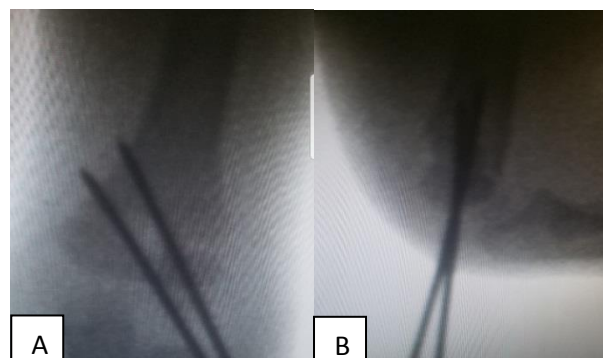


Figure 3: Radiograph of a Gartland type III fracture fixed with two lateral K wires. (A) Anteroposterior view, (B) lateral view.

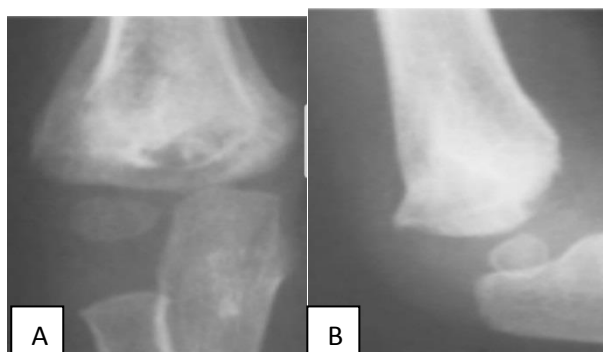

Figure 4: Radiograph of a united displaced supracondylar fracture after fixation with two lateral Kirchner wires at follow up. (A) Anteroposterior view, (B) lateral view.

DISCUSSION

Displaced supracondylar humerus fractures in children are a common clinical entity encountered in orthopaedic practice. Appropriate reduction and fixation of these fractures is essential for attainment of good functional and cosmetic results. Closed reduction and percutaneous pinning is now considered the treatment of choice for most displaced supracondylar fractures. The advantages of this treatment technique include less duration of hospital stay, preservation of circulation and decreased incidence of complications like infections, joint stiffness and compartment syndrome.²³ Several configurations of pins for fixation of these fractures have been used over the years. These include crossed medial and lateral pins, lateral parallel, convergent or divergent configurations. Lateral pin configuration has been found to be as stable as crossed pin configuration, while minimizing the risk of iatrogenic ulnar nerve injury.²⁴⁻²⁷

In our present study we evaluated the effectiveness of closed reduction and lateral percutaneous K wire fixation in the management of displaced supracondylar fractures (type II and III) in relation to achievement of union and functional results. Flynn's criteria (Table 1) were used for assessment of cosmetic and functional results.²³ This was a prospective observational study conducted on 70 patients of either sex with an average of 5.98 years, with displaced supracondylar humerus fractures (Figures 1 and 2). All the patients underwent closed reduction and percutaneous lateral K wire fixation (Figures 3). The fractures of all the patients in this study united (Figures 4) with an average duration of 3.8 weeks (Table 4). Majority of the patients in our study at follow up had satisfactory functional and cosmetic outcomes according to Flynn's criteria. According to these criteria the results in our study were excellent in 58 (82.86%), good in 7 (10%), fair in 3 (4.28%) and poor in 2 (2.86%) patients. Of the two patients with poor results one patient had elbow stiffness which improved with continuous passive motion and physical therapy, while the other patient, who developed cubitus varus deformity needed surgery in the form of corrective osteotomy. Three patients developed superficial pin track infections which improved with antiseptic dressing and antibiotics.

The results of our study are quite comparable to other studies done about this technique.²⁸⁻³⁰ In the study by Bhuyan the average time taken for union was 4 weeks and the Flynn's criteria were good to excellent in 97.47% of the patients and fair to poor in 2.52% of the patients.²⁸ These results favour quite favourably to our study. In the study by Sahu the average time taken for union was 4 weeks and the Flynn's criteria were 91.75% excellent, 7.05% good, 1.17% fair and no poor result, which is quite comparable to our study.²⁹ In the study by Sharma et al the average time taken for union was 4 weeks and the Flynn's criteria were 13.3% excellent, 60% good, 16.67% fair and 10% poor which compares quite favourably to our study.³⁰

CONCLUSION

From the above analysis, we can infer that the lateral percutaneous K wire fixation is a safe and effective method of treatment of displaced paediatric supracondylar humerus fractures with excellent rates of union and satisfactory functional and cosmetic results.

Funding: No funding sources

Conflict of interest: None declared

Ethical approval: The study was approved by the institutional ethics committee

REFERENCES

- Henrikson B. Supracondylar fracture of the humerus in children. A late review of end-results with special reference to the cause of deformity, disability and complications. *Acta Chir Scand Suppl.* 1966;369:1-72.
- Landin LA, Danielsson LG. Elbow fractures in children: an epidemiological analysis of 589 cases. *Acta Orthop Scand.* 1986;57:309.
- Cheng JC, Lam TP, Maffulli N. Epidemiological features of supracondylar fractures of the humerus in Chinese children. *J Pediatr Orthop B.* 2001;10(1):63-7.
- Houshian S, Mehdi B, Larsen MS. The epidemiology of elbow fracture in children: analysis of 355 fractures, with special reference to supracondylar humerus fractures. *J Orthop Sci.* 2001;6(4):312-5.
- Farnsworth CL, Silva PD, Mubarak SJ. Etiology of supracondylar humerus fractures. *J Pediatr Orthop.* 1998;18(1):38-42.
- Nork SE, Hennrikus WL, Loncarich DP. Relationship between ligamentous laxity and the site of upper extremity fractures in children: extension supracondylar fracture versus distal forearm fracture. *J Pediatr Orthop B.* 1999;8(2):90-2.
- McLauchlan GJ, Walker CR, Cowan B. Extension of the elbow and supracondylar fractures in children. *J Bone Joint Surg (Br).* 1999;81(3):402-5.
- Brown IC, Zinar DM. Traumatic and iatrogenic neurological complications after supracondylar humerus fractures in children. *J Pediatr Orthop.* 1995;15:440.
- Culp RW, Osterman AL, Davidson RS. Neural injuries associated with supracondylar fractures of the humerus in children. *J Bone Joint Surg.* 1990;72:1211.
- French PR: Varus deformity of elbow following supracondylar fractures of the humerus in children. *Lancet.* 1959;2:439.
- Labelle H, Bunnell WP, Duhaime M. Cubitus varus deformity following supracondylar fractures of the humerus in children. *J Pediatr Orthop.* 1982;2:539.
- Cramer KE, Green NE, Devito DP. Incidence of anterior interosseous nerve palsy in supracondylar

- humerus fractures in children. *J Pediatr Orthop.* 1993;13(4):502-5.
13. Campbell CC, Waters PM, Emans JB, Kasser JR, Millis MB. Neurovascular injury and displacement in type III supracondylar humerus fractures. *J Pediatr Orthop.* 1995;15(1):47-52.
 14. Copley LA, Dormans JP, Davidson RS. Vascular injuries and their sequelae in pediatric supracondylar humeral fractures: toward a goal of prevention. *J Pediatr Orthop.* 1996;16(1):99-103.
 15. Blount WP. Volkmann's ischemic contracture. *Surg Gynecol Obstet.* 1950;90:244-6.
 16. Bristow WR. Myositis ossificans and Volkmann's paralysis: notes on two cases, illustrating the rarer complications of supracondylar fracture of the humerus. *Br J Surg.* 1923;10:475-81.
 17. Dormans JP, Squillante R, Sharf H. Acute neurovascular complications with supracondylar humerus fractures in children. *J Hand Surg (Am).* 1995;20(1):1-4.
 18. Battaglia TC, Armstrong DG, Schwend RM. Factors affecting forearm compartment pressures in children with supracondylar fractures of the humerus. *J Pediatr Orthop.* 2002;22(4):431-9.
 19. Dowd GS, Hopcroft PW. Varus deformity in supracondylar fractures of the humerus in children. *Injury.* 1979;10(4):297-303.
 20. Chess DG, Leahey JL, Hyndman JC. Cubitus varus: significant factors. *J Pediatr Orthop.* 1994;14(2):190-2.
 21. Smith L. Deformity following supracondylar fractures of the humerus. *J Bone Joint Surg.* 1960;42:235.
 22. Gartland JJ. Management of supracondylar fractures of the humerus in children. *Surg Gynecol Obstet.* 1959;109:145.
 23. Flynn JC, Matthews JG, Benoit RL. Blind pinning of displaced supracondylar fracture of the humerus in children. Sixteen years' experience with long-term follow-up. *J Bone Joint Surg Am.* 1974;56:263-72.
 24. Skaggs DL, Hale JM, Bassett J, Kaminsky C, Kay RM, Tolo VT. Operative treatment of supracondylar fractures of the humerus in children. The consequences of pin placement. *J Bone Joint Surg Am.* 2001;83:735-40.
 25. Reynolds RA, Jackson H. Concept of treatment in supracondylar humeral fractures. *Injury* 2005;36(1):51-6.
 26. Mostafavi HR, Spero C. Crossed pin fixation of displaced supracondylar humerus fractures in children. *Clin Orthop Relat Res.* 2000;376:56-61.
 27. Woratanarat P, Angsanuntsukh C, Rattanasiri S, Attia J, Woratanarat T, Thakkinstian A. Meta-analysis of pinning in supracondylar fracture of the humerus in children. *J Orthop Trauma.* 2012;26:48-53.
 28. Bhuyan BK. Close reduction and percutaneous pinning in displaced supracondylar humerus fractures in children. *J Clin Orthop Trauma.* 2012;3(2):89-93.
 29. Sahu RL. Percutaneous lateral Kirschner wire fixation in pediatric supracondylar fractures of humerus. *J Orthop Traumatol Rehabil.* 2013;6:78-83.
 30. Sharma A, Walia JP, Brar BS, Sethi S. Early results of displaced supracondylar fractures of humerus in children treated by closed reduction and percutaneous pinning. *Indian J Orthop.* 2015;49:529-35.

Cite this article as: Jan WF, Khan UM, Bhat HR, Zeerak S. A study on management of paediatric supracondylar humerus fractures with lateral percutaneous Kirschner wire fixation. *Int J Res Orthop* 2019;5:911-5.