

Original Research Article

Evaluation of clinical results and complications of internal fixation of intertrochanteric femur fracture with proximal femoral nail antirotation

Manish Raj, S. P. S. Gill*, Akashdeep Singh, Ajay Kumar Rajput, Santosh Kumar Singh

Department of Orthopaedics, Uttar Pradesh University of Medical Sciences, Saifai, U. P., India

Received: 20 January 2019

Revised: 07 February 2019

Accepted: 08 February 2019

***Correspondence:**

Dr. S. P. S. Gill,

E-mail: simmygill@gmail.com

Copyright: © the author(s), publisher and licensee Medip Academy. This is an open-access article distributed under the terms of the Creative Commons Attribution Non-Commercial License, which permits unrestricted non-commercial use, distribution, and reproduction in any medium, provided the original work is properly cited.

ABSTRACT

Background: The purpose of the present study was to evaluate the theoretical advantages of the proximal femoral nail antirotation in cases of intertrochanteric fractures and also whether it actually alters the eventual functional outcome of the patient.

Methods: The present study includes a total 30 patients with intertrochanteric femur fractures managed with proximal femoral nail antirotation between December 2014 to November 2016. In all patients similar standard physical rehabilitation therapy were followed. All complications including intra and postoperative were assessed and recorded. The patients were followed up for over 24 months. Functional outcome was assessed using the Harris hip score.

Results: All of 30 cases of intertrochanteric fracture got united with good anatomical position and average time of fracture union was 14 weeks. Postoperative complications included 2 degree varus deformity (n=1, 3%), calcification at tip of greater trochanter (n=4, 13%), sensitivity over TFL (n=2, 7%), medial thigh pain (n=3, 10%). 10 patients developed femoral shortness (mean=0.22 cm, range from 0-1 cm). Average harris hip score at the end of study showed mean value of 87, ranged from 65 to 94 with almost 22 (73%) patients showing excellent or good outcome.

Conclusions: Proximal femoral nail antirotation (PFNA) represents a significant treatment option in management of intertrochanteric fractures with low complication rate.

Keywords: Intertrochanteric fracture, Internal fixation, Proximal femoral nail antirotation, Clinical results, Complications

INTRODUCTION

Trochanteric fractures are one of the most common injuries sustained predominantly in patients over sixty years of age. They are 3 to 4 times more common in women who are osteoporotic; trivial fall being the most common mechanism of injury.¹ The greatest problems for the orthopaedic surgeon treating this fracture are instability and the complications of fixation that result from instability. The type of implant used has an important influence on complications of fixation. Sliding

devices like the dynamic hip screw have been extensively used for fixation. However, if the patient bears weight early, especially in comminuted fractures, these devices can penetrate the head or neck, bend, or separate from the shaft.²

Intramedullary devices like the proximal femoral nail have been reported to have an advantage in such fractures as their placement allowed the implant to lie closer to the mechanical axis of the extremity, thereby decreases the lever arm and bending moment on the implant.

Intramedullary nail carry an advantage over other load-sharing devices by not having to depend on plate fixation with bone screws purchasing a compromised lateral cortex.^{3,4}

More recently, a new generation of proximal femoral nails with helical blades had been developed, featuring a large contact area and compression between the blade and the cancellous bone promoting better stability against varus collapse, especially in patients with osteoporotic bones.⁵⁻⁸ The aim of the present study was to evaluate the clinical results and complications of internal fixation of intertrochanteric fractures with the proximal femoral nail antirotation.

METHODS

This study was conducted on 30 patients presented with intertrochanteric femur fracture between December 2014 to November 2016 in department of orthopaedics, Uttar Pradesh university of medical sciences (UPUMS), Saifai. The present study was conducted after obtaining the permission from ethical committee of the institute. All patients with inter-trochanteric femur fractures and who were able to walk prior to the fracture were included in the study. However, patients with pathological fracture, active infection, unstable medical illness and non-traumatic disorder were excluded from the study. Patients with comorbid conditions like diabetes, peripheral vascular disease or chronic osteomyelitis were excluded in this study.

The patients were evaluated as per the history; mode of injury, necessary radiological investigations and haematology profile was done on admission. The 30 patients with intertrochanteric fractures were fixed with proximal femoral nail antirotation. The length of the incision, duration of surgery, blood loss and fluoroscopy time was recorded intraoperatively. The immediate post-operative X-rays were evaluated. Patients were mobilized non weight bearing as soon as the pain or general condition permitted. Weight bearing was commenced depending upon the stability of the fracture and adequacy of fixation, delaying it for patients with unstable or inadequate fixation. All the cases were again evaluated through clinical and radiological methods at 6 weeks, 12 weeks, 6 months and 1 year for any morbidity and mortality. Radiographs of affected hip were obtained in A.P and lateral planes at each follow up visit and any changes in position of implant and extent of fracture united were noted. Fractures were judged to be radiographically if bridging callus was evident on 3-9 cortices as noted on 2 views. Functional outcome was assessed using the Harris hip score.

RESULTS

The present study consists of 30 cases of intertrochanteric femur fractures. All the cases were fixed using proximal femoral nail antirotation. The study period

was from December 2014 to November 2016. The age of the patients ranged from 54 to 86 with fracture most common in the 5th and 6th decade and on average age of 69 years. Out of 30 patients, 17 (57%) patients were females and 13 (43%) patients were males showing female preponderance because of osteoporosis being a common problem among postmenopausal women. In our study, 22 (73%) patients sustained injury following trivial fall on ground, 5 (17%) sustained injury due to fall from height and 3 (10%) met road traffic accident. The mean time from injury to surgery time was 5.3 days, ranging from 2 to 10 days. Out of 30 cases treated with PFNA 3 (10%) took <49 minutes, 5(17%) took 50-59 minutes, 10 (33%) took 60-69 minutes, 8(27%) took 70-79 minutes and 4 (13%) took >80 minutes. The average time duration was 63 minutes with ranging from 45-85 minutes. The average blood loss was 96 ml, ranged from 60 to 180 ml. Out of 30 cases, average post-operative hospital stay was of 5.6 days, ranged from 4 to 14 days. Out of 30 cases operated, 10 cases suffered shortening in affected side averaged about 0.22 cm ranged from 0 to 1 cm. None of the patient had deep infection or failure or breakage due to implant fatigue. Secondary surgery was not required in any patient.

Table 1: Showing characteristics of internal fixation of intertrochanteric fracture with PFNA.

Characteristics	Findings
Age (years)	68.3±11.12
Sex (M:F)	13:17
Duration of surgery (minutes)	67±14
Intra-operative blood loss (ml)	105±18
Duration of fracture union (weeks)	14±2.1
Femoral shortness	0.22±0.01

Table 2: Showing postoperative complications.

Complications	Number of patients	%
Varus collapse	1	3
Calcification at tip of greater trochanter	4	13
Sensitivity over TFL	2	7
Medial thigh pain	3	10
Femoral shortness	10	34

At the end of study of 30 cases, average follow up was of 14.3 months ranging from 11 to 18 months. Out of 30 cases of intertrochanteric femur fractures managed by proximal femoral nail antirotation, 6 (20%) patients had excellent outcome, 16 (53%) had good results, 6 (20%) had fair outcome and 2 (7%) patients had a poor result. Average Harris hip score at the end of study showed mean value of 87, ranged from 65 to 94 with almost 22 (73%) patients showing excellent or good outcome and 100% fractures got united with a good component position and average time to bone healing was 14 weeks (range 12-22 weeks). There was no intra-operative complication or mortality encountered. Migration of

screws into acetabulum was not observed in any of the patient. In 4 patients, there was ectopic new bone formation at insertion point of stabilizing and compression screw but this does not affect the patient's condition. Post-operative complications included 2 degree varus deformity (n=1, 3%), calcification at the tip of greater trochanter (n=4, 13%), sensitivity over TFL (n=2, 7%). Medial thigh pain (n=3, 10%). 10 patients developed femoral shortness (mean=0.22 cm, range from 0-1 cm).

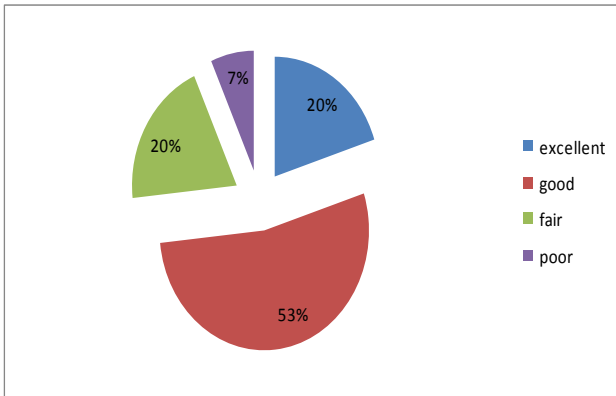


Figure 1: Showing Harris hip score at the end of study.

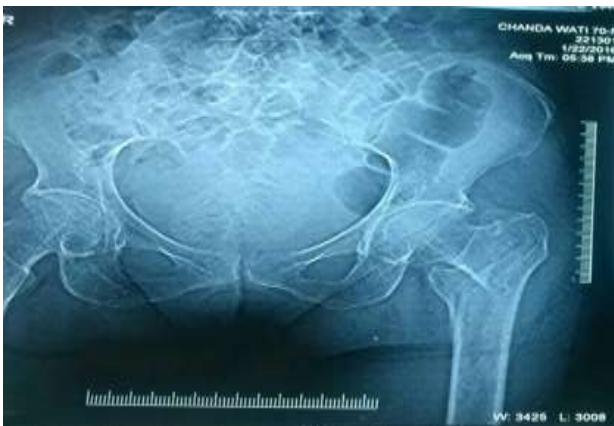

Figure 2: Pre-operative X-ray showing intertrochanteric fracture left femur.

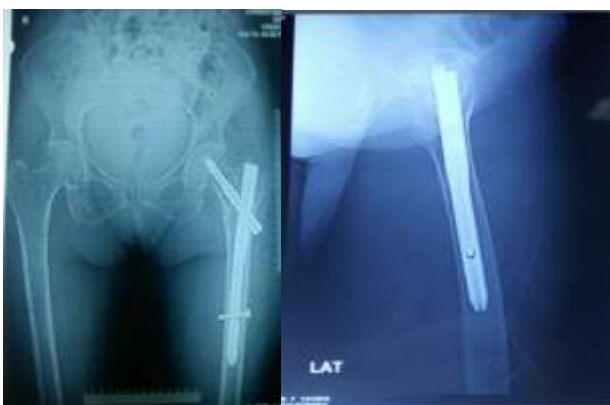

Figure 3: Immediate postoperative X-ray showing internal fixation with PFNA.

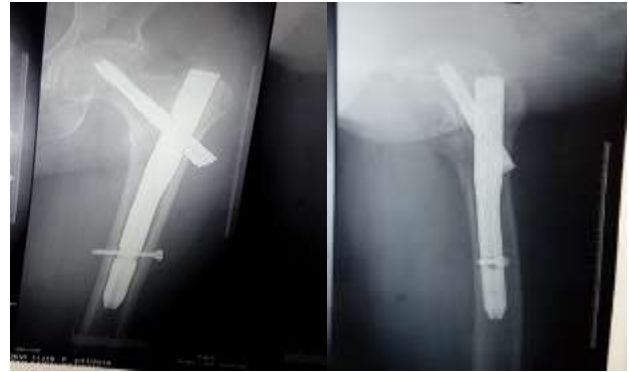

Figure 4: X-ray showing osseous union at fracture site.

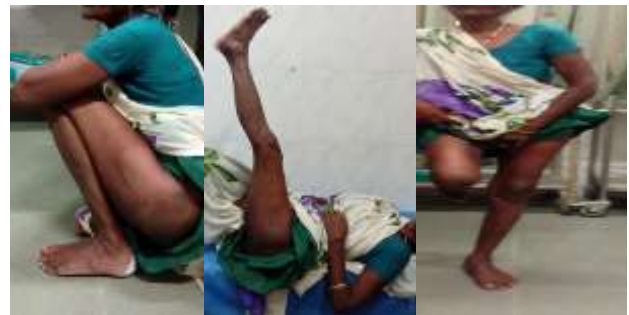

Figure 5: Clinical photographs showing full range of movements achieved.

DISCUSSION

The incidence of unstable intertrochanteric fracture is increasing and this trend is likely to continue. These fractures are challenging for an average orthopaedic surgeon. Treatment modalities include osteosynthesis with dynamic hip screws and cephalomedullary nails and in selected cases, arthroplasty. However, the choice of implant for unstable intertrochanteric fractures is still debatable. Fixation of unstable intertrochanteric fractures with dynamic hip screw is associated with excessive displacement of the fracture, leading to meadilization of the femoral shaft and lateralization of the greater trochanter resulting in shortening of the limb and thus the lever arm of the abductor mechanism of the hip, leading to abnormal hip biomechanics.²

The first generation intramedullary nails had a shorter lever arm, to decrease tensile strain on the implant, the lack of requirement of an intact lateral cortex, the improved load transfer (as a result of medial location), the potential for closed fracture reductions, percutaneous insertion, shorter operative time, and reduced blood loss are theoretical advantage of intramedullary devices compared with compression hip screw devices.³⁻⁵

The first generation nail for treatment of intertrochanteric fracture, the gamma nail, was associated with a relatively high incidence of peri-implant fracture of 2.2% to 1.7% approximately 4 times greater than seen with

compression hip screws.^{5,9} Nail geometry and size were contributing factors. A large (10 degree) valgus bend, long (200 mm) length without an anterior bow, and relative stiffness caused by large proximal (17 mm) and distal (12-16 mm) diameters all provided for increased stress concentration at the tip of the nail.¹⁰ The rate of cut out of these first generation nails, 2% to 4.3% was no better than that seen with compression hip screw devices, 2.5%.^{6,9} Changes to implant geometry, a reduced valgus bend to 4 degree, a decrease in the distal diameter to 11 mm and shortening of the length to 180 mm decreased the stress concentration at the tip of second generation gamma nails.¹⁰ The rate of peri implant fracture reduced with these second-generation devices to between 0% and 4.5%.⁹

The third generation nails such as the proximal femoral nail (PFN), which incorporates multiple screws into the femoral head, have been introduced. Multiple points of fixation theoretically provide better rotational control of unstable fractures compared with a single lag screw. The theoretical concern about smaller diameter screws was, screw cut-out directly related to their decreased diameter that could be exacerbated by screw bending. Fracture of the smaller superior screws has been seen, especially when it is placed near the subchondral bone of the femoral head. In this position, it encounters large varus stress that are not shared by the large inferior screws.¹⁰ Unstable proximal femoral fractures were treated successfully with proximal femoral nail antirotation (PFNA). Insertion of the blade compacts the cancellous bone. These characteristics provide optimal anchoring and stability when the implant is inserted into osteoporotic bone and had been biomechanically proven to retard rotation and varus collapse. The inserted PFNA blades achieve an excellent fit through bone compaction and require less bone removal compared to a screw.⁵ PFNA are now favoured in west and there are multiple studies coming from that region to support this.⁵⁻⁸ Very few studies exist on this subject from Indian population.

Sahin et al in their study conducted on 45 patients who underwent osteosynthesis using the PFNA for unstable intertrochanteric femoral fractures found high union rate, early post-operative mobilization, and shorter operation time.⁷ Zeng et al in their study of thirteen RCT involving 958 cases found that PFNA for intertrochanteric fractures is superior to dynamic hip screw in regards to the mean duration of surgery, mean intra-operative blood loss, the rate of post-operative complication, and the rate of post-operative fixation failure.¹⁴

Kumar et al in their study conducted on 42 patients of unstable intertrochanteric fractures fixed with PFNA presents with less operative time and low complication rate. However, proper operative technique is important for achieving stability and to avoid major complications.¹⁵

Sadic et al retrospectively analysed 113 consecutive patients with intertrochanteric fractures treated with proximal femoral nail antirotation, suggested that PFNA offers advantages, as it can be easily inserted and provides stable fixation, which allows early mobilization of the patient.¹⁶ Therefore, early operation, good reposition, strict respect of technical steps and stable fixation will result in good functional recovery.

In our study patients treated with PFNA had a significantly lower pain score at the sixth month of follow up. No cases of implant breakage and fatigue were seen during the follow up period. The helical blade effectively decreased the incidence of cut out. Due to advantages of high union rate, early post-operative mobilization and short operation time, PFNA osteosynthesis is the method of choice for surgical treatment of intertrochanteric femoral fractures.

The main limitation of our series was small number of patients, lack of control group, and absence of data relating the functional outcome with the bone quality of the patient.

CONCLUSION

In our study of unstable intertrochanteric fractures treated with PFNA, we found good outcome with very few complication rate and high union rate with short operative time and early post-operative mobilization.

Funding: No funding sources

Conflict of interest: None declared

Ethical approval: The study was approved by the institutional ethics committee

REFERENCES

1. Kaufer H. Mechanics of the treatment of Hip Injuries. *Clin Orthop.* 1980;146:53-61.
2. Davis TRC, Sher JL, Horsman A, Simpson M, Porter BB, Checketts, RG. Intertrochanteric femoral fractures. Mechanical failure after internal fixation. *J Bone Joint Surg.* 1990;72:26-31.
3. Adams CI, Robinson CM, Court -Brown CM, Mcqueen MM. Prospective randomized controlled trial of an intramedullary nail versus dynamic screw and plate for intertrochanteric fractures of the femur. *J Orthop Trauma.* 2001;15:394-400.
4. Hardy DC, Descamps PY, Krallis P, Fabeck L, Smets P, Bertens CL. Use of an intramedullary hip-screw compared with a compression hip screw with a plate for intertrochanteric femoral fractures. A prospective randomized study of one hundred patients. *J Bone Joint Surg.* 1998;80:618-30.
5. Mereddy P, Kamath S, Ramakrishnan M, Malik H, Donnachi N. The AO/ASIF proximal femoral nail antirotation (PFNA): A new design for the treatment of unstable proximal femoral fractures. *Injury.* 2009;40(4):428-32.

6. Pu J, Liu L, Wang G, Yue Fang, Yang T. Results of the proximal femoral nail anti-rotation (PFNA) in elderly chinese patients. *International Orthopaedics*. 2009;33:1441-4.
7. Sahin S, Erturer E, Ozturk I, Toker S, Seckin F, Akman S. Radiographical and functional results of osteosynthesis using the proximal femoral nail antirotation (PFNA) in the treatment of unstable intertrochanteric femoral fractures. *Acta Orthop Traumatol Turc*. 2010;44(2):127-34.
8. Kristel D, Lovric I, Kristek J, Biljan M, Kristek G, Sakic K. The PFNA in the treatment of intertrochanteric fractures. *Coll Antropol*. 2010;3(3):937-40.
9. Lorich DG, Geller DS, Nielson JH. Osteoporotic pertrochanteric hip fractures. Management and current controversies. *J Bone Joint Surg*. 2004;86:398-410.
10. Ricci WM. New Implants for the treatment old Intertrochanteric femur fractures. *Tech Orthop*. 2004;19:143-52.
11. Sarmiento A. Intertrochanteric fractures of the femur. 150 degree angle nail plate fixation and early rehabilitation – A preliminary report of 100 cases. *J Bone Joint Surg*. 1963;45:706-22.
12. Sarmiento A, Williams EM. The unstable intertrochanteric fracture: treatment with a valgus osteotomy and I-beam nail-plate. A preliminary report of one hundred cases. *J Bone Joint Surg*. 1970;52A:1309-18.
13. Clawson DK. Trochanteric fractures treated by the sliding screw plate fixation method. *J Trauma*. 1964;4:737-52.
14. C Zeng. Treatment of Trochanteric fractures with proximal femoral nail antirotation or dynamic hip screw systems: a meta-analysis. *J Int Med Res*. 2012;40:839-51.
15. Kumar GN, Sharma G, Khatri K, Farooque K, Lakhota D, Sharma V, et al. Treatment of unstable intertrochanteric fractures with proximal femoral nail antirotation: Our experience in Indian patients. *Open Orthop J*. 2015;9:456-9.
16. Sadic S, Custovic S, Jasarevic M, Fazlic M, Krupic F. Proximal femoral nail antirotation in treatment of intertrochanteric hip fractures: a Retrospective study in 113 patients. *Med Arh*. 2015;69(6): 353-6.

Cite this article as: Raj M, Gill SPS, Singh A, Rajput AK, Singh SK. Evaluation of clinical results and complications of internal fixation of intertrochanteric femur fracture with proximal femoral nail antirotation. *Int J Res Orthop* 2019;5:283-7.