

Original Research Article

Tennis elbow brace and wrist cock-up splint in the management of tennis elbow: a comparative study

Sandeep Gavhale, Harshit Dave, Hitesh Rohra*, Vipul D. Shet, Ganesh Aher, Sagar Bansal

Department of Orthopaedics, Grant Medical College and Sir J.J. Group of Hospitals, Byculla, Mumbai, Maharashtra, India

Received: 15 April 2020

Revised: 16 May 2020

Accepted: 03 June 2020

***Correspondence:**

Dr. Hitesh Rohra,

E-mail: hrohra.hr@gmail.com

Copyright: © the author(s), publisher and licensee Medip Academy. This is an open-access article distributed under the terms of the Creative Commons Attribution Non-Commercial License, which permits unrestricted non-commercial use, distribution, and reproduction in any medium, provided the original work is properly cited.

ABSTRACT

Background: The purpose of our study was to compare the efficacy of a wrist splint with a forearm counterforce strap brace in the management of tennis elbow.

Methods: This prospective study was conducted between January and December 2018 comprising of 75 patients suffering from lateral epicondylitis managed conservatively with splints. Patients were randomized into three treatment groups, group 1 received tennis elbow forearm brace, group 2 received wrist extension splint, group 3 received both tennis elbow forearm brace and wrist extension splint. The patient-rated tennis elbow evaluation (PRTEE) score and visual analogue scale (VAS) scores were calculated at 0, 3 and 6 weeks of the treatment.

Results: Mean difference of pre-treatment and post-treatment PRTEE score was significant in all three groups and was maximum for group 3 patients (32.42) followed by group 2 patients (27.04) followed by group 1 patients (20.06). Pre-treatment and post-treatment VAS score difference was maximum for group 3 patients.

Conclusions: Significant symptomatic relief can be achieved in patients with tennis elbow by using either tennis elbow forearm brace or wrist extension splint or both. Provided proper patient selection and compliance, wrist extension splint achieves better symptomatic relief and functional outcome as compared to tennis elbow brace.

Keywords: Tennis elbow, Lateral epicondylitis, Tennis elbow brace, Cock up splint, Brace

INTRODUCTION

Lateral epicondylitis or tennis elbow is the most common cause of lateral elbow pain affecting mainly middle-aged patients. It is characterized by pain in the region of the lateral epicondyle of the humerus which is aggravated during resisted dorsiflexion of the wrist, supination and power grip.¹ With an annual incidence of 1-3% in the general population, it could lead to a substantial loss of labour due to the pain experienced by the patients.² It typically occurs during the 4th and 5th decades of life without gender disposition.² It is caused by inflammation of the common extensor origin on the lateral epicondyle of the humerus, with resultant microtears and histologic

changes of angio-fibroblastic hyperplasia.³ The extensor carpi radialis brevis (ECRB) and the extensor digitorum communis (EDC) have been implicated as the most commonly affected tendons. Conservative treatment strategies have been aimed at relieving inflammation through rest, local ice application, activity modifications, pain killers, splints, injections, and more recently, extracorporeal shock wave therapy. Nonoperative treatment of lateral epicondylitis is successful in 70-80% of cases at 1 year.⁴

Different types of braces and orthotic devices have been developed and popularized for the treatment of tennis elbow. The most commonly used devices include a brace

placed around the muscle bellies of the wrist extensors and a wrist extension splint (Figure 1). Both these braces have been used successfully with significant symptomatic relief. The purpose of our study was to compare the efficacy of a wrist splint with a forearm counterforce strap brace in the management of tennis elbow.

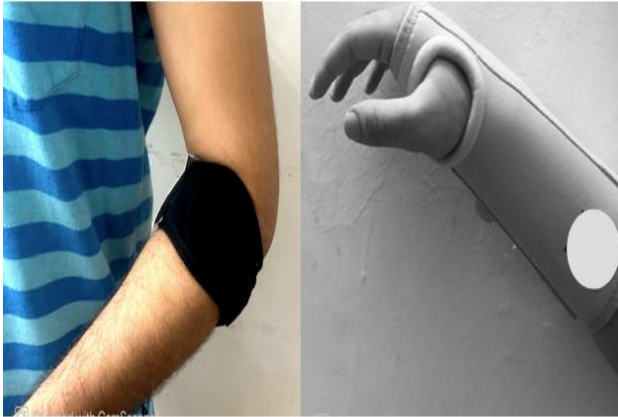


Figure 1: Tennis elbow brace and cock up splint.

METHODS

This prospective study was conducted in a tertiary care centre (Grant Medical College and Sir J.J. Group of Hospitals) between January and December 2018 comprising of 75 patients suffering from lateral epicondylitis managed conservatively with splints. Patients were selected based on inclusion and exclusion criteria.

Inclusion criteria

Inclusion criteria were tenderness on palpation over the lateral extensor origin. Pain with resisted wrist and long finger extension.

Exclusion criteria

Exclusion criteria were who had received prior treatments such as physical therapy, bracing, or steroid injections within the last 6 months. Patients with cervical radiculitis or compressive neuropathies. Elbow radiographs positive for arthritis or other pathology.

Patients were randomized into three treatment groups - group 1 received tennis elbow forearm brace, group 2 received wrist extension splint and group 3 received both tennis elbow forearm brace and wrist extension splint.

The patients were informed on the use and application of the braces according to a standard protocol and were instructed to wear their braces continuously. In the event of discomfort, patients were allowed to take off their braces for no longer than an hour. They were permitted to resume daily activities as much as their braces allowed but were warned to stay away from vigorous activities as well

as sports that could overload wrist extensors. In addition to bracing, patients were advised local ice application. Analgesics and anti-inflammatory medications were not formally prescribed for the patients during the study period; however, patients were allowed to take occasional over the counter paracetamol as needed.

Patients were followed up clinically at the end of the third and sixth weeks of the treatment. Data was collected through verbal communication and clinical examination. The patient-rated tennis elbow evaluation (PRTEE) score and visual analogue scale (VAS) scores were noted at 0, 3 and 6 weeks of the treatment.⁵

Statistical analysis

Mean and standard deviation of pre-treatment and post-treatment PRTEE score were calculated for each group and compared using the paired t-test for significance. P value less than 0.05 was considered significant. Mean difference between pre-treatment and post-treatment PRTEE score was also calculated for each group.

RESULTS

Out of 75 consecutive patients with lateral epicondylitis who presented to our outpatient department, 39 were male and 36 were females. The average age of the patients was 46 years with men having an average age of 45.4 and females having an average age of 47.3. 26 patients were daily laborer by occupation, 24 were household workers, 12 were drivers and 13 had a desk job. The average duration of symptoms at presentation was 4.24 weeks (Figure 2, Tables 1-3). Patients were randomized in three treatment groups and were followed up for 6 weeks and their pre-treatment and post-treatment PRTEE scores were calculated at 0, 3 and 6 weeks.

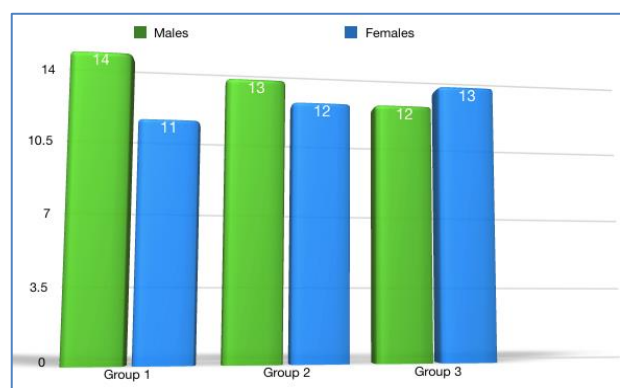


Figure 2: Distribution of patients according to age.

Group 1

Mean pre-treatment PRTEE score was 75.26 and post-treatment score was 55.2 with pre- and post-treatment score difference being 20.06. T score was -19.26 with p value being less than 0.00001 (significant).

Group 2

Mean pre-treatment score was 75.5 and the post-treatment score was 48.5 with pre- and post-treatment score difference being 27.04. T score was -22.72 with p value being less than 0.00001 (significant).

Group 3

Mean pre-treatment PRTEE score was 74.2 and post-treatment score was 41.84 with pre- and post-treatment score difference being 32.42. T score was -32.9 with p value being less than 0.00001 (significant).

Table 1: Distribution of patients according to age.

Groups	Mean age in years (males)	Mean age in years (females)
Group 1	44.86	48.18
Group 2	46.38	43.66
Group 3	45.08	49.84
Overall average	45.4	47.3

Mean difference of pre-treatment and post-treatment PRTEE score was maximum for group 3 patients (32.42) who were given both tennis elbow forearm brace and wrist extension splint followed by group 2 patients (27.04) who were given only wrist extension splint followed by group

1 patients (20.06) who were given tennis elbow forearm brace (Table 4).

Table 2: Distribution of patients according to occupation.

Occupation	Group 1	Group 2	Group 3
Household	7	9	8
Laborer	7	8	8
Driver	5	4	4
Desk job	6	4	5

Table 3: Distribution of patients according to average duration of symptoms at presentation.

Groups	Average duration of symptoms at presentation
Group 1	4.48
Group 2	4.32
Group 3	3.92
Overall average	4.42

VAS scores were also determined for all the patients in each group at 0, 3 and 6 weeks. Pre-treatment and post-treatment VAS score difference of 3 was observed in group 1, a difference of 3.5 was observed in group 2 and a difference of 4.5 was observed in group 3.

Table 4: Mean, standard deviation and mean difference of pre-treatment and post-treatment PRTEE scores of three groups.

Variables	Tennis elbow forearm brace		Wrist extension splint		Tennis elbow forearm brace and wrist extension splint	
	Mean	SD	Mean	SD	Mean	SD
Pre-treatment score at 0 weeks	75.26	4.82	75.5	2.8	74.2	4.71
Post-treatment score at 6 weeks	55.2	4.57	48.5	5.17	41.84	2.46
Difference of pre- and post-treatment score	20.06		27.04		32.42	
P value	<0.00001	<0.00001	<0.00001	<0.00001	<0.00001	<0.00001

DISCUSSION

The essential goal of lateral epicondylitis treatment is to gain a rapid return to the full functioning of the affected elbow. Conservative treatment strategies have been aimed at relieving inflammation and is successful in 70-80% of cases at 1 year.⁴ In our clinical study, we investigated the effectiveness of different braces in the treatment of lateral epicondylitis. We have found that both tennis elbow forearm brace and wrist extension splint are effective with wrist extension splint slightly superior to forearm splint in symptomatic relief.

Counterforce strap bracing was introduced by Ilfeld in 1965, but Nirschl coined the term ‘counterforce’ in reference to a nonelastic strap to prevent the full muscular

expansion of the proximal forearm.^{6,7} Electromyographic (EMG) studies have confirmed reduced EMG activity in the forearm musculature treated with the forearm support band.⁸ In a more recent study, Meyer et al showed that a force reduction of 13-15% in the origin of ECRB could be obtained with forearm support applying adequate compression.⁹ Two mechanisms of action for the forearm brace have been suggested most frequently in the literature. According to the first theory, the band inhibits full muscle contraction by constricting the forearm musculature. Inhibition of muscle expansion decreases the magnitude of muscle contraction and tension at the musculotendinous unit proximal to the band is consequently reduced. The second theory suggests that the support band applies direct compression over the extensor carpi radialis brevis (ECRB) muscle belly. This

compression supposedly creates a compressive adhesion or secondary origin which leads to the unloading of the extensor origin at the lateral epicondyle.

The main goal of resting splints is to hold the wrist extensor muscles in a position of rest. One possible theory explaining this finding is that the wrist splint allows improved immobilization of the wrist extensors in the resting position. Jansen et al investigated the amount of electrical activity in the wrist extensors by electromyography during activity with and without the wrist splint and discovered a significant decrease in electrical activity using the splint during lifting activities compared to no splint.¹⁰ Additionally, the wrist extension splint is generally visible and serves as a constant reminder to avoid using that arm, possibly allowing better pain relief than the forearm strap. Furthermore, the wrist splint prevents passive stretching of the extensor tendons, thus contributing to pain relief.

Several studies have compared bracing to other treatment modalities, and there is a lack of evidence for the long-term benefit of physical interventions in general.¹¹ In a randomized controlled trial, Struijs et al evaluated the clinical outcome and cost-effectiveness of 140 patients receiving either physical therapy, elbow strap bracing, or a combination of both for the treatment of lateral epicondylitis at a minimum 1-year follow-up.¹² No clinically relevant or statistically significant differences were found between the groups regarding pain and function.

Despite the frequent use of braces, no definitive evidence is present in the current literature concerning their effectiveness. Only one study focusing on the comparison of two different types of splints in lateral epicondylitis treatment was found in our literature survey. Streek et al compared a forearm hand splint with a simple elbow band and found no difference between them.¹³

In our study, a significant improvement for all parameters at 6 weeks was obtained in all the three group patients. Although the mean difference of pre-treatment and post-treatment score was maximum for patients who were given both tennis elbow forearm brace and wrist extension splint, patient compliance was a major concern. Proper counselling was inevitable in patients who were given wrist extension splint.

CONCLUSION

Significant symptomatic relief can be achieved in patients with tennis elbow by using either tennis elbow forearm brace or wrist extension splint or both. Provided proper patient selection and compliance, wrist extension splint achieves better symptomatic relief and functional outcome as compared to tennis elbow brace.

Funding: No funding sources

Conflict of interest: None declared

Ethical approval: The study was approved by the institutional ethics committee

REFERENCES

1. Struijs PA, Smidt N, Arola H, Dijk VCN, Buchbinder R, Assendelft WJ. Orthotic devices for tennis elbow: a systematic review. *Br J Gen Pract.* 2001;51(472):924-9.
2. Buchanan BK, Varacallo M. Tennis Elbow (Lateral Epicondylitis). In: *Stat Pearls.* Treasure Island (FL): Stat Pearls Publishing; 2019.
3. Regan W, Wold LE, Coonrad R, Morrey BF. Microscopic histopathology of chronic refractory lateral epicondylitis. *American J Sports Med.* 1992;20(6):746-9.
4. Boyer MI. Lateral tennis elbow: Is there any science out there. *J Shoulder Elbow Surg.* 1999;8(5):481-91.
5. Rompe JD, Overend TJ, Dermid MJC. Validation of the patient-rated tennis elbow evaluation questionnaire. *J Hand Therapy.* 2007;20(1):3-11.
6. Ilfeld FW, Field SM. Treatment of tennis elbow: use of a special brace. *JAMA.* 1966;195(2):67-70.
7. Nirschl RP. Tennis elbow. *Orthop Clin North Am.* 1973;4:747-400.
8. Mackler SL, Epler M. Effect of standard and air cast tennis elbow bands on integrated electromyography of forearm extensor musculature proximal to the bands. *American J Sports Med.* 1989;17(2):278-81.
9. Meyer NJ, Walter F, Haines B, Orton D, Daley RA. Modelled evidence of force reduction at the extensor carpi radialis brevis origin with the forearm support band. *J Hand Surg.* 2003;28(2):279-87.
10. Jansen CW, Olson SL, Hasson SM. The effect of use of a wrist orthosis during functional activities on surface electromyography of the wrist extensors in normal subjects. *J Hand Ther.* 1997;10:243-9.
11. Bisset L, Paungmali A, Vicenzino B, Beller E. A systematic review and meta-analysis of clinical trials on physical interventions for lateral epicondylalgia. *Br J Sports Med.* 2005;39:411-22.
12. Struijs PA, Bos KIB, Tulder VMW, Dijk VCN, Bouter LM, Assendelft WJ. Cost effectiveness of brace, physiotherapy, or both for treatment of tennis elbow. *British J Sports Med.* 2006;40(7):637-43.
13. Streek MV, Schans CV, Greef MD, Postema K. The effect of a forearm/hand splint compared with an elbow band as a treatment for lateral epicondylitis. *Prosthetics Orthotics Int.* 2004;28(2):183-9.

Cite this article as: Gavhale S, Dave H, Rohra H, Shet VD, Aher G, Bansal S. Tennis elbow brace and wrist cock-up splint in the management of tennis elbow: a comparative study. *Int J Res Orthop* 2020;6:813-6.