

## Original Research Article

# Short-term functional results of surgical management of fractures of olecranon process of ulna by locking hook plate

Maruti B. Lingayat<sup>1</sup>, Altamash Patel<sup>1\*</sup>, Chandrakant R. Thorat<sup>2</sup>

<sup>1</sup>Department of Orthopaedics, GMCH, Aurangabad, Maharashtra, India

<sup>2</sup>Department of Orthopaedics, GMCH, Dhule, Maharashtra, India

**Received:** 07 February 2021

**Revised:** 12 July 2021

**Accepted:** 13 July 2021

### \*Correspondence:

Dr. Altamash Patel,

E-mail: altamashpatel01@gmail.com

**Copyright:** © the author(s), publisher and licensee Medip Academy. This is an open-access article distributed under the terms of the Creative Commons Attribution Non-Commercial License, which permits unrestricted non-commercial use, distribution, and reproduction in any medium, provided the original work is properly cited.

## ABSTRACT

**Background:** The aim was to study functional results of fixation of fractures of olecranon process of ulna by locking hook plate.

**Methods:** The study was conducted on 30 patients who underwent fixation of olecranon fracture by locking hook plate in department of orthopaedics, GMCH Aurangabad from September 2018 to September 2020. Patients were assessed functionally using Mayo elbow performance score and radiologically using serial follow up radiographs of elbow.

**Results:** At 2 year follow up of 30 patients of all types of olecranon fracture treated by locking hook plate, no patient had evidence of non-union or loss of reduction or any other major complications. In our study 21 patients (70%) showed excellent results, 6 patients (20%) showed good results and 3 patients (10%) showed fair results. None of the patients in our study showed poor results. 3 patients (10%) had superficial infection which were treated by adequate antibiotics after doing culture and sensitivity testing and 4 patients (13.33%) had symptomatic metal prominence which underwent implant removal after union of fracture.

**Conclusions:** Fixation of all types of fractures of olecranon by locking hook plate is good alternative to other methods of fixation like tension band wiring, intramedullary fixation using screw tension band wiring which are used only in selected cases. In our study we conclude that locking hook plate is excellent modality of treatment for all types of fractures of olecranon, it gives excellent functional and radiological outcome with minimal complication and stable fixation of all types of fractures including transverse as well as comminuted fractures.

**Keywords:** Olecranon fractures, Olecranon locking hook plate, Open reduction and internal fixation

## INTRODUCTION

Olecranon fractures are one of the most commonly seen orthopaedic injuries in the emergency room. Fractures of the olecranon process of the ulna typically occurs as a result of a motor-vehicle or motorcycle accident, a fall or assault. Non displaced fractures can be treated with a short period of immobilization followed by gradually increasing range of motion. When displaced, open reduction and internal fixation are usually required to obtain anatomical realignment of the articular surface and restore normal

elbow function. The fixation should be stable, allow active elbow flexion and extension and promote union of the fracture.<sup>1</sup> In the past, closed reduction and plaster cast application was the treatment for fracture of olecranon. But prolonged immobilization with its own complications increased the morbidity and mortality of patients.<sup>2</sup> So keeping this in consideration, it has become important to intervene surgically. The active mobilisation after surgery will restore the patient to normal function as early as possible. The early and active movement not only prevents the tissue from fracture disease but greatly influences the

quality and rapidity of fracture union.<sup>3</sup> For comminuted fractures, distal fractures involving coronoid process, oblique fractures, transverse fracture plate fixation is most appropriate mode of treatment. For comminuted fractures and non-unions, a dorsally applied olecranon hook plate is used.<sup>1,3,4</sup> Olecranon fractures are relatively common injuries, accounting for approximately 10% of upper extremity fractures in adults. These fractures may result from a direct blow to the proximal ulna or indirectly via the forceful contraction of the triceps against resistance (typically, during a fall onto an outstretched hand). Less commonly, the olecranon may fracture when the elbow is hyper extended as the bone is impacted against the olecranon fossa of the distal humerus. For unstable injuries, operative fixation typically is required. Even after recovery, loss of range of motion is not uncommon. This article provides an overview of olecranon fractures in adults, therefore, discussion of olecranon fractures in skeletally immature patients is beyond the scope of this article. The olecranon is the region of the proximal ulna that extends from the tip of the ulna to the coronoid process. Three main anatomic features must be recalled when treating fractures of the olecranon. First, the olecranon is the site of insertion of the triceps, a muscle whose action would tend to displace a fracture. Second, the trochlear notch of the olecranon forms a cavity in which the distal humerus sits and thus all olecranon fractures, by definition, are intraarticular injuries. Third, the posterior process of the olecranon prevents posterior translation of the humerus (just as the coronoid process prevents anterior translation) and thus displacement can lead to elbow instability. Olecranon fractures typically are seen in young individuals after high energy trauma or in the elderly after low-energy falls. Although olecranon fractures most commonly occur as isolated injuries, it is essential to evaluate all patients for other injuries. Specifically, injuries to the ipsilateral extremity must be identified, including elbow fracture dislocations, as these injuries may alter the treatment plan and result in higher rates of fracture non-union, pain.

## **METHODS**

### ***Inclusion criteria***

Adults with age of >18 years, radiologically diagnosed fractures of olecranon process of ulna and consent to participate in the study were included in the study.

### ***Exclusion criteria***

Patients with open fractures, fractures of olecranon process with compartment syndrome needing fasciotomy, fractures of olecranon process with vascular injury needing vascular repair and refusal to provide informed consent were excluded from the study.

All patients with fractures of olecranon process of ulna admitted in department of orthopaedics, government medical college and hospital Aurangabad were evaluated

for a period of 2 years following fixation by locking hook plate. Functional evaluation was done using Mayo elbow performance score and also radiological evaluation was done by taking anteroposterior and lateral views of elbow. It was prospective study conducted from September 2018 to September 2020. Patient coming to OPD and casualty of GMCH Aurangabad were selected for our study.

### ***Surgical technique***

The operative site was scrubbed and painted with betadine solution one night prior to surgery to minimize chances of infection.

### ***Anaesthesia***

The operation was performed under general anaesthesia or brachial block. Position and tourniquet-mid arm tourniquet was applied with patient in lateral position. Site of the surgery was thoroughly painted with betadine and spirit and draped.

### ***Exposure***

Exposure of the olecranon was done by Campbell's posterolateral approach. A vertical incision was taken over the posterior aspect of the elbow about 2.5 cms proximal to olecranon, curving distally along the lateral aspect of olecranon reaching the subcutaneous border of the ulna and extending distally for about 7.5 cms distal to olecranon. Fascia was incised along the line of skin incision and fracture site was exposed. Fracture haematoma was cleared off and the fracture site was gently curettage. Accurate anatomical hairline reduction was achieved and held with either reduction clamp or with the help of nonthreaded 2.5 mm k wires for temporary stabilization. 3.5 mm olecranon locking hook plate was applied on the posterior surface with 3.5 mm cortical non locking and locking screws after drilling and tapping and hook of the plate was inserted directly on olecranon process after splitting the tendon of triceps brachi to avoid the complication of postoperative metal prominence and screw was inserted through hole in hook region into the canal of ulna giving additional stability and thereby preventing back out of plate. Thorough wash was given, wound closed in layers and sterile dressing was applied.

### ***Post op protocol***

All the patients were treated with injection cefotaxime 1 gm twice daily for 5 days followed by tablet cefixime 200 mg daily for 5 days. Anti-inflammatory, analgesics, injection diclofenac for 3 days followed by tablet diclofenac 50 mg twice daily then as and when needed was given for management of postoperative pain. Affected limb was elevated and patient was asked to perform finger movements on day 1. Elbow movements were advised from 3rd postoperative day. For comminuted fractures and unstable fixations, the limb was immobilized in A/E Plaster of Paris posterior slab with elbow in 90 degree

flexion for 2 weeks. For other fractures, the limb was mobilized by about 3rd postoperative day. First check dressing done on 4th postoperative day. Alternate suture removal done on 11th postoperative day. Complete suture removal done on 13th postoperative day.

In our study the patients on discharge were advised to report for follow up after 6 weeks and 12 weeks and thereafter every 3 months. The result was assessed 3 months after the procedure. At follow up a detailed clinical examination was done and patient was assessed subjectively for the symptoms like pain, swelling, restriction of joint motion. On clinical examination, swelling of the joint, tenderness, condition of surgical site, any discharge or presence of infection, movements of the elbow joint, prominence of head of cancellous screw or prominence of the part of hook plate, nutrition and power of the muscles acting on the joint were noted. Patients were instructed to carry out physiotherapy in the form of, active flexion-extension and pronation-supination without loading. Check X-ray were taken and patients followed up to look for adequate union at fracture site. In all patients duration after which they returned to job was noted.

All patients treated by olecranon fractures were evaluated by using Mayo elbow performance score for functional outcome and standard radiographs of anteroposterior and lateral views of elbow for radiological assessment.

**RESULTS**

Total number of patients evaluated in our study were 30 and they were followed up for a period of one year. Age group of patients in our study was between 21 to 60 years with average age of 40.5 years. In our study males were 20 and females were 10 (Table 1 and 2).

**Table 1: Age incidence.**

Age (in years)	21-30	31-40	41-50	51-60
No. of cases	6	12	5	7
Percentage	20	40	16.66	23.33

**Table 2: Sex incidence.**

Sex	No. of cases	Percentage
Male	20	66.66
Female	10	33.33

In our study 19 patients showed involvement of right side and 11 patients showed involvement of left side.

Most common mechanism of injury was road traffic accident 16 cases (53.33%), while 13 patients (43.33%) had fall from height and 1 patient (3.33%) had history of assault.

Also 24 patients (80%) had oblique and transverse fracture, 5 patients (16.66%) had comminuted fracture while 1 patient (3.33%) had avulsion fracture.

22 patients (73.33%) had union of fracture in less than 4 months while 8 patients (26.66%) had union between 4-6 months. No patient in our study showed non-union which was positive finding.

Functional results were evaluated using Mayo elbow performance score which showed excellent results in 21 patients (70%), good result was found in 6 patients (20%), fair result was found in 3 patients (10%). None of the cases showed poor result (Table 3).

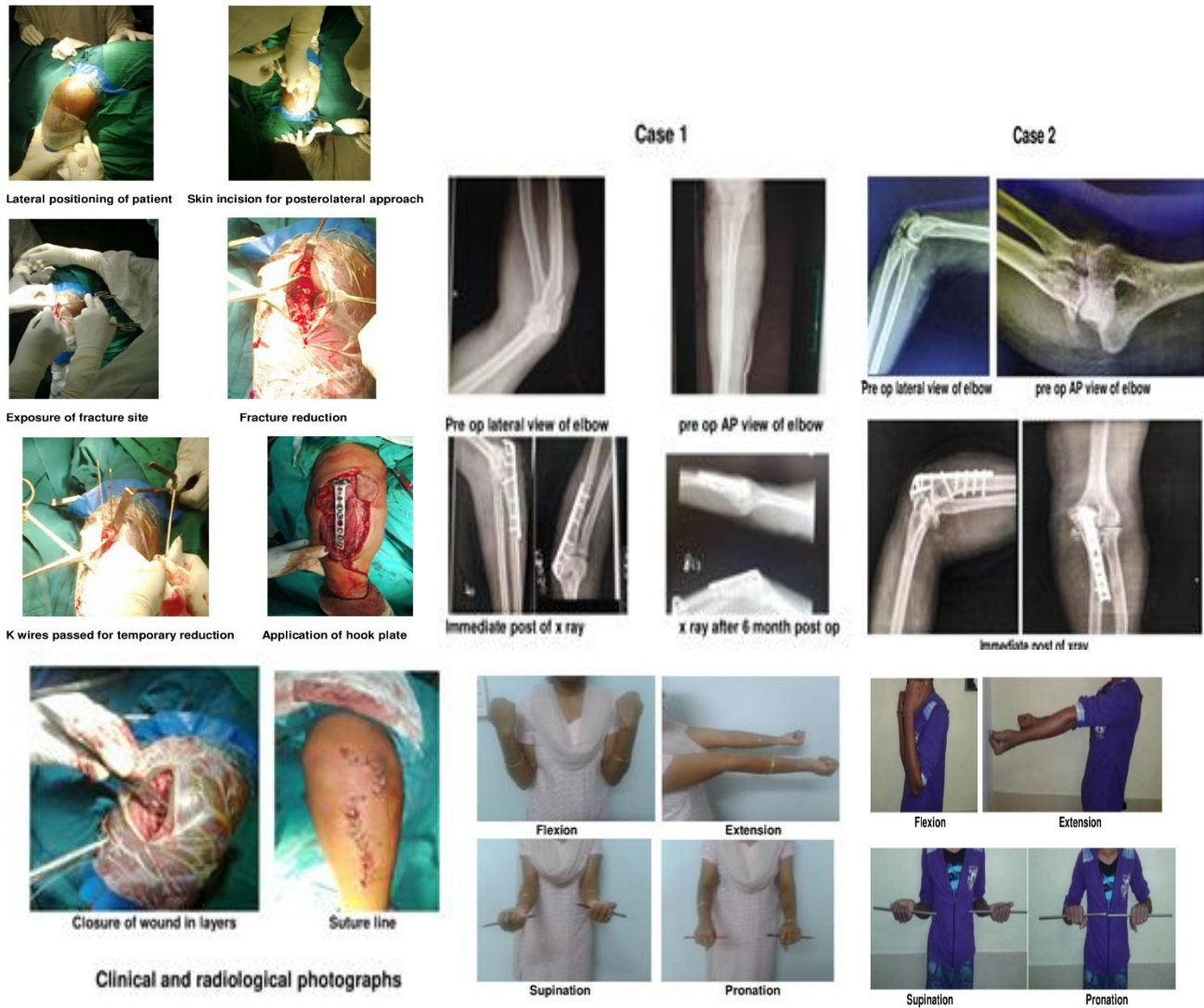
**Table 3: Results of Mayo elbow performance score.**

Grading score	No. of cases	Percentage
Excellent (>90)	21	70
Good (75-89)	6	20
Fair (60-74)	3	10
Poor (<60)	-	-

Results of our study were excellent and we were in favour of using hook plate for all types of fractures of olecranon process of ulna. Fixation of olecranon fracture using hook plate is an excellent modality of treatment as hook plate gives good results in transverse, oblique as well as comminuted fractures so can be used as a single modality of treatment irrespective of the type of fracture giving better functional as well as radiological outcome.

**Table 4: Mayo elbow performance score.**

Section	N
<b>Section 1: Pain intensity</b>	45
None	45
Mild	30
Moderate	15
Severe	-
<b>Section 2: Motion</b>	20
Arc of motion greater than 100 degrees	20
Arc of motion between 50 and 100 degrees	15
Arc of motion less than 50 degrees	5
<b>Section 3: Stability</b>	10
Stable	10
Moderate instability	5
Grossly unstable	-
<b>Section 4: Function (Tick as many as able)</b>	25
Can comb hair	5
Can eat	5
Can perform hygiene	5
Can din shirt	5
Can don shoe	5
Total	100



**Figure 1: Intraoperative, radiological and follow up images.**

**Complications**

During follow up period of one year, no other complications like loss of reduction or failure of implant were seen. In our study, 3 patients developed superficial infection after 7 days of surgery which was recovered by giving appropriate antibiotics after doing culture sensitivity testing while 4 patients had symptomatic metal prominence after 6 months of surgery which was treated by implant removal after union of fracture.

**DISCUSSION**

Fractures of olecranon process of ulna are one of the most common injuries of upper extremity.<sup>5</sup> Olecranon fractures of ulna accounts for approximately 10% fractures around elbow in adults and they vary from simple non displaced fractures to complex fracture dislocation of elbow.<sup>6</sup> Before the days of asepsis, olecranon fracture was treated by

immobilisation in full extension for 4-6 weeks, but that resulted in stiff elbow in non-functional position. So after that, immobilisation in mild flexion was given.<sup>7</sup> In this position non-union became very common due to wide separation of fractured fragments.<sup>8</sup> In order to avoid complication of non-union as well as arthritis of elbow joint, anatomical reduction is required by internal fixation for any intra-articular fracture of olecranon. Tension band wiring has been considered as gold standard procedure for displaced transverse intra-articular fractures of olecranon.<sup>9</sup> But the drawback of this technique was that it had complication of symptomatic metal prominence and hence required reoperation, that's why internal fixation of comminuted fractures of olecranon has evolved towards using more stable and rigid construct.<sup>10-17</sup> So fixation of olecranon fractures using hook plate gives rigid internal fixation and provides adequate stability in both simple as well as comminuted fractures of olecranon.<sup>18</sup> No failure of fixation was reported in our study using technique of hook plate. Early range of motion is a critical aspect in



postoperative care of fractures of olecranon process of ulna.<sup>19</sup> Posterior plating was most commonly used which was applied on dorsal tension surface of ulna and it facilitated fracture reduction and early union.<sup>20</sup> The advantage of using this technique of hook plate was that it could be used in all types of fractures of olecranon process of ulna achieving stable and rigid internal fixation which in turn allowed early range of motion of elbow joint avoiding complication of secondary arthritis and postoperative stiffness of elbow thereby giving excellent functional outcome.

Limitation of this study was we could not use this implant in compound fracture of olecranon process of ulna.

## CONCLUSION

From the present study it is concluded that technique of open reduction and internal fixation for simple transverse, oblique and comminuted fractures using locking hook plate are effective means and gold standard technique of treating fractures of olecranon. Because of rigid fixation of fracture fragments early active range of motion of elbow joint can be initiated and thereby avoiding complication of postoperative elbow stiffness. From our study we conclude that locking hook plate can be used as excellent modality of treatment for fixation of all types of olecranon fractures of ulna with minimal complications and good functional outcome to the patient, which aspect is very important from psychological and economical point of view for the patient causing early return to work of the patient.

*Funding: No funding sources*

*Conflict of interest: None declared*

*Ethical approval: The study was approved by the institutional ethics committee*

## REFERENCES

1. Ring D. Elbow fractures and dislocations. Bucholz RW, Heckman JD, eds. Rockwood and Green Fractures in Adults. 7<sup>th</sup> ed. Philadelphia: Lippincott Williams and Wilkins; 2010: 936-42.
2. Howard JL, Urist MR. Fracture dislocation of the radius and the ulna at the elbow joint. Clin Orthop 1958;12:276-84.
3. Willams JR. Coronoid, radial head, olecranon fractures and elbow dislocations. Oxford Text book of Orthopaedics and Trauma. 1st ed. Oxford University Press; 2002: 1969-72.
4. Willis C Campbell WC, Canale ST, Beaty JH. Fractures of shoulder, arm and forearm. Campbell's Operative Orthopaedics. 11<sup>th</sup> ed. Philadelphia, PA: Mosby/Elsevier; 2008: 3411-7.
5. Jupiter JB, Mehne DK. Trauma to the adult elbow of the distal humerus. In: Browner BD, Jupiter JB, Levine AM, eds. Skeletal trauma fractures, dislocations, ligamentous injuries. Philadelphia: WB Saunders; 1992: 1125-76.
6. Veillette CJ, Steinmann SP. Olecranon fractures. Orthop Clin North Am. 2008;39(2):229-36.
7. Deane M. Comminuted fractures of the olecranon: an appliance for internal fixation. Injury. 1970;2(2):103-6.
8. Perkins G. Fractures of the olecranon. Br Med J. 1936;2(3952):668-9.
9. Colton CL. Fractures of the olecranon in adults: classification and management. Injury. 1973;5(2):121-9.
10. Holdsworth BJ, Mossad MM. Elbow function following tension band fixation of displaced fractures of the olecranon. Injury. 1984;16(3):182-7.
11. Karlsson MK, Hasserius R, Besjakov J, Karlsson C, Josefsson PO. Comparison of tension-band and figure-of-eight wiring techniques for treatment of olecranon fractures. J Shoulder Elbow Surg. 2002;11(4):377-82.
12. Macko D, Szabo RM. Complications of tension-band wiring of olecranon fractures. J Bone Joint Surg Am. 1985;67(9):1396-401.
13. Romero JM, Miran A, Jensen CH. Complications and re-operation rate after tension-band wiring of olecranon fractures. J Orthop Sci. 2000;5(4):318-20.
14. Wolfgang G, Burke F, Bush D, Parenti J, Perry J, LaFollette B, et al. Surgical treatment of displaced olecranon fractures by tension band wiring technique. Clin Orthop Relat Res. 1987;224:192-204.
15. Boyer MI, Galatz LM, Borrelli J, Axelrod TS, Ricci WM. Intra-articular fractures of the upper extremity: new concepts in surgical treatment. Instr Course Lect. 2003;52:591-605.
16. Hume MC, Wiss DA. Olecranon fractures. A clinical and radiographic comparison of tension band wiring and plate fixation. Clin Orthop Relat Res. 1992;285:229-35.
17. Nork SE, Jones CB, Henley MB. Surgical treatment of olecranon fractures. Am J Orthop Belle Mead NJ. 2001;30(7):577-86.
18. Bailey CS, MacDermid J, Patterson SD, King GJ. Outcome of plate fixation of olecranon fractures. J Orthop Trauma. 2001;15(8):542-8.
19. Elliott MJ, Ruland R, Fox B. Olecranon fracture fixation utilizing a bioabsorbable tension band construct: analysis of stability with motion in a cadaveric model. J Pediatr Orthop B. 2005;14(6):444-7.
20. Gordon MJ, Budoff JE, Yeh ML, Luo ZP, Noble PC. Comminuted olecranon fractures: a comparison of plating methods. J Shoulder Elbow Surg. 2006;15(1):94-9.

**Cite this article as:** Lingayat MB, Patel A, Thorat CR. Short-term functional results of surgical management of fractures of olecranon process of ulna by locking hook plate. Int J Res Orthop 2021;7:959-63.