

Neuroimaging Findings of the High-risk Neonates and Infants Referred to Mofid Children's Hospital

How to Cite This Article: Saket S^{ib}, Karimzadeh P, Nasehi MM, Taghdiri MM, Falahi M, Shamshiri A, Rahimian E. Neuroimaging Findings of the High-risk Neonates and Infants Referred to Mofid Children's Hospital. Iran J Child Neurol. Autumn 2022; 16(4): 33-44

Sasan SAKET MD^{1,2},
Parvaneh KARIMZADEH MD^{1,2},
Mohammad Mehdi NASEHI MD^{1,2},
Mohammad Mehdi TAGHDIRI MD^{1,2},
Mino FALAHI MD³,
Ahmadreza SHAMSHIRI MD⁴,
Elham RAHIMIAN MD⁵

1. Iranian Child Neurology Center of Excellence (ICNCE), Pediatric Neurology Research Center, Research Institute for Children Health, Shahid Beheshti University of Medical Sciences, Tehran, Iran.
2. Pediatric Neurology Department, Mofid Children's Hospital, Faculty of Medicine, Shahid Beheshti University of Medical Sciences, Tehran, Iran
3. Department of Pediatric Neonatology, Neonatal Health Research Center, Research Institute for Children Health, Shahid Beheshti University of Medical Sciences, Tehran, Iran.
4. Department of Community Oral Health, School of Dentistry, Research Center for Caries Prevention, Dental Research Institute, Tehran University of Medical Sciences,

Abstract

Objectives

Neuroimaging in high-risk neonates and infants is done to help child neurologists predict the future neurodevelopmental outcome of these children. In this study, we assessed high-risk neonates and infants admitted to the NICU or neonatal wards of Mofid children's Hospital, especially regarding clinical development and brain imaging.

Materials & Methods

This cross-sectional study was conducted on 170 patients admitted to the neonatal and NICU ward of Mofid children's Hospital. Considering the inclusion criteria, 112 patients were included in this project. Brain ultrasonography was performed on almost all of these babies by a single radiologist. Some patients underwent a brain CT scan, and brain MRI without contrast was done on the others. These images were interpreted and compared by a single pediatric neuro-radiologist blinded to clinical data. All of these babies were followed up until 18 months of age.

Results

In this study, 57.1% of the patients were male and 42.9% were female. Of 44 patients who obtained Electroencephalogram (EEG) during the hospitalization period with probable seizure, 25 (56.8%) had normal EEGs. Of 89 babies who were examined by ultrasound, 19 (21.3%) had abnormal findings; ventriculomegaly and then germinal matrix hemorrhage (GMH) were the most common abnormalities. Also, 27 cases (71.1%) of 38 patients undergoing a CT scan had abnormal findings. The most common findings were a hypodense area in the white matter and ventriculomegaly. Of 41 patients who

Tehran, Iran.

5. Neuroradiologist, Haghigat MRI Center, Tehran, Iran

Corresponding Author

Saket S. MD

Assistant Professor of Child Neurology at Iranian Child Neurology Center of Excellence (ICNCE), Pediatric Neurology Research Center, Research Institute for Children Health, Shahid Beheshti University of Medical Sciences, Tehran, Iran.

Email: drsasan@sbmu.ac.ir

Received: 27-Aug-2021

Accepted: 29- May -2022

Published: 23-oct-2022

underwent MRI between 1 and 27 months, 34 cases (82.9%) had an abnormal MRI. The most common findings were periventricular hyperintensities in 17 cases (41.5%), mildly delayed myelination in 15 cases (36.6%), and severe brain atrophy or thinning of corpus callosum or white matter volume loss in seven cases (17.1%). During the follow-up period, which was 18.55 ± 6.56 months, 79 (70.5%) of the children had normal development and 33 (29.5%) were suffering from a global neurodevelopmental delay. More precisely, 49 (43.7%) and 35 (31.2%) patients had motor development delay and delayed verbal development, respectively. The abnormal findings of brain imaging in the ultrasound, CT scan, and MRI were all significantly associated with an adverse neurodevelopmental outcome ($P < 0.001$, $P = 0.02$, and $P < 0.001$, respectively).

Conclusion

In this study, we showed that at any time before six months or after one year of age, the result of brain MRI was a strong predictor of the patient's outcome.

Keywords: Neuroimaging findings; Neurodevelopmental outcome; High-risk neonates; infants

DOI: 10.22037/ijcn.v16i4.35943

Introduction

Cerebral palsy (CP), as a predictive sign of neurodevelopmental aspects in infants born after 27 weeks' gestation, occurs in 3% of the infants (1-3), which might grow up to 20% in children born between 24- and 26-weeks' gestation (4). Brain imaging during the neonatal period could assess the neurodevelopmental situation to help decision-makers provide conservative and protective health care systems. Many studies have been conducted to assess the role of cranial imaging techniques, including ultrasound, CT scan, and MRI, in detecting the neurodevelopmental situation in neonates and infants. They showed the effects of many medical conditions on child neurodevelopmental problems,

such as seizures (5-7) and asphyxia (8). MRI is known as a perfect way to diagnose perinatal arterial ischemic stroke, neonatal Cerebral Sino Venous Thrombosis (CSVT), perinatal trauma, intraventricular hemorrhage (IVH), cerebellar hemorrhage, and preterm neonatal damage in the white matter (1, 4, 9-14). The incidence and severity of IVH depend on birth weight and gestational age insofar as 25% of neonates weighing 501-750 gr at birth usually have the most severe hemorrhages, especially in males (4). El-Dib et al. in 2010 and Plaisier et al. in 2014 claimed that cranial MRI was a highly prognostic modality for a neurologic outcome in preterm neonates when they reached their term-equivalent age (15, 16). Previously in

2009, Myers et al. pointed out that abnormal brain MRI in preterm neonates, at their term-equivalent age, could warn about serious clinical damage in the future (17). In 2013, brain MRI was introduced as the gold standard imaging by Hallberg et al. in brain assessment among neonates, while the CT scan could make children face a considerable number of dangerous radioactive beams to obtain lower quality images instead (18). The current study attempted to evaluate and follow up high-risk neonates and infants who were hospitalized and experienced cranial imaging through their first 18 months of age before comparing their current situations with birth time in order to schedule perfect arrangements for a favorable future.

Materials & Methods

Through a cross-sectional method, the present study aimed to evaluate cranial imaging results among high-risk neonates and infants referred to a university referral children's hospital in Tehran. Out of the patients admitted to the neonatal or NICU ward of Mofid hospital, a large number of themes were enrolled in this study based on the inclusion and exclusion criteria from April 2012 to April 2013, providing that their parents granted us their consent.

Inclusion criteria: The following criteria were set for including the patients in this study: Hypoglycemia, meningitis or sepsis, asphyxia, seizure, hypotonia, poor feeding, lethargy, hypertonia, swallowing disorders, cyanosis, and apnea, abnormal neurologic examination, symptomatic hyperbilirubinemia, prematurity (GA<34-35 wks.), under mechanical ventilation, malformation, an Apgar score <4 in the first minute or <6 in the fifth minute, and a prenatal history including breech presentation, nuchal cord, forceps delivery, preeclampsia, eclampsia,

decolman, drug abuse, prolonged delivery, and precipitated delivery.

Exclusion criteria: Imperfect disease and history records, surgical cases without brain imaging, and lack of cooperation were the items causing patients to leave the study. Weekly serial visits with the participants were scheduled after a complete primary examination while they were supervised by a single radiologist for a cranial ultrasound and also a brain CT scan (Siemens Multi-Slice). Brain MRI without contrast (Siemens Medical Systems, Avanto, Germany 1.5 Tesla) was also tried for some patients if needed. All the patients were followed up at least to their 18 months of age.

MRI indications: The patients with at least one inclusion criterion along with an abnormal neurologic examination, an abnormal cranial CT scan or ultrasound, postnatal seizure, postnatal abnormal clinically neurologic findings, evolutionary regression, and a developmental delay after six months had a relevant indication for MRI.

Statistics: SPSS was utilized to analyze quantitative and qualitative data through the independent t-test, Chi-square test, and Fisher's exact test, and the significance level was considered 0.05.

Ethics: There was no extra charge for research visits that were not clinically necessary and the parents received feedback on imaging and the results of each visit. The aim and process of the study were explained to all the parents before giving their verbal consent. All the private information was safely kept by the principal investigators.

Results

Of 170 primarily evaluated patients, 58 subjects were excluded due to imperfect data considering inclusion and exclusion criteria, and 112 were finally

studied. Males made up 57.1% of the participants and the rest were females. As seen in Table 1, the shortest and longest gestational ages were 26 weeks and 41 weeks, respectively. The lowest birth weight was 770 gr, but the highest was 4125 gr. Concerning the head circumference, it ranged between 25 and 36.5 cm. The majority of the hospitalized children were from Tehran. Figure 1 shows the frequency of medical conditions of the participants on the bases of the inclusion criteria. Three-fourths of the studied children (84 cases) had experienced cesarean section, and 28 (25%) were naturally given birth, among whom 89% had a normal vaginal delivery (NVD) and three suffered from a difficult delivery. Figure 2 shows that myelomeningocele (3 cases), cleft palate (2 cases), and coarctation of the aorta (2 cases) were the most frequent abnormalities. Of 44 patients experiencing electroencephalography due to the suspicious seizure, 25 (56.8%) had normal findings, and 12 (27.3%) had mildly, 6 (13.6%) had moderately, and one (2.3%) had severely abnormal findings. Table 2 illustrates 89 children with ultrasound evaluation from day two to day 82, including 19 cases (21.3%) with abnormal findings, among which ventriculomegaly and germinal matrix bleeding were the most frequent ones.

Of 38 patients with a CT-scan study between days two and 112, 27 (71.1%) had abnormal findings, as shown in Table 3. The most frequent findings were hypodense areas in the white matter in 10 (26.3%) cases, ventriculomegaly in seven (18.4%), intraventricular hemorrhage (IVH) in four (10.5%), and extra-axial space widening in four cases (10.5%). Moreover, MRI results between month

one to month 27 in 41 cases showed 34 abnormal findings (82.9%), including periventricular hyperintensity in seventeen (41.5%), mild myelination delay in fifteen (36.6%) and severe brain atrophy, thinning of corpus callosum or white matter volume loss in seven (17.1%) (see Table 4). Among the imaging techniques, the CT scan was better than ultrasound based on the result of the McNemar test. Furthermore, although MRI was much better than the ultrasound, the sample size was not enough to show the superiority of MRI over the CT scan.

The mean time of follow-up was 18.55 ± 6.56 months. During this time 79 (70.5%) of the patients had normal development but 33 (29.5%) experienced global developmental delay; in other words, 49 (43.7%) had motor delay whilst 35 (31.2%) had speech delay as can be seen in diagram 3. Table 5 shows the correlation between cranial ultrasound and the outcome of high-risk neonates to indicate an undesirable sequel in 24 (34.3%) and 15 (78.9%) patients with normal and abnormal ultrasound findings, respectively (P -value <0.001). Fisher's exact test indicated that 4 out of 11 (36.4%) patients with normal and 22 of 27 (81.5%) patients with an abnormal brain CT scan had an unfavorable outcome (P -value=0.02). Moreover, unwanted sequels in one of seven (14.3%) and 33 of 34 (97.1%) with normal and abnormal MRI findings were significantly different (P -value <0.001) (Table 5). In addition, Table 6 shows MRI as a perfect prognostic module for outcomes, disregarding children's age in the high-risk population.

Neuroimaging Findings of the High-risk Neonates and Infants Referred to Mofid Children's Hospital

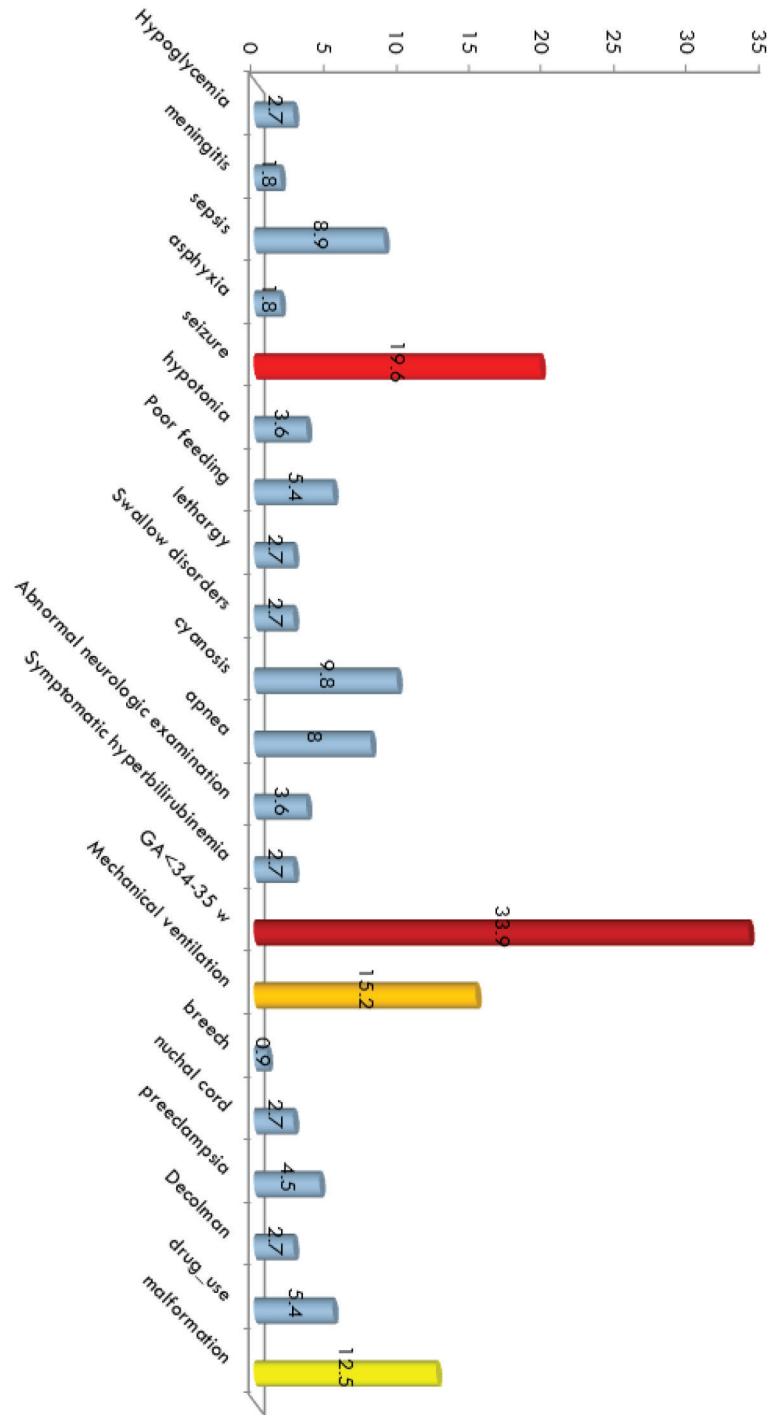


Figure 1. The frequency of different medical conditions among the participants regarding our inclusion criteria

Neuroimaging Findings of the High-risk Neonates and Infants Referred to Mofid Children’s Hospital

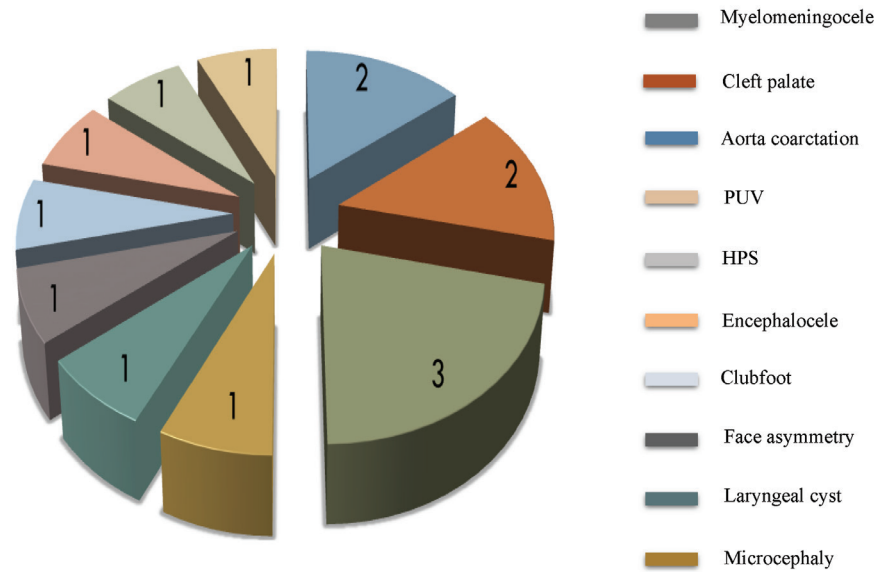


Figure 2. The frequency of abnormalities among the participants

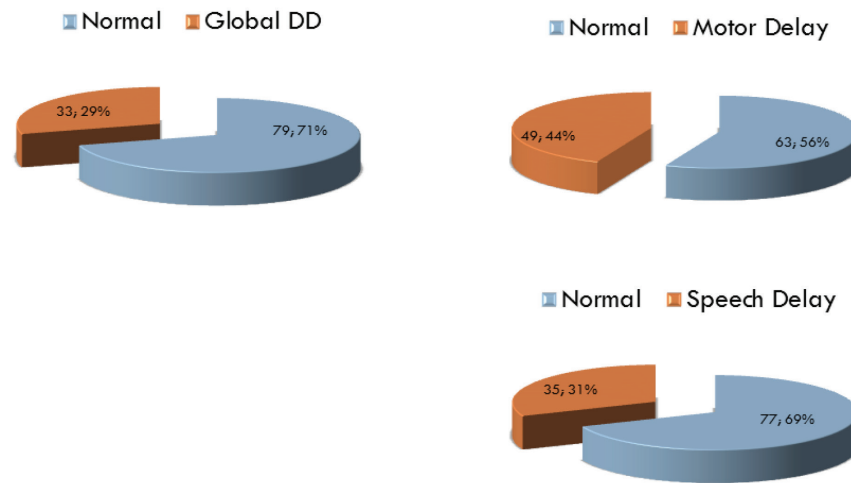


Figure 3. Assessment of high-risk infants regarding neurodevelopmental aspects

Table 1. Characteristics of 112 high-risk infants participating in the current study

Items	Mean±SD	Minimum	Maximum
Gestational age (wks)	35.18±3.58	26	41
Birth weight (gr)	2490.04±848.80	770	4125
Head circumference (cm)	32.32±2.64	25	36.5

SD: Standard Deviation; wks: Weeks; gr: Grams; cm: Centimeters

Table 2. Brain ultrasonographic findings among high-risk infants between days 2 and 82 of hospitalization

Findings	First Ultrasound 89 patients n (%)	Second Ultrasound 23 patients n (%)	Third Ultrasound 9 patients n (%)
Ventriculomegaly	7(7.9)	7(30.4)	3(33.3)
Hydrocephalus	1(1.1)	1(4.3)	0

Findings	First Ultrasound 89 patients n (%)	Second Ultrasound 23 patients n (%)	Third Ultrasound 9 patients n (%)
Encephalomalacia	1(1.1)	1(4.3)	1(11.1)
ICH	0	0	0
IVH	1(1.1)	2(8.7)	1(11.1)
Gray matter hemorrhage 1-4	7(7.9)	6(26.1)	1(11.1)
Cystic changes	1(1.1)	1(4.3)	1(11.1)
Microcalcification	1(1.1)	0	0
Porencephalic lesion	0	1(4.3)	0
Parenchymal damage	0	1(4.3)	0

Table 3. Brain CT-scan findings among high-risk infants

Findings	First CT-scan 38 patients n (%)	Second CT-scan 9 patients n (%)	Third CT-scan 3 patients n (%)
Ventriculomegaly	7(18.4)	3(33.3)	2(66.7)
Hydrocephalus	4(10.5)	3(33.3)	1(33.3)
Dysgenesis of Corpus Callosum	3(7.9)	1(11.1)	0
Brain atrophy	2(5.3)	0	0
Extra axial spaces widening	4(10.5)	0	0
White matter hypodense	10(26.3)	2(22.2)	2(66.7)
Hypodense foci along falx cerebri	1(2.6)	0	0
IVH	4(10.5)	1(11.1)	3(100)
ICH	1(2.6)	0	0
Brain edema	3(7.9)	0	0
Porencephaly	1(2.6)	1(11.1)	2(66.7)
Calcification	2(5.3)	0	0
Encephalocele	1(2.6)	1(11.1)	0
Cortical dysplasia	0	1(11.1)	0
Subdural hematoma/effusion	0	2(22.2)	2(66.7)

Table 4: Brain MRI findings among the studied high-risk infants with the relevant frequencies

Findings	First MRI: 41 patients n (%)
Normal brain MRI	7(17.1)
Severe brain atrophy	7(17.1)
Widening of CSF spaces	3(7.3)
Agenesis of Corpus Callosum	2(4.9)
Thinning of Corpus Callosum	7(17.1)
Increased signal in Globus Pallidus	3(7.3)
Increased signal in Pons	1(2.4)
Increased signal in Midbrain	1(2.4)
Delayed myelination (slight)	15(36.6)
Delayed myelination (significant)	2(4.9)
Periventricular hyperintensities	17(41.5)
PVWM volume loss	7(17.1)
Vascular anomaly	1(2.4)
Focal Gliosis	3(7.3)
Periventricular calcification	1(2.4)
Ventricular dilatation	2(4.9)

Table 5. Outcomes of the participants based on a comparison of three imaging modulations (ultrasound, CT scan and MRI)

Module		Outcome		Sig
		Desirable n (%)	Undesirable n (%)	
Ultrasound	Normal	46(65.7)	24(34.3)	< 0.001*
	Abnormal	4(21.1)	15(78.9)	
CT scan	Normal	7(63.6)	4(36.4)	0.02**
	Abnormal	5(18.5)	1(14.3)	
MRI	Normal	6(85.7)	1(14.3)	< 0.001***
	Abnormal	1(2.9)	33(97.1)	

*P-value was extracted by Chi-square test, Odds ratio=7.19, 95%CI: 2.15-24.06

**P-value was extracted by Fisher’s exact test, Odds ratio=7.7, 95%CI: 1.61-36.86

***P-value was reported by Fisher’s exact test, Odds=198, 95%CI: 10.84-3616.86

Table 6. Correlation between imaging findings based on **brain MRI timing** and the outcome among high-risk infants

Age at MRI imaging	Patients	Outcome		Sig
		Desirable	Undesirable	
< 6 months	12	3	8	0.006
6-12 months	12	2	10	0.17
>12 months	18	2	16	0.02

Discussion

The present study aimed to assess cranial imaging in neonates and infants with a history of preterm delivery and raise some abnormalities in not only encephalography but also ultrasound, CT scan, and MRI as expected. Detecting neurodevelopmental outcomes in high-risk neonates has been a challenge; however, early and accurate prediction of neurodevelopmental delay is vital to make a perfect decision on intervention or novel therapies (19).

Of 112 patients, three (2.7%) had a history of hypoglycemia, and one of them showed changes in parietal periventricular density by a CT scan. This finding is in line with Karimzadeh et al. who explained 90% of signal changes in posterior brain area through MRI in 2010 (16) among 27 convulsive cases. We reported 22 (19.6%) cases with seizure which is more prevalent in preterm infants (20). Of the 38 patients who underwent CT scans between days two and 112, 27 cases (71.1%) had abnormal CT scans, with the most common findings being hypodense areas in the white matter in 10 cases (26.3%), ventriculomegaly in seven cases (18.4%), intraventricular hemorrhage in four cases (10.5%), and widening of the extra-axial space in four cases (10.5%). The rates were much lower than what Taghdiri et al. revealed in 80 neonates in 2005 (5). They showed 65% abnormality in a CT scan, including 21.2% intracranial hemorrhage and 10% dysgenesis, and they strongly advised that a

cranial CT scan be performed on all neonates who experience seizure during their first 72 hours of life and usually have a difficult or lengthy delivery, or asphyxia. In the present study, asphyxia occurred in two (1.8%) of 112 patients who belonged to the group of abnormal brain CT-scan findings. Assessing 45 neonates with asphyxia in Shiraz in 2004 by Pour-Arian et al. (8) indicated 80% abnormalities, such as 33.3% intracranial hemorrhage. Sabzehi et al., in 2014 (6), conducted a study on 102 infants with a history of seizure. They found that of the 49 patients who underwent a brain CT scan, 86.3% had abnormal findings. Intracranial hemorrhage was seen in 6.9% of infants. They reported a 14.7% death rate through their performance, while we observed a death rate of 5.4% in our study. The present study had a high rate of seizure chiefly due to the referral center where we were working and to which neonates and infants were admitted from 15 adjacent provinces. A low death rate may be attributed to complete and perfect high health services provided by our center. Two of our deceased patients who had abnormal MRI and CT-scan findings had refractory seizures. Seyed Shahabi et al. studied 31 term neonates with seizure in 2008 and their results revealed ischemic brain lesions in a CT scan in five (16%) patients, while cranial ultrasound showed the lesions only in one (7). Like others, they advised using a CT scan or MRI in all neonates with seizure without ش history of asphyxia, even if their physical examination is

normal and no explanation exists for seizure. Our finding is in line with some previous studies in terms of the superiority of MRI in brain imaging for neurodevelopment assessment in children (1-3, 21). El-Dib et al. (15) in 2010 and Plaisier et al. in 2014 (22) admired brain MRI for predicting a neurologic outcome in preterm neonates at their term-equivalent age, and Hallberg et al. (18) named brain MRI as the gold standard modality for neonatal brain assessment in 2013 and placed the CT scan inferior due to high X-ray exposure for low-quality images. In this regard, Myers et al. mentioned that using a cranial MRI at term-equivalent age in preterm neonates could correlate brain abnormalities with a serious clinical outcome in the future (17).

In 2018, Natarajan et al. (23) considered histologic chorioamnionitis, gestational age, antenatal steroids, and cesarean section as associated factors with abnormal cranial imaging among more than 7,000 moderately preterm infants who showed 15% intracranial hemorrhage, cystic periventricular leukomalacia, or late ventriculomegaly.

In more detail, Salamon et al. (24) in 2014 asserted that periventricular hemorrhagic infarction in temporal or frontal white matter in preterm infants was related to a typical motor outcome besides having the risk of cognitive, behavioral, and visual challenges. Of the 89 patients undergoing sonography between days two and 82, 19 cases (21.3%) had abnormal sonography, with the most common ultrasound findings being ventriculomegaly and then germinal matrix hemorrhage (GMH). Working on 129 preterm infants, Zhang et al. (25) found that the consistency rate between cranial ultrasound and MRI was 88%. At the first cranial ultrasound, GMH grades three and four, hospitalization duration, and

weight significantly correlated with mental and psychomotor developmental index MDI/PDI and prognosis.

In Conclusion

the current study showed the superiority of the CT scan and MRI in detecting cranial damage compared with cranial ultrasound. Nevertheless, there was no perfect sample size to compare MRI and CT scans in this regard. However, disregarding the age, MRI had a strong prognostic value in predicting the outcome.

Author's Contribution

PK, SS and MF designed and supervised all the processes, and SS collected the data and prepared the primary & final manuscript and followed up the babies until 18 months of age. ARSh analyzed the data and reviewed the primary manuscript. All radiologic images were interpreted and compared by ER. All authors have seen and approved the content of the final manuscript that is currently being submitted and have contributed significantly to the work.

Acknowledgment

This research article is based on Sasan Saket's dissertation for subspecialty in Pediatric Neurology at a university hospital in Tehran, Iran. We thank all the hard-working colleagues who assisted us in achieving promising results. This research article is based on Dr. Sasan Saket's dissertation for subspecialty in Pediatric Neurology at a university hospital in Tehran, Iran. We thank all the hard-working colleagues who assisted us in achieving promising results, especially Pediatric Neurology Research Center and Neonatal Health Research Center. Finding the families to schedule medical

visits was the only challenge throughout the follow-up period.

Conflict of interest

None

References

1. Xiong T, Gonzalez F, Mu D. An overview of risk factors for poor neurodevelopmental outcome associated with prematurity. *World J Pediatr.* 2012 8(4):293-300.
2. Li M, An Y, Miao L, Hua R, Yu A, Zhang F, et al. Risk factors of cerebral palsy during the perinatal period. *Academic Journals* 2011; 6(13), pp. 2724-8.
3. Benders MJ, Palmu K, Menache C, Borradori-Tolsa C, Lazeyras F, Sizonenko S, et al. Early Brain Activity Relates to Subsequent Brain Growth in Premature Infants. *Cerebral Cortex* 2014; doi:10.1093/cercor/bhu097.
4. Swaiman KF, Ashwal S, Ferriero DM, Schor NF. *Swaiman's Pediatric Neurology Principles and Practice.* 5th ed. 2012. London. ELSEVIER Saunders.798-810.
5. Taghdiri MM, Emadi M, Jabbari M, Tavasoli AR. Plain CT scan in Neonatal Convulsion. *MJIRC* 2005; 7:53-5.
6. Sabzehei MK, Basiri B, Bazmamoun H. The Etiology, Clinical Type, and Short Outcome of Seizures in Newborns Hospitalized in Besat Hospital/ Hamadan/ Iran. *Iran J Child Neurol.* 2014 spring 8(2):24-8.
7. Seyed Shahabi N, Fakhraee SH, Afjeiee SA, Kazemian M. Seizures and Cerebral Infarction and the Role of Neuroimaging in the Full-Term Newborns. *PajooHande.* 2008; 13 (4) :347-53.
8. Pourarian Sh, Rasekhi AR. A Study on the Correlation between Brain CT-scan and Clinical Findings in Neonatal Asphyxia. *JMR* 1383; 3: 42-7.
9. Fenichel GM. *Neonatal Neurology.* 4th ed.2007. China. Churchill Livingstone. pp:69-89 & 109-141 &143-165.
10. Perlman JM. *Neurology Neonatology Question and Controversies.* 2nd ed.2012. Philadelphia. Elsevier. pp:27-45 & 285-324 &325-340.
11. Castillo M, Mukherji SK. *Imaging of the Pediatric Head, Neck, and Spine.* 1st ed.1996. Philadelphia. Lippincott-Raven. pp:96-142 & 145-187 & 277-316.
12. Barkovich AJ, Kjos BO, Jackson DE, Norman D: Normal maturation of the neonatal and infant brain: MR imaging at 1.5 T, 1988.*Radiology* 166:173-80.
13. Kliegman RM, Stanton BF, St. Geme JW, Schor NF, Behrman RE. *Nelson textbook of pediatrics.* 19th ed. 2011. Philadelphia. Elsevier. p:552.
14. Gleason CA, Devaskar SU. *Avery's diseases of the newborn.* 9th ed.2012. Philadelphia. Elsevier. pp:816-43.
15. El-Dib M, Massaro AN, Bulas D, Aly H: Neuroimaging and Neurodevelopmental Outcome of Premature Infants. *Am J Perinatol* 2010; 27:803-18.
16. Karimzadeh P, Tabarestani S, Ghofrani M: Hypoglycemia-Occipital Syndrome: A Specific Neurologic Syndrome Following Neonatal Hypoglycemia? *J Child Neurol.*2010; 1-8.
17. Myers E, Ment LR. Long-Term Outcome of Preterm Infants and the Role of Neuroimaging. *Clin Perinatol.* 2009 December; 36 (4):

- doi:10.1016/j.clp.2009.07.008.
18. Hallberg B, Blennow M. Investigations for neonatal seizures. *Seminars in Fetal & Neonatal Medicine* 18 (2013) 196-201.
 19. Cioni G, Inguaggiato E, Sgandurra G. Early intervention in neurodevelopmental disorders: underlying neural mechanisms. *Developmental Medicine & Child Neurology* 2016; 58 (Suppl. 4): 61–6. DOI: 10.1111/dmcn.13050.
 20. Pisani F, Facini C, Bianchi E, Giussani G, Piccolo B, Beghi E. Incidence of neonatal seizures, perinatal risk factors for epilepsy and mortality after neonatal seizures in the province of Parma, Italy. *Epilepsia* 2018; 59(9): 1764-73.
 21. Menkes JH, Sarnat HB, Maria BL. *Child Neurology*. 7th ed.2006. Philadelphia. Lippincott Williams & Wilkins.p:368.
 22. Plaisier A, Govaert P, Lequin MH, Dudink J. Optimal Timing of Cerebral MRI in Preterm Infants to Predict Long-Term Neurodevelopmental Outcome: A Systematic Review. *Am J Neuroradiol*.2014. dx.doi.org/10.3174/ajnr.A3513.
 23. Natarajan G, Shankaran S, Nolen TL, et al. Neurodevelopmental outcomes of preterm infants with retinopathy of prematurity by treatment. *Pediatrics* 2019; 144(2): e20183537. doi: 10.1542/peds.2018-3537.
 24. Salamon AS, Groenendaal F, van Haastert IC, et al. Neuroimaging and neurodevelopmental outcome of preterm infants with a periventricular haemorrhagic infarction located in the temporal or frontal lobe. *Dev Med Child Neurol*. 2014; 56(6): 547-55. doi: 10.1111/dmcn.12393. Epub 2014 Feb 10.
 25. Zhang XH, Qiu SHJ, Chen WJ, et al. Predictive value of cranial ultrasound for neurodevelopmental outcomes of very preterm infants with brain injury. *Clin Med J (Engl)* 2018; 131(8): 920-6. doi: 10.4103/0366-6999.229895.

Copyright © 2022 The Authors. Published by Shahid Beheshti University of Medical Sciences.
This work is published as an open access article distributed under the terms of the Creative Commons Attribution 4.0 License (<http://creativecommons.org/licenses/by-nc/4>). Non-commercial uses of the work are permitted, provided the original work is properly cited.
