



Effects of Intracanal Curcumin and Aloe vera on pH Changes in Simulated Root Surface Resorption Defects: An *In vitro* Study

Sahar Shakouei Bonab ^a , Mohammad Samiei ^a , Aysan Shahmorad Moghanlou ^{b*}

^a Department of Endodontics, School of Dentistry, Dental and Periodontal Research Center, Tabriz University of Medical Sciences, Tabriz, Iran; ^b School of Dentistry, Dental and Periodontal Research Center, Tabriz University of Medical Sciences, Tabriz, Iran

Article Type: Original Article

Received: 24 Jun 2022

Revised: 09 Sep 2022

Accepted: 18 Sep 2022

Doi: 10.22037/iej.v17i4.35570

*Corresponding author: Aysan Shahmorad Moghanlou, Faculty of Dentistry, Tabriz University of Medical Sciences, Golgasht St., Tabriz, Iran.

E-mail: aysanshmd@gmail.com

Introduction: Commonly used medicaments in the treatment of external inflammatory root resorption (EIRR) have shown adverse effects; resulting in an increasing tendency to employ natural and/or herbal medication. The present *in vitro* study aimed to evaluate the effects of curcumin and aloe vera, as two natural medicaments, on the changes of pH in external root surface defects; and compare their outcomes with the results obtained from the application of calcium hydroxide, as a conventional medicament used in endodontic treatments. **Materials and Methods:** In the current investigation, 92 permanent teeth, with a single root canal, were randomly divided into four groups. Similar cavities were created on the buccal surfaces of roots, 5 mm from their apices. The root canals in each of the study groups were filled with curcumin, aloe vera, calcium hydroxide or normal saline. The pH was measured after 20 min (i.e. the baseline), 1, 7, 14, 21, and 28 days using a digital pH meter. The data were analysed using repeated-measures ANOVA and the statistical significance was set at $P < 0.05$. **Results:** At the baseline, day 1 and day 7, the mean pH of both curcumin and aloe vera groups was higher than the mean pH of calcium hydroxide and normal saline groups ($P < 0.05$). On day 14, the mean pH of aloe vera group was higher than that of calcium hydroxide and normal saline groups ($P < 0.05$). On days 21 and 28, the mean pH of aloe vera group was higher than the mean pH of all the other groups ($P < 0.05$). All other intergroup differences were not statistically significant at each time point ($P > 0.05$). **Conclusion:** The current *in vitro* study demonstrated that aloe vera was more alkaline than curcumin; nevertheless, both groups exhibited more alkalinity than calcium hydroxide.

Keywords: Aloe vera; Calcium hydroxide; Curcumin; External inflammatory root resorption; External root surface pH

Introduction

Root resorption is the progressive destruction of cementum and dentin by clastic cells. In primary dentition, it is deliberated as a normal physiologic procedure; however, it is considered pathologic in permanent dentition, and most frequently occurs due to inflammation/infection [1-3]. Based on the affected surface(s) and the pathogenesis of the resorption procedure, root resorptions are classified into internal inflammatory resorption, internal replacement resorption, internal surface resorption, external inflammatory resorption, external replacement resorption, external cervical resorption and external surface resorption [2, 3]. External inflammatory root resorption (EIRR) is one of the most prevalent conditions affecting traumatized teeth and their prognosis, especially in

avulsion and replantation cases [4, 5]. It occurs due to cementum loss, which allows communication between the infected/necrotic pulp and the surrounding periodontium through the denuded dentinal tubules. This provides a reservoir for bacteria as well as a path for their toxins and by-products to advance to the root surface, resulting in EIRR progression [1-3].

Since the delayed diagnosis of EIRR can lead to tooth loss, it represents a challenge in dentistry and endodontics [6-8]. It is very important to arrest the progression of EIRR by immediate intervention after the diagnosis is confirmed. The arrest could be achieved by eliminating microorganisms, their by-products and infected pulp tissue from the root canals [1, 2]. However, it has been shown that changes in some characteristics of the lesion area, e.g., pH, have been considered beneficial in arresting the resorptive process [9, 10].

One of the most common and traditional treatments for EIRR is using calcium hydroxide (CH) paste as an intracanal dressing [7-9]. Hermann introduced CH as an intracanal medicament to treat nonvital teeth [11, 12]. However, it is now mostly used as an inter-appointment intracanal dressing [12]. The role of CH in endodontics is mostly due to its ability to induce hard tissue formation, dissolve peripheral tissues, and reveal antibacterial effects. In addition, the high alkaline pH of calcium hydroxide leads to the removal of microorganisms and neutralization of endotoxins [7, 8, 13]. Furthermore, several studies have reported that CH could arrest the resorptive process via releasing hydroxyl ions, which can prevent/arrest the resorption by neutralizing the acidic pH of the resorption area [8, 9, 14]. Furthermore, these hydroxyl ions can inhibit the osteoclastic acid hydrolase activity in the periodontium and activate alkaline phosphatase by increasing the pH of the area [15].

Despite all the advantages and therapeutic effects of CH as an intracanal medicament, as well as its high success rate of up to 97% for the treatment of inflammatory resorption [16], its application in treating EIRR lesions has been limited due to its disadvantages and/or adverse effects; but not limited to, the long-term nature of CH treatment next to its necrotizing effect and higher susceptibility to dentin fracture owing to changes in the mechanical properties of the root dentin; e.g. increasing its brittleness [7, 8, 17, 18]. Moreover, considering the time factor in the treatment of EIRR lesions with CH [6], there are controversial results regarding the effect of intracanal CH on increasing the pH of root surface [6-8]. Additionally, other chemical medicaments have shown adverse effects, including antibiotics overuse, that can result in resistant infections/misuse and cytotoxic reactions. Consequently, natural and/or herbal medicaments are becoming more popular in endodontics [19-21]. Many studies have been conducted on the antibacterial and anti-inflammatory properties of natural medications and have shown different benefits, e.g., lower toxicity, microbial resistance, cost and greater availability [19, 22, 23]. Some of the natural medicaments include propolis [24, 25], carvacrol [26, 27], cumin [28], ginger [29], aloe vera [19, 20, 23, 30] and curcumin [22, 31, 32].

Aloe vera (or *Aloe barbadensis*) is a plant that belongs to the *Liliaceae* family. It is rich in nutrients and active compounds, e.g., vitamins, enzymes, minerals, lignin, and amino acids [20]. This plant, also known as *babosa*, is a natural medicine with anti-inflammatory and antibacterial effects, tissue regeneration ability, and the ability to create a mineralized barrier [21, 23, 30]. Among the components present in aloe vera, aloins and barbadoins are responsible for its antibacterial effects [20].

Curcumin is a natural polyphenol extracted from *Curcuma longa* (turmeric), one of the main components of curry and used as a spice/herbal medicine in many countries. In addition, its therapeutic potential has been evaluated in various diseases caused by inflammatory or immune responses; including rheumatoid arthritis, pancreatitis, and various cancers [32]. Curcumin can experimentally stimulate osteoblastogenesis and inhibit osteoclastogenesis, encouraging its application in preventing bone anomalies [32]. Additionally, it shows other effects, including anti-inflammatory, antioxidant, anti-carcinogenic, antiviral, and antibacterial effects [22]. A recent study demonstrated that light-activated curcumin, as an intracanal medicament, has a more antibacterial effect against *Enterococcus faecalis* compared to CH [31].

The above-mentioned findings and alike support the effectiveness of curcumin or aloe vera application in endodontic treatments. Considering the increasing tendency towards using natural and herbal medications in endodontic treatments, and since many of the commonly used medicaments for treating EIRR are partially effective or have unacceptable adverse effects [32], it is necessary to evaluate the impact of natural medicaments on EIRR lesions. Since increasing the pH of the lesion area is a standard measure to prevent lesions from extension [6, 15], this study aimed to evaluate the effect of curcumin and aloe vera, as intracanal medicaments, on the pH of external root surface compared with calcium hydroxide.

Materials and Methods

In the present *in vitro* study, approved by the Ethics Committee of Tabriz University of Medical Sciences (under the code IR.TBZMED.REC.1399.133), 92 permanent teeth, including incisors, canines and mandibular premolars, with one root, a single root canal and no previous endodontic treatment, were collected. The sample size was calculated using the results of a recent study [7]. Considering the type of error, i.e. $\alpha=0.05$ and $\beta=80\%$, the sample size for each group was 19. To increase the reliability of the study, the sample size was increased by 20%. Therefore, the final sample size for each group was 23 and the total was 92. All the collected teeth were cleaned from debris and soft tissue remnants, and were disinfected by immersing in 5.25% sodium hypochlorite for 1 h [13]. The samples were carefully rinsed in distilled water and stored in normal saline until being used [7]. All the teeth were decoronated using a diamond disk (DFS Diamon, Riedenburg, Germany) at an equal length of 14 mm from the apex. Full-length radiographs (Carestream, Rochester, NY, USA) were taken from each tooth

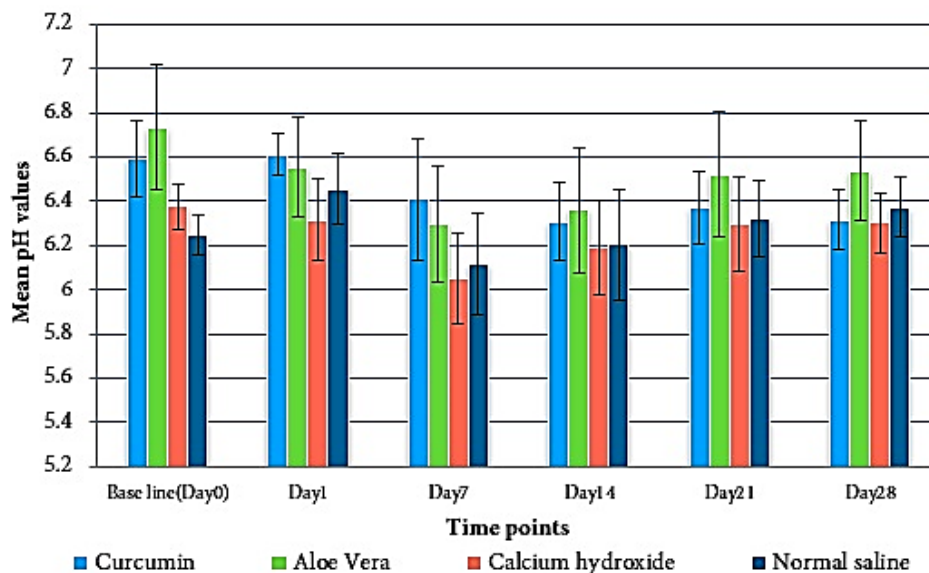


Figure 1. The mean root surface pH values in four study groups at six different time points

in two buccolingual and mesiodistal directions to confirm the presence of a single canal as well as the similarity of the canal shape and root dentin dimensions in all samples. To simulate EIRR lesion, a cavity with a diameter of 1.4 mm and a depth of 0.7 mm was prepared using a 1.4-mm high-speed round carbide bur (DiaTessin, Vanetti, Gordevio, Switzerland) on the buccal surface of each root, 5 mm from the apex [7, 8]. To eliminate the smear layer, the created cavities were filled with 3 mL of 17% EDTA (Morvabon, Tehran, Iran) for one minute, followed by 3 mL of 5.25% sodium hypochlorite (Golrang Pakshu, Tehran, Iran) and then, rinsed with distilled water [7].

The working length was confirmed by taking a radiograph of each tooth with #15 K-file (Mani, Tochigi, Japan). The procedure was followed by preparing the canal with Protaper rotary system (Dentsply Maillefer, Ballaigues, Switzerland) using the crown-down technique with nickel-titanium rotary files: ProTaper S1, S2, F1, and ProFile 25/.04 to 50/.04 (Dentsply Maillefer, Ballaigues, Switzerland). The final instrumentation size for all canals was 50/.04 to standardize the canal size, allowing the same irrigation needle depth and fit (13 mm from the access cavity without binding)[8]. After preparation, the root canals were irrigated using 5 mL of 17% EDTA (Morvabon, Tehran, Iran) followed by 5 mL of 5.25% sodium hypochlorite (Golrang Pakshu, Tehran, Iran) to remove the smear layer. To complete the procedure, the root canals were re-irrigated with 5 mL of distilled water [7]. At the end of the preparation, all root surfaces in each sample were covered with two layers of nail polish [33], except for the lesion area.

The teeth were randomly assigned to four groups ($n=23$). All the root canals were dried using paper points (Meta Dental Co., Seoul,

Korea) before obturation. The first group was filled with curcumin paste, which consisted of curcumin powder and distilled water with a 3:7 weight ratio. The second and third groups were filled with aloe vera gel (Seagull, Tehran, Iran) and calcium hydroxide paste (Morvabon, Tehran, Iran), respectively. The last group was filled with normal saline as the control group. The curcumin and calcium hydroxide pastes were transferred into the root canals with a counterclockwise rotation action of a #30 K-file (Mani, Tochigi, Japan) and packed using paper points (Meta Dental Co., Seoul, Korea) to a 12-mm length from their apices. Next, aloe vera gel and normal saline were injected into the root canals using a sterile syringe with a 25-gauge needle (Ava, Tehran, Iran). Finally, the access cavities and the apices were sealed by modeling wax (Dentsply Sirona, York, PA, USA). All of the samples were restored in vials containing 7.5 mL of normal saline solution at 37°C throughout the study process.

The pH was measured in each vial at 20-min, 24-h, and 7-, 14-, 21-, and 28-day intervals using a digital pH meter (Metrohm AG, Herisau, Switzerland). The pH meter was calibrated at the beginning and after every five measurements. The calibration process was carried out by immersing the tip of the electrode in two buffer solutions. The electrode was flushed with distilled water before and after calibration, and before each measurement [11].

The normality of pH values at different time points was evaluated using Kolmogorov-Smirnov analysis. Since the results demonstrated that the distribution of pH values at each different time point was normal, the data were described by descriptive statistical methods (mean±standard deviation) and analyzed

using repeated-measures ANOVA. The significance level was set at $P < 0.05$ using SPSS software (SPSS version 20.0; SPSS, Chicago, USA).

Results

The mean pH values of four study groups at six measurement intervals are presented in Table 1 and Figure 1. Based on the repeated-measures ANOVA, the pH change over time was significant in all experimental groups ($P < 0.05$). Additionally, there was an interaction effect between the study group and the measurement time, meaning that the effect of different medicaments on the pH of external root surface was not the same at different time points ($P < 0.05$).

Intergroup results revealed that the curcumin group had higher overall mean pH in comparison to the calcium hydroxide ($P < 0.001$) and normal saline groups ($P = 0.003$). In addition, the difference between the pH values of curcumin and aloe vera groups was not statistically significant ($P > 0.05$). Moreover, the aloe vera group showed higher pH values than the calcium hydroxide and normal saline groups ($P < 0.001$). The mean pH of calcium hydroxide and normal saline groups showed no significant difference ($P > 0.05$).

At the baseline (day 0) and days 1 and 7, the mean pH of aloe vera and curcumin groups was higher than the mean pH of calcium hydroxide and normal saline groups ($P < 0.05$). On day 14, the mean pH of aloe vera group was higher than that of calcium hydroxide and normal saline groups ($P < 0.05$). On days 21 and 28, the mean pH in aloe vera group was higher than the mean pH of all the other groups ($P < 0.05$). All other intergroup differences at each time point were not statistically significant ($P > 0.05$).

Intragroup results demonstrated that in the curcumin group, the mean pH decreased from day 1 to day 7 ($P < 0.05$) but increased from day 14 to day 21 ($P < 0.05$). The mean pH of aloe vera group decreased from day 1 to day 7 ($P < 0.05$) and increased from day 14 to day 21 ($P < 0.05$). In calcium hydroxide group, the mean pH decreased from day 1 to day 7 ($P < 0.05$), followed by an increase from day 7 to day 14, and from day 14 to day 21 ($P < 0.05$). The mean pH of the normal saline group increased between the

baseline (day 0) and day 1, and between day 7 and day 28 but decreased from day 1 to day 7 ($P < 0.05$). Changes in mean pH values between all other time points in each study group were not statistically significant ($P > 0.05$).

Discussion

In this *in vitro* study, four groups of permanent teeth were prepared, with 23 teeth in each group. The samples of one group were filled with normal saline as the control group, while the other three groups were filled with three different intracanal medicaments: curcumin, aloe vera and calcium hydroxide. Based on the findings of the current study, both curcumin and aloe vera could affect the pH of external root surface. The overall mean pH of external root surface in the aloe vera group was higher than the curcumin group, and the mean pH in both experimental groups was higher than the calcium hydroxide group. These results suggested higher hydroxyl ion diffusion in these two experimental groups in comparison to the calcium hydroxide group.

A number of previous studies have demonstrated the increasing effect of different intracanal medicaments, including calcium hydroxide, on the pH of external root surface in EIRR lesions due to the diffusion of hydroxyl ions through dentinal tubules [7-9, 12, 14]. However, the results of previous studies on the effect of calcium hydroxide on hydroxyl ions diffusion and root surface pH are controversial [34]. The results of a study by Esberard *et al.* on the effect of calcium hydroxide sealers on pH changes of the root dentin surface demonstrated that these sealers could not increase the pH of root surface to an alkaline level [35]. Moreover, Fuss *et al.* reported that the low solubility of calcium hydroxide and the buffering effect of dentinal tubules inhibit the diffusion of hydroxyl ions through dentinal tubules. Therefore, the pH of external root surface ten days after the application of calcium hydroxide showed no significant change [15]. However; it has to be considered that this buffering effect of the dentinal tubules applies to all medicaments. Therefore, it cannot be a confounding variable in the current study.

Table 1. Mean (SD) of root surface pH values measured in four study groups at six different time points

	Curcumin	Aloe vera	Calcium hydroxide	Normal saline
Baseline (Day 0)	6.592 (0.171)	6.731 (0.282)	6.375 (0.099)	6.250 (0.091)
Day 1	6.609 (0.093)	6.554 (0.223)	6.317 (0.188)	6.453 (0.158)
Day 7	6.410 (0.274)	6.297 (0.260)	6.050 (0.204)	6.116 (0.231)
Day 14	6.306 (0.176)	6.360 (0.284)	6.187 (0.212)	6.204 (0.251)
Day 21	6.371 (0.161)	6.521 (0.283)	6.296 (0.212)	6.322 (0.172)
Day 28	6.317 (0.137)	6.537 (0.226)	6.302 (0.134)	6.374 (0.134)

In this study, the first group was filled with curcumin paste, which consisted of curcumin powder and distilled water with a 3:7 weight ratio. Since previous studies used curcumin as an irrigator or in combination with other medicaments, no studies could be found using curcumin in the form of a paste as an intracanal medicament. Therefore, this was achieved by testing different weight ratios to obtain the best consistency of paste for intracanal application using the method described in methods and materials. A study by Martins *et al.* demonstrated that curcumin in combination with piperine could suppress osteoclastogenesis without adverse cytotoxic effects on periodontal ligament cells [32]. This anti-osteoclastogenesis effect of curcumin along with its anti-inflammatory activity suggests its effectiveness in EIRR treatment.

On the other hand, it has been reported that aloe vera, in association with calcium hydroxide or photobiomodulation, could increase cell viability of fibroblasts in pulp tissue during endodontic treatments [30]. These properties of aloe vera indicate that it is an effective natural medicament for EIRR treatment. Based on the results of this study, it could be interpreted that these two natural medicaments, *i.e.* curcumin and aloe vera, may increase the pH of external root surface, and therefore, compared to calcium hydroxide, they may be more effective in EIRR treatment.

Additionally, the comparison of results at different time points of the study showed an overall decrease in pH in all study groups. This overall decrease in pH values was observed in most studies on the effect of different medicaments on the pH of external root surface. Hewrad *et al.* [8] evaluated the effect of mineral trioxide aggregate and calcium hydroxide on the external root surface pH, reporting that in a 4-week period, pH decreased in both MTA and calcium hydroxide groups.

Furthermore, Çalt *et al.* evaluated the pH changes and calcium ion diffusion after applying calcium hydroxide dressing materials. The results revealed a gradual decrease in pH after three days [9]. Based on a study by Minana *et al.*, a decrease in pH could be related to exposure to CO₂, which might lead to decreased availability of hydroxyl ions due to the chemical reaction between hydroxyl ions and CO₂ from the air; causing a significant drop in pH. However, the latter diffused hydroxyl ions, while samples restored in vials with sealed caps could compensate for the pH drop and increase pH over time [14]. In the current study, the pH decreased in all groups, from day 0 to day 7, followed by an increase from day 7 to day 28. The only exception was the curcumin group, in which the pH decreased from day 21 to day 28. Nonetheless, the controversial results of this study were the outcomes of control group, which

demonstrated increased pH at some levels of the study, specifically on day 1, when the pH of control group increased significantly compared with day 0. Although similar results were observed in some previous studies, in which the control groups were treated by normal saline solution, the increase in pH in the control groups of those studies was not significant [6, 8]. Based on a study by Nerwich *et al.*, this increase could be related to the diffusion of sodium hypochlorite remaining in dentinal tubules during irrigation [12], suggesting that sodium hypochlorite has been a confounding variable in this study and responsible for the gradual increase in pH in the control group from day 7 to day 28 (6.1161 ± 0.23 vs 6.3743 ± 0.13 , respectively). However, the higher mean pH of the control group, compared to the calcium hydroxide group (6.28 ± 0.21 vs 6.25 ± 0.20), cannot be explained by the effect of sodium hypochlorite since it was used for irrigation in all of the study groups.

Considering the low solubility of CH [15] and the controversial results regarding the efficacy of various intracanal application methods of CH [7, 36], the results of the study group treated with this medicament can be explained by the two mentioned factors. In this study, CH paste was placed in prepared root canals using the counterclockwise rotation of a #30 K-file, and then, compacted using paper points [7].

In a study by Forghani *et al.* [7] with a comparable application method of CH, the results demonstrated that the mean pH of CH group decreased from 20 min to 28 days after application (9.10 ± 0.63 vs 8.14 ± 0.56 , respectively). Similarly, pH values decreased between day 0 and day 28 of the current study (6.3757 ± 0.09 vs 6.3022 ± 0.13). However, the overall mean pH of CH group measured during the study by Forghani *et al.* was higher than that of the current study (8.72 ± 0.63 vs 6.25 ± 0.20 , respectively).

To summarize, to the best knowledge of the authors, this study was the first to evaluate the effect of curcumin and aloe vera, as intracanal medicaments, on the pH of external root surface. The results suggest that the two aforementioned herbal medicaments could be appropriate natural alternatives for CH. Nonetheless, considering the controversial results of CH and control groups, further studies are recommended to evaluate the effect of sodium hypochlorite, CH solubility, and its application method on the pH of external root surface. In addition, the current study evaluated the mean pH of the fluid in which samples were immersed. Therefore, measuring the pH of lesion area or the root dentin surrounding it, may demonstrate different pH results since the concentration of hydroxyl ions in this small area differs from a 7.5-mL fluid. Furthermore, since the immersion fluid was not replaced during the study period, it

may have resulted in equilibration and static solution of hydroxyl ions diffusion, followed by gradual pH reduction. Therefore, it is recommended to remove the fluid during the study to simulate the *in vivo* situation and prevent equilibrium in future studies.

Additionally, samples were covered with nail polish in the presented *in vitro* study, and the prepared access cavities as well as apices were sealed with wax, creating an impermeable layer on the root surface and apex. However, in the *in vivo* situation, the apex and lateral canals have a major role in communication between the root canal and periodontium. Overall, it is recommended to simulate a situation much similar to an *in vivo* situation for future *in vitro* studies.

Conclusion

Based on this *in vitro* study, both curcumin and aloe vera may be considered good alternatives for chemical medicaments such as calcium hydroxide in EIRR treatment since they increased the pH of the external root surface. This effect was more significant in the group of teeth treated with aloe vera gel. Nevertheless, further *in vitro* and *in vivo* studies should be conducted to evaluate the precise effect of the two mentioned herbal medicaments and their potential complications in EIRR treatment.

Acknowledgements

This paper is based on Aysan Shahmorad Moghanlou's undergraduate thesis (No. 64100). The authors thank the Dental and Periodontal Research center of Tabriz University of Medical Sciences for their financial and technical support. The authors deny any conflicts of interest regarding the publication of this paper.

Conflict of Interest: 'None declared'.

References

1. Asgary S, Ahmadyar M. One-visit RCT of maxillary incisors with extensive inflammatory root resorption and periradicular lesions: a case report. *Iran Endod J.* 2011;6(2):95.
2. Patel S, Saberi N. The ins and outs of root resorption. *Br Dent J.* 2018;224(9):691-9.
3. Darcey J, Qualtrough A. Resorption: part 1. pathology, classification and aetiology. *Br Dent J.* 2013;214(9):439-51.
4. Yoshpe M, Einy S, Ruparel N, Lin S, Kaufman AY. Regenerative endodontics: a potential solution for external root resorption (case series). *J Endod.* 2020;46(2):192-9.
5. Barbato-Ferreira DA, Costa SFDS, Gomez RS, Bastos JV. DNA Methylation patterns of immune response-related genes in inflammatory external root resorption. *Braz Oral Health.* 2020;34.
6. Lima TFR, Ascendino JF, Cavalcante IdO, Salazar-silva JR, Silva EJNI, Lemos SG, Soares AdJ. Influence of chlorhexidine and zinc oxide in calcium hydroxide pastes on pH changes in external root surface. *Braz Oral Health.* 2019;33.
7. Forghani M, Mashhoor H, Rouhani A, Jafarzadeh H. Comparison of pH changes induced by calcium enriched mixture and those of calcium hydroxide in simulated root resorption defects. *J Endod.* 2014;40(12):2070-3.
8. Heward S, Sedgley CM. Effects of intracanal mineral trioxide aggregate and calcium hydroxide during four weeks on pH changes in simulated root surface resorption defects: an *in vitro* study using matched pairs of human teeth. *J Endod.* 2011;37(1):40-4.
9. Çalt S, Serper A, Özçelik B, Dalat MD. pH changes and calcium ion diffusion from calcium hydroxide dressing materials through root dentin. *J Endod.* 1999;25(5):329-31.
10. Sabbagh S, Shirazi AS, Torabzadeh H. Double antibiotic paste for management of external inflammatory root resorption. *Iran Endod J.* 2018;13(4):569-72.
11. Hermann B. Die Behandlung der entzündeten und infizierten Pulpa und der Pulpagangrän nach der Calxylmethode, *Zahnärztl. Rundschau.* 1940;22(23):24.
12. Nerwich A, Figdor D, Messer HH. pH changes in root dentin over a 4-week period following root canal dressing with calcium hydroxide. *J Endod.* 1993;19(6):302-6.
13. Mozayeni MA, Haeri A, Dianat O, Jafari AR. Antimicrobial effects of four intracanal medicaments on enterococcus faecalis: an *in vitro* study. *Iran Endod J.* 2014;9(3):195.
14. Miñana M, Carnes Jr DL, Walker III WA. PH changes at the surface of root dentin after intracanal dressing with calcium oxide and calcium hydroxide. *J Endod.* 2001;27(1):43-5.
15. Fuss Z, Tsesis I, Lin S. Root resorption—diagnosis, classification and treatment choices based on stimulation factors. *Dent Traumatol.* 2003;19(4):175-82.
16. Finucane D, Kinirons MJ. External inflammatory and replacement resorption of luxated, and avulsed replanted permanent incisors: a review and case presentation. *Dent Traumatol.* 2003;19(3):170-4.
17. Panchal V, Gurunathan D, Thangavelu L. Comparison of antibacterial efficacy of cinnamon extract and calcium hydroxide as intracanal medicament against *E. faecalis*: An *in vitro* study. *Pharmacog J.* 2018;10(6).
18. Asgary S, Nosrat A, Seifi A. Management of inflammatory external root resorption by using calcium-enriched mixture cement: a case report. *J Endod.* 2011;37(3):411-3.
19. Sowjanya J, Chandana C. Antimicrobial efficacy of calcium hydroxide, propolis, and Aloe vera as intracanal medicament—a review. *J Adv Pharm Edu Res.* 2017;7(3).
20. Kusuma CS, Manjunath V, Gehlot PM. Comparative evaluation of Neem, Aloe vera, Chlorhexidine and Calcium Hydroxide as an intracanal medicament against *E. faecalis*—an *in vitro* study. *J Clin I & Diagno Res* 2018;12(3).
21. Borges AH, Guedes OA, Volpato LER, Siebert Filho G, Borba AM, Zina O, Piva E, Estrela C. Physicochemical properties of MTA and Portland cement after addition of Aloe vera. *Iran Endod J.* 2017;12(3):312.

22. Saha S, Nair R, Asrani H. Comparative evaluation of propolis, metronidazole with chlorhexidine, calcium hydroxide and curcuma longa extract as intracanal medicament against *E. Faecalis*—an *in vitro* study. *J Clin Diagn Res.* 2015;9(11):ZC19.
23. de Bretas LP, de Lima CO, Raposo NRB, Aarestrup BJV, do Prado M, Neiva C. Antimicrobial activity and biocompatibility of a calcium hydroxide and aloe verabased intracanal medication. *Rev Bras Odontol.* 2017;74(3):180-6.
24. Zare Jahromi M, Toubayani H, Rezaei M. Propolis: a new alternative for root canal disinfection. *Iran Endod J.* 2012;7(3):127-33.
25. Ahangari Z, Naseri M, Vatandoost F. Propolis: chemical composition and its applications in endodontics. *Iran Endod J.* 2018;13(3):285-92.
26. Sharifian MR, Shokouhinejad N, Aligholi M, Emaneini M, Alizadeh J. Antibacterial Substantivity of Carvacrol and sodium hypochlorite in infected bovine root dentin. *Iran Endod J.* 2009;4(2):45-8.
27. Seghatoleslami S, Samadi N, Salehnia A, Azimi S. Antibacterial activity of endemic *Satureja Khuzistanica* Jamzad essential oil against oral pathogens. *Iran Endod J.* 2009;4(1):5-9.
28. Abbaszadegan A, Gholami A, Ghahramani Y, Ghareghan R, Ghareghan M, Kazemi A, Iraj A, Ghasemi Y. Antimicrobial and cytotoxic activity of *Cuminum cyminum* as an intracanal medicament compared to chlorhexidine gel. *Iran Endod J.* 2016;11(1):44.
29. Valera MC, Cardoso FGdR, Maekawa LE, Camargo CHR, De Oliveira LD, Carvalho CAT. *In vitro* antimicrobial and anti-endotoxin action of *Zingiber Officinale* as auxiliary chemical and medicament combined to calcium hydroxide and chlorhexidine. *Acta Odontol Scand.* 2015;73(7):556-61.
30. Carvalho NC, Guedes SAG, Albuquerque-Júnior RLC, de Albuquerque DS, de Souza Araújo AA, Paranhos LR, Camargo SEA, Ribeiro MAG. Analysis of Aloe vera cytotoxicity and genotoxicity associated with endodontic medication and laser photobiomodulation. *J Photochem Photobiol B.* 2018;178:348-54.
31. Devaraj S, Jagannathan N, Neelakantan P. Antibiofilm efficacy of photoactivated curcumin, triple and double antibiotic paste, 2% chlorhexidine and calcium hydroxide against *Enterococcus faecalis* *in vitro*. *Scientific reports.* 2016;6(1):1-6.
32. Martins CA, Leyhausen G, Volk J, Geurtsen W. Curcumin in combination with piperine suppresses osteoclastogenesis *in vitro*. *J Endod.* 2015;41(10):1638-45.
33. Asgary S, Eghbal MJ, Parirokh M, Torabzadeh H. Sealing ability of three commercial mineral trioxide aggregates and an experimental root-end filling material. *Iran Endod J.* 2006;1(3):101-5.
34. Roghanizad N, Bahreini F, Vatanpour M. Hydroxyl ion diffusion through intact and resorbed roots at various time intervals. *Iran Endod J.* 2011;6(3):107.
35. Esberard RM, Carnes Jr DL, Carlos E. pH changes at the surface of root dentin when using root canal sealers containing calcium hydroxide. *J Endod.* 1996;22(8):399-401.
36. Parhizkar A, Asgary S. Local drug delivery systems for Vital Pulp Therapy: a new hope. *Int J Biomater.* 2021;2021.

Please cite this paper as: Shakouei Bonab S, Samiei M, Shahmorad Moghanlou A. Effects of Intracanal Curcumin, Aloe vera and Calcium Hydroxide during Four Weeks on pH Changes in Simulated Root Surface Resorption Defects: An *In vitro* Study. *Iran Endod J.* 2022;17(4): 172-8. *Doi:* 10.22037/iej.v17i4.35570.