

THE UNIVERSITY OF TEXAS

MD Anderson
Cancer Center[®]

University of Texas MD Anderson Cancer Center

OpenWorks @ MD Anderson

OncoLog MD Anderson's Report to Physicians
(All issues)

OncoLog MD Anderson's Report to Physicians

11-2002

OncoLog Volume 47, Number 11, November 2002

Mariann Crapanzano

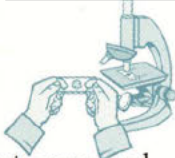Kerry L. Wright

Frank A. Morello Jr. MD

Follow this and additional works at: <https://openworks.mdanderson.org/oncolog>



Part of the [History of Science, Technology, and Medicine Commons](#), and the [Oncology Commons](#)



REPORT TO PHYSICIANS

NOVEMBER 2002 Vol. 47, No. 11

OncoLog

Diagnosis Based on Nonsurgical Biopsy: A Cooperative Effort

by **Mariann Crapanzano**

Many patients who enter a cancer center for examination cross the threshold seeking a diagnosis. Others come for information about a known or suspected recurrence. For some patients, only a surgical procedure will provide the answers; for others, the secrets of their disease that will determine their treatment and prognosis will be discovered before they ever see an operating room.

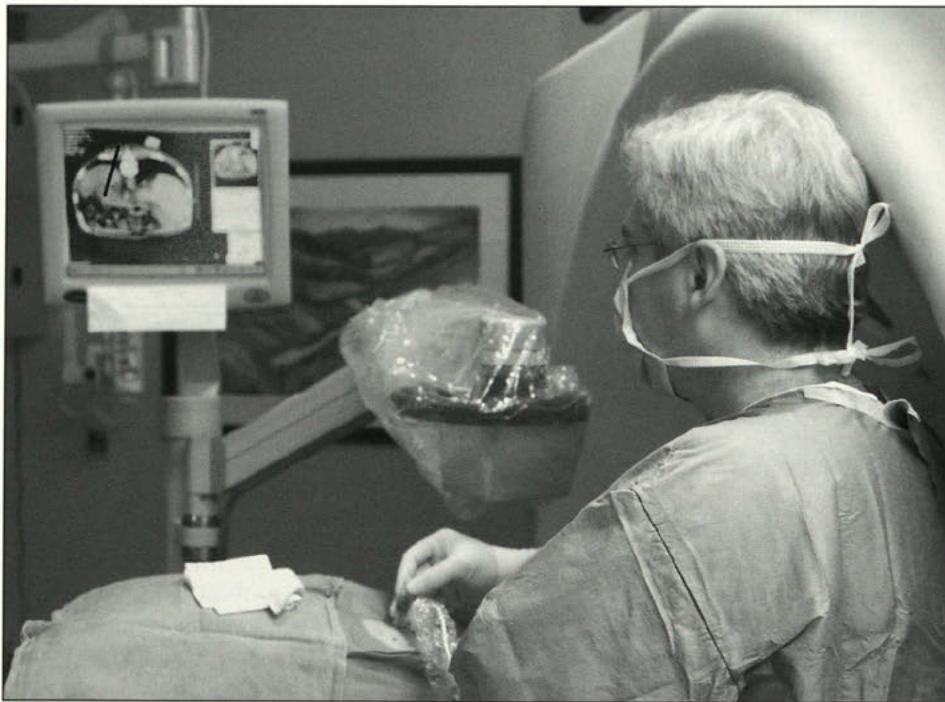
Using advanced imaging modalities and cytologic techniques, several departments and subspecialties at The University of Texas M. D. Anderson Cancer Center work together to sample and diagnose suspicious lesions without surgery. These diagnostic biopsies are often precise enough to not only diagnose a first-time or recurrent cancer but also identify the cancer subtype or give information about whether a recurrent tumor is more or less aggressive than the original tumor.

"It's not just about saying, 'There is tumor there,'" said Marshall E. Hicks, M.D., a professor in the Department of Diagnostic Radiology and chief of the Section of Vascular and Interventional Radiology.

Dr. Hicks heads a team that sees patients referred for the evaluation of

nonpalpable lesions in all major organs and organ systems except the brain, breast, and heart. Using computed tomography (CT), ultrasonography, and fluoroscopy, radiologists identify the lesions and perform image-guided percutaneous fine-needle aspiration

(Continued on next page)



Dr. Marshall E. Hicks, a professor in the Department of Diagnostic Radiology, performs a biopsy using an electromagnetic guidance system that tracks the biopsy needle and displays it on a monitor (image of needle enhanced).

THE UNIVERSITY OF TEXAS
**MD ANDERSON
CANCER CENTER**

Nonsurgical Biopsy Diagnosis

(Continued from page 1)

(FNA) and core-needle biopsies in deep tissues, such as the lung and liver. Most procedures are performed using local anesthesia and conscious sedation, and patients are often given anxiolytic agents, Dr. Hicks said.

A recent addition to the imaging modalities used in the interventional radiology clinic is an advanced PC-based electromagnetic guidance system used during CT interventions to provide real-time virtual tracking of the biopsy needle.

Also guiding the radiologists are cytopathologists, who provide immediate feedback during biopsy procedures. FNA is usually the first-line diagnostic approach used in the interventional radiology clinic, although a core-needle biopsy is sometimes necessary initially. According to Savitri Krishnamurthy, M.D., an assistant professor in the Department of Pathology, if the FNA smear is not diagnostic, the cyto-

pathologist may advise the radiologist to perform a core-needle biopsy.

Because it takes one to two days to process the core biopsy specimen, a “touch prep” of the core is prepared immediately by cytotechnicians, and the cytopathologist (sometimes with the radiologist) evaluates it to determine whether it is adequate for the diagnostic tests that may be needed. All of this is completed—usually within 10 to 15 minutes of the biopsy—while the patient is still on the examination table, so that if more cells or tissues are needed, the radiologist may obtain additional samples right away.

The cytologic analysis of biopsy specimens is not unique to M. D. Anderson. What sets the institution apart from many centers, said Dr. Hicks, is that it has specifically dedicated space, equipment, and staff who daily perform and evaluate such biopsies. This quick cytologic evaluation benefits

the patient by helping to minimize the number of needle insertions, or passes, an advantage that is especially significant in cases that present a risk of complication, such as pneumothorax.

Without the immediate feedback from a cytopathologist who can read small-needle biopsies, Dr. Hicks said, the radiologist would in many cases likely perform a core-needle biopsy, which requires a larger-gauge needle and more time to be processed, to help ensure that the specimen is sufficient for the necessary diagnostic tests.

Many lesions and lymph nodes, such as those in the mediastinum and lung, can be accessed for biopsy using more than one approach, said Dr. Hicks. Thus, the radiologists in the interventional radiology clinic consult with other physicians, such as those who perform endoscopic or bronchoscopic biopsies, to determine the most effective biopsy method.

FNA Clinic Streamlines Biopsy Diagnosis of Palpable Lesions

by Mariann Crapanzano

A patient is referred to the FNA (fine-needle aspiration) Clinic at The University of Texas M. D. Anderson Cancer Center for biopsy of a palpable lesion. The atmosphere is welcoming, and he is surprised to find that the procedure is quick and almost painless. But the biopsy's apparent simplicity is deceiving. With just a tiny sampling of cells, cytopathologists in the FNA Clinic are able to diagnose disease and perform molecular studies to reveal the biologic characteristics and behavior of malignancies. This intimate knowledge of the disease can help physicians individualize treatment planning and monitor protocols.


According to Savitri Krishnamurthy, M.D., an assistant professor in the Department of Pathology and a cyto-

pathologist in the FNA Clinic, the clinic is structured to advance the rapid diagnosis of palpable lesions in a manner that is cost-effective, easy for the patient, and accurate.

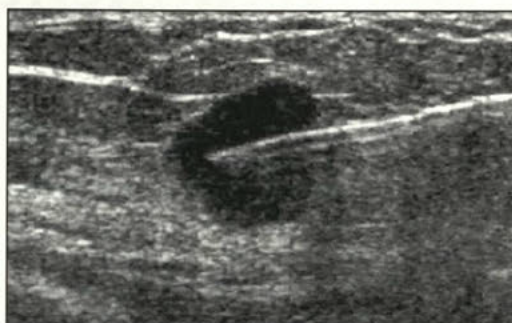FNA is an established diagnostic tool that is used throughout the world, but the FNA Clinic at M. D. Anderson as a dedicated clinic in which pathologists perform FNA biopsies (as well as core-needle and punch biopsies) is a prototype, said Dr. Krishnamurthy. Central to the success of this clinic is the team of cytopathologists, who not only perform biopsies of palpable lesions but also interpret the results—of both the initial staining and the ancillary diagnostic tests—obtained from an FNA specimen.

Breast and lymphoma lesions account for a large portion of the FNA biopsies performed in the clinic. According to Dr. Krishnamurthy, cells are collected from the lesion, and the smears are immediately prepared and evaluated. A diagnosis can be made on

the basis of those smears alone—usually within 15 minutes—in up to 80% of cases, she said. If the initial smears generate only a differential diagnosis,



Dr. Savitri Krishnamurthy, an assistant professor in the Department of Pathology, prepares to perform a fine-needle aspiration (FNA) biopsy on patient [REDACTED] in the FNA Clinic.



This ultrasound image shows the biopsy of a breast lesion using fine-needle aspiration (FNA). Physicians in the Breast Diagnostic Clinic stage breast cancer by sampling lymph nodes at each successive level (e.g., axilla, clavicle, and neck), using FNA and immediate cytologic evaluation, to determine the most distal positive lymph node.

Rodolfo C. Morice, M.D., a professor in the Department of Pulmonary Medicine and chief of the Section of Interventional Pulmonology, performs bronchoscopic biopsies to diagnose pulmonary and mediastinal lesions and to stage pulmonary malignancies. According to Dr. Morice, the selection of modality often depends on the size and location of the lesion: a larger pulmonary lesion that is centrally located in the lung parenchyma may be best approached by a transbronchial

biopsy performed under fluoroscopic guidance, whereas a smaller lesion in the periphery of the lung may be safely and more efficiently approached percutaneously in the interventional radiology clinic. For larger lesions, said Dr. Morice, transbronchial biopsy seems to reduce the risk of pneumothorax.

The biopsy procedures performed by Dr. Morice and his colleagues yield both histologic and cytologic specimens. In some cases, biopsy forceps are used to obtain samples from lesions inside the

bronchial tubes, under direct vision using a bronchoscope; in others, a small-gauge needle is passed through a flexible bronchoscope to access lymph nodes in the mediastinum through the bronchi; and in others, a bronchoalveolar lavage provides cellular washings of the alveoli, often to diagnose infectious complications from chemotherapy. Dr. Morice said that in cases involving immunocompromised patients, cytopathologists provide quick feedback, helping to ensure that the biopsy specimen is adequate for diagnosis or identifying infectious organisms so that appropriate antibiotic treatment can be started quickly.

Patients who are referred for the diagnosis of nonpalpable breast lesions and the staging of breast cancer are seen in the Julie and Ben Rogers Breast Diagnostic Clinic. Within this clinic is the Section of Breast Imaging, which
(Continued on page 4)

then ancillary studies, such as immunocytochemical staining, flow cytometry, electron microscopy, and molecular tests (e.g., fluorescence in situ hybridization and polymerase chain reaction), are performed. The results help guide the clinician who is treating the patient, said Dr. Krishnamurthy. If a definitive diagnosis cannot be achieved, then the clinician decides upon the next course of action, which might include performing a surgical biopsy or monitoring the patient.

FNA biopsy of palpable lesions has several benefits, said Dr. Krishnamurthy. First, it is quick. Second, it is associated with a low morbidity rate and is tolerated well by patients, most of whom do not even require local anesthesia. Third, the cells collected by FNA biopsy can be not only evaluated morphologically but also used to perform a detailed immunophenotypic and molecular analysis. Fourth, FNA allows the pathologist to sample more than one area of the mass.

The risks associated with the procedure are minimal: slight oozing of blood and a remote risk of infection, said

Dr. Krishnamurthy. Although the risk of seeding theoretically exists, it is typically not seen, she said. One limitation of FNA biopsy is that it requires the acquisition of many cells to make a diagnosis, and some lesions (for example, those that are very fibrotic) may not yield cells for analysis. In such cases, or when the analysis fails for technical reasons, the cytopathologist may recommend to the patient's referring clinician that a surgical biopsy be performed.

The cytopathologists in the FNA Clinic at M. D. Anderson perform detailed immunophenotyping and other molecular tests on cytologic material. Immunophenotyping identifies markers unique to each cell type and thus helps confirm a diagnosis.

Cytologic biopsy techniques also are used to monitor changes in a tumor over time. This ability and the precision with which the cytopathologists can define the molecular characteristics of malignant lesions have led to the FNA Clinic's role in serially monitoring the biologic features of malignancies during protocols conducted at M. D. Anderson.

For example, gene microarray analysis of an FNA or core-needle biopsy may reveal why a particular patient's tumor is resistant to one or more chemotherapeutic agents or may show the effect of gene therapy on a particular tumor as a study progresses.

"It helps us to learn what has happened to the cells," said Dr. Krishnamurthy. "Did they all die? Did their morphologic and genetic characteristics change? That's where the gene microarray analysis in those types of protocols helps us."

Dr. Krishnamurthy predicts that FNA biopsy will play an even bigger role in the future. "It is going to be a molecular era," she said. "Tumors are going to be characterized by their genetic characteristics. For that, you need cells to determine what genes the cells have, as well as the status of the transcription of those genes. FNA is the easiest method to get the cells." ●

FOR MORE INFORMATION, contact Dr. Krishnamurthy at (713) 794-5625.

Nonsurgical Biopsy Diagnosis

(Continued from page 3)

is headed by Peter J. Dempsey, M.D., a professor in the Department of Diagnostic Radiology. The needle biopsies that are most commonly performed in the Breast Diagnostic Clinic are the x-ray-guided stereotactic core biopsy (which in the Breast Diagnostic Clinic is typically performed on calcifications detected by mammography) and the ultrasound-guided FNA or core-needle biopsy. Both the stereotactic and the ultrasound-guided core-needle biopsies are processed using the same procedure that is used for surgical biopsy specimens, said Dr. Dempsey, with final results obtained within days. The ultrasound-guided FNA biopsies, however, are fixed, stained, and read within minutes, he said, again calling upon the joint skills of the radiologist and cytopathologist.

"We go in under ultrasound guidance with a small needle and obtain cells," Dr. Dempsey said. "A cytotechnologist is in the room with us. We prepare the slides in the room, and the tech walks them literally around the corner [in the Clinic] and stains them, which takes only about 10 minutes. Then we as radiologists sit down with the cytopathologist ... and together we look at the slides and make a diagnosis."

According to Dr. Krishnamurthy, communication between cytopathologists and radiologists helps to determine whether an FNA biopsy, a core biopsy, or both are appropriate for a particular case.

Throughout M. D. Anderson, the combined efforts of specialists across disciplines help to accurately and efficiently diagnose and stage disease, in many cases sparing the patient a surgical biopsy and in each case bringing the patient closer to an individualized treatment regimen.

"It takes time, it takes patience, and it takes people who are meticulous," said Dr. Dempsey. "A lot of people." ●

FOR MORE INFORMATION, contact
Dr. Hicks at (713) 792-5765,
Dr. Krishnamurthy at (713) 794-5625,
Dr. Morice at (713) 792-4599, or
Dr. Dempsey at (713) 792-2720.

Benign Care: Young Patients Conditions Find Treatment at

by Kerry L. Wright

Its mission is to eliminate cancer, so it may come as a surprise to many that The University of Texas M. D. Anderson Cancer Center also treats some non-cancerous disorders, many of them in children or young adults. Although benign, these conditions either are similar to cancer in behavior or treatment or put patients at risk for a malignancy, all of which make a cancer center an appropriate environment for treating them.

Benign head and neck tumors

Benign tumors often appear on the head and neck. The vascular proliferation known as hemangioma, for example, occurs in 5% to 10% of infants, making it the most common benign tumor in this age group.

Hemangiomas typically appear as small, strawberry-colored spots on an infant's skin, growing until the child is about eight months to one year old and then spontaneously regressing. Fewer than 10% of hemangiomas require treatment, but occasionally they can grow very large.

"Hemangiomas tend to occur in the head and neck area, so they can threaten the airway and start to occlude the eye, which can threaten vision," said Cynthia Herzog, M.D., an associate professor in the Division of Pediatrics. If hemangiomas become large enough to require treatment, prednisone is administered as standard therapy. Interferon has also recently been shown to reduce the size of the proliferations, but while it has a higher response rate than does prednisone, it is more likely to produce toxic

effects, so it is administered only to patients whose disease does not respond to standard therapy.

It is these patients, with hemangiomas that do not respond to prednisone, who are sometimes treated at cancer centers, said Dr. Herzog. Most community dermatologists and pediatricians routinely administer prednisone, but they may not be comfortable giving a patient interferon. Dr. Herzog uses interferon to treat one case of hemangioma every year or two, a very small percentage of the cases that require treatment.

In contrast, benign parotid tumors (which are locally aggressive) and benign thyroid tumors are frequently treated in the Department of Head and Neck Surgery. "By far the most common benign tumors we treat here are benign parotid tumors and benign tumors of the thyroid," said Eduardo Diaz, Jr., M.D., an associate professor in the department. Seventy percent of all thyroid tumors and 80% of all parotid tumors are benign.

These tumors are rarely life threatening, but they can adversely affect a patient's quality of life, said Dr. Diaz. Parotid tumors can be very disfiguring, and thyroid tumors can grow extremely large, compressing internal structures such as the trachea and making it difficult to swallow and breathe.

Both parotid and thyroid tumors, whether benign or malignant, typically encompass important nerves, requiring what Dr. Diaz calls "technically challenging operations." However, these tumors occur most frequently in young adults, who usually recover well from surgery.

Intricate surgeries are also necessary to remove head and neck tumors from young patients with neurofibromatosis, a benign genetic condition associated with several nonmalignant and malignant tumors. (See related article on page 6.)

Giant cell tumor of the bone

Unlike most benign head and neck tumors, which remain local, benign giant cell tumor of the bone can take

with a Variety of Noncancerous M. D. Anderson Cancer Center

on several of the aggressive characteristics of cancer.

"The benign designation is one that is histologic, not one that necessarily reflects its behavior," said Alan Yasko, M.D., an associate professor in the Department of Surgical Oncology and chief of the Section of Orthopaedic Oncology.

Representing about 20% of all benign tumors and about 5% of all musculoskeletal tumors, giant cell tumor of the bone occurs most often in the knee, wrist, pelvis, or sacrum of young adult women, causing extensive destruction of the bone and often disabling surrounding joints. It is locally aggressive, is usually accompanied by a soft tissue mass, can be multicentric, and can recur, actually metastasizing in about 3% of cases.

According to Dr. Yasko, nearly 90% of giant cell tumors of the bone can be treated successfully with curettage, an intralesional excision in which the uninvolved bone and adjacent joints are spared and the remaining bone cavity is filled in with cement. However, effective alternative methods of treatment are being studied for cases in which surgery would be extremely debilitating for the patient.

Embolization, or cutting off the blood supply of the tumor, has been used effectively in select cases to slow progression of the tumor and allow bone to re-form. Similarly, interferon has been shown to decrease the blood supply to these tumors by inhibiting specific angiogenic factors.

Autoimmune diseases of the skin

Both alopecia areata and psoriasis are usually diagnosed by early adulthood, and both arise from immune system abnormalities.

"These conditions are just variations of graft-versus-host disease, where T cells attack the skin," said Madeleine Duvic, M.D., a professor in the Department of Dermatology.

In alopecia areata, a patient's own T cells attack the hair follicles, causing


partial or complete loss of scalp hair and, in severe cases, body hair. In psoriasis, an unknown irregularity induces T-cell proliferation, causing raised patches of overgrown skin to appear all over the body.

Neither of these autoimmune diseases has a cure, although symptoms can be successfully treated with immunosuppressive drugs, immunotherapy, or steroids.

One gene that predisposes individuals to alopecia areata is known to be located on the short arm of chromosome 6 within the major histocompatibility locus, which contains the genes that encode the proteins that must be matched between patient and donor before bone marrow transplantation. Dr. Duvic is particularly interested in identifying the exact location of the gene within this locus.

Toward this aim, the National Institute of Arthritis and Musculoskeletal and Skin Diseases has established a national alopecia areata registry that over the next three and a half years will be collecting blood samples, digital photographs of the scalp, and other clinical data from 2,500 patients with the disorder and their families.

The registry is housed at M. D. Anderson, and Dr. Duvic is the principal investigator. Other participating institutions include the University of Colorado, the University of California at San Francisco, the University of Minnesota, and Columbia University. The resources collected through this project will be used in studies throughout the country to determine the genetic basis of alopecia areata, perhaps helping to explain the causes of other autoimmune diseases as well.



The treatment of benign parotid and thyroid tumors often requires "technically challenging operations" to avoid important nerves, said Dr. Eduardo Diaz, Jr., an associate professor in the Department of Head and Neck Surgery.

"And by studying these diseases, we may learn more about how to prevent or treat graft-versus-host disease, which is really a major impediment to treating cancer," said Dr. Duvic.

Although patients with noncancerous conditions make up only a small percentage of the overall patient population at M. D. Anderson and other cancer centers throughout the country, cancer specialists are working to improve the treatment of these patients, and in turn, the study of benign conditions may help us better understand malignant disease. ●

FOR MORE INFORMATION, contact Dr. Herzog at (713) 745-0157, Dr. Diaz at (713) 745-2231, Dr. Yasko at (713) 794-5242, or Dr. Duvic at (713) 745-1113.

See related article on page 6.

Cognitive Interventions Are Crucial for Many Patients with Neurofibromatosis

by Kerry L. Wright


Neurofibromatosis, while not a cancer, arises in a manner typical of the disease—from a mutation in a tumor suppressor gene. It is also, like many cancers, unpredictable.

Occurring in approximately one of every 4,000 individuals, neurofibromatosis is an autosomal dominant genetic disorder (inherited or occurring through sporadic mutation) that includes variable manifestations that typically emerge in childhood. Its most striking characteristic is the neurofibromas, or benign tumors of the nerve sheath, that surface on the skin and occur internally throughout the body in virtually all patients with the disorder.

“A cancer center is a perfect place for the management of neurofibromatosis because the disease has a high incidence of malignant and nonmalignant tumors,” said Bartlett Moore, Ph.D., an associate professor in the Division of Pediatrics and a neuropsychologist in the Neurofibromatosis Clinic at The University of Texas M. D. Anderson Cancer Center.

In addition to neurofibromas, brain tumors (many of them benign optic gliomas) develop in approximately 15% of patients, and malignant sarcomas develop in some patients. Other common symptoms of neurofibromatosis include benign Lisch nodules in the eye, café-au-lait spots on the skin, freckling on the upper body or groin region, and bone and spine abnormalities. Although there is no specific medical treatment for neurofibromas, the symptoms must be managed. Tumors may require surgery, and other systemic problems, such as hypertension and endocrine dysfunction, require medical intervention.

The Neurofibromatosis Clinic at M. D. Anderson was established in 1992 and is directed by John Slopis, M.D., M.P.H., an associate professor in the Department of Neuro-Oncology. The clinic provides diagnostic screening, tumor surveillance, medical manage-



Dr. Bartlett Moore (left), an associate professor in the Division of Pediatrics, and **Dr. John Slopis**, a clinical assistant professor in the Department of Neuro-Oncology, discuss magnetic resonance images of the brains of children with neurofibromatosis.

ment, and genetic counseling for patients up to 26 years of age.

According to Dr. Moore, between 40% and 50% of children with neurofibromatosis have a cognitive or learning disability or other academic problems, including attention deficit/hyperactivity disorder.

“For many kids with neurofibromatosis, their learning problems are really significant,” Dr. Moore said. Unfortunately, the means by which neurofibromatosis causes these abnormalities are not yet apparent. On magnetic resonance imaging of the brain, areas of high signal intensity appear in 70% of children with neurofibromatosis, but neither the general presence nor the number of these hyperintensive areas seems to correlate with learning difficulties. Nevertheless, in collaboration with Dr. Slopis and Norman Leeds, M.D., a professor in the Department of Diagnostic Radiology; Edward Jackson, Ph.D., an associate professor in the Department of Imaging Physics; and Srikanth Mahankali, M.D., an instructor in the Department of Imaging Physics, Dr. Moore is searching for a connection between the neuroanatomical and cognitive features of neurofibromatosis.

“If the hyperintensities are in an area of the brain called the thalamus, the kids tend to have more memory problems and learning problems,” Dr. Moore said.

Several clinical psychologists and an education specialist (Cynthia Powell, a clinical research coordinator in the Division of Pediatrics) are available in the clinic to counsel and educate patients and their families about these changes and their consequences. Powell helps interpret cognitive tests given to school-age patients to identify any abnormalities that might affect their performance in school.

“Then, if the parent desires, I contact their child’s school to find out what is already being done to meet the needs of the student and to provide information and strategies that can and should increase the chances of success for the student,” Powell said.

All patients with neurofibromatosis treated at M. D. Anderson return each year for screening and testing so that any physical or cognitive changes or symptoms can be detected and managed. More than 300 children and adolescents are receiving care in the Neurofibromatosis Clinic, and an adult neurofibromatosis clinic has recently been established by W. K. Alfred Yung, M.D., professor and chair of the Department of Neuro-Oncology. Dr. Slopis manages the medical care of patients in the adult clinic as well.

“Not only can we now see patients of any age with neurofibromatosis, we can coordinate the medical care of multiple members of the same family,” said Dr. Slopis.

Dr. Moore considers the management of cognitive problems associated with neurofibromatosis extremely important.

“In most cases, the most significant factor for children with neurofibromatosis is to make sure to maximize their school experience because that’s something that is going to have an effect on the rest of their lives,” he said. ●

FOR MORE INFORMATION, contact Dr. Moore at (713) 792-2454 or Dr. Slopis at (713) 500-7098.



Answers to Common Questions about the Use of Radioisotopes for Diagnosis

When physicians need to determine whether a person has cancer, they often use radioactive substances (called radioisotopes or radiopharmaceuticals) to make a diagnosis. A number of different procedures make use of radioisotopes to diagnose cancer or to determine its location and characteristics.

Radioisotopes are used with some types of diagnostic tests to make a particular organ, process, or area of disease stand out more clearly on diagnostic images of the body. If you are told that you should undergo diagnostic testing using radioisotopes, you may have some questions about the procedure. The following are answers to some common questions about the diagnostic use of radioisotopes.

Q: What happens in a diagnostic test using radioisotopes?

A: When you have a diagnostic test using radioisotopes, you are given a very small amount of a radioactive drug, usually as an injection. Different drugs are used, depending on what part of the body is being examined. For example, if the doctor thinks you might have a liver tumor, you would receive a drug that travels to your liver. A machine called a gamma camera then takes images of the affected part of your body. These images help your doctor determine whether you have cancer (or another disease).

In these tests, the amount of radiation that you receive is usually about the same as when you have a chest x-ray (and sometimes less).

Diagnostic tests using radioactive substances are one kind of diagnostic

imaging test. Other imaging tests include x-rays, magnetic resonance imaging (MRI), and computed tomography (CT).

Q: Will it hurt?

A: If the radioisotope is injected, you may feel the needle stick, as with any injection or blood test. Other than that, these tests have the advantage of being virtually painless.

Q: Will I become radioactive after the test?

A: The tiny amount of radioactivity used in diagnostic testing quickly disappears from your body; the radioisotope either passes out of the body or naturally loses its radioactivity.

Q: What diseases can be detected by diagnostic testing with radioisotopes?

A: Radioisotopes can be used to help detect cancers of the lung, parathyroid, liver, prostate, and breast, among others. Additionally, such tests are used to detect heart disease, metabolism disorders, kidney disease, internal bleeding, and many other medical problems.

Q: What are the differences between radioisotopes used for diagnosis and those used for treatment?

A: Radioisotopes can be used both to help diagnose cancer (or other diseases) and to treat disease. However, in diagnostic imaging tests, only very small amounts of radioactive material are used. When radiation is used to treat cancer, the

dose is much larger because it is being used to destroy the cancerous tissue, and there is more concern about this larger amount of radiation causing unwanted effects.

Q: What are the risks associated with diagnostic testing using radioisotopes?

A: Diagnostic tests with radioisotopes are very safe. However, be sure to tell the doctor if you have any allergies to foods, preservatives, dyes (such as dyes used in medical tests), or anything else. Any risks associated with a particular test should be explained to you before the testing is started.

Children can undergo many of the tests that involve radioisotopes. However, you should discuss with your doctor both the risks and benefits of such testing in children.

Q: Are these diagnostic tests safe for women who are pregnant or breastfeeding?

A: Because unborn babies are much more sensitive to small doses of radiation than are children or adults, your physician may decide to use other tests that don't involve radiation. Tell your doctor if you think you might be pregnant or if you are breastfeeding. ●

For more information, contact your physician or contact the M. D. Anderson Information Line:

☎ (800) 392-1611 within the United States, or

☎ (713) 792-6161 in Houston and outside the United States.

November 2002


©2002 The University of Texas M. D. Anderson Cancer Center

DiaLog

“Is This Going to Hurt?”

Frank A. Morello, Jr., M.D.
Assistant Professor
Section of Vascular and
Interventional Radiology

Uncertainty is difficult to endure, even by the most strong-willed and emotionally grounded person. Waiting to find out a score on a test, the reaction to a marriage proposal, or the sex of an unborn



baby can produce so much anxiety that a person cannot properly function until the anxiety is relieved. Imagine, then, the anxiety experienced by someone who is awaiting the results of a diagnostic test for cancer.

Patients often begin their cancer journey at M. D. Anderson Cancer Center with a diagnostic biopsy. They already know that they have a “mass” or some abnormality that may be malignant. The uncertainty of the diagnosis causes stress that is easy to read on patients’ faces and hear in their conversations. Receiving a diagnosis of cancer is one of the most devastating experiences a person can have, but we as physicians can help make the ordeal easier to bear.

Our actions have a greater impact on patients than we may realize, and with a few simple measures, we can make the most of our interactions with them. For example, at least a day before a scheduled biopsy in the interventional radiology clinic, our patients come to the clinic for a consultation visit. They meet with clinic personnel to discuss their upcoming procedure, have all of their

questions answered, and receive instructions about diet or medications for the day of the procedure. This relieves some anxiety on the day of the procedure because the patients have already found the clinic and interacted with some of the staff. Also, they have had time to think about the procedure and gain a full understanding of what will happen, without any surprises.

On the day of the procedure, patients receive an intravenous sedative to help them relax and remain still during the biopsy. Despite this, the most commonly asked question is, “Is this going to hurt?” If not properly addressed beforehand, the uncertainty of pain causes anxiety, which can be detrimental to the success of the procedure. A simple, direct description of what kind of pain will be encountered and when changes this uncertainty to a certainty, which is much easier to cope with. Providing this information may actually reduce the perception of pain, as many of our patients say that it was not as bad as they thought it would be.

A positive experience during the biopsy procedure sets the stage for the remainder of a patient’s time at M. D. Anderson. But the cancer experience will always include some uncertainty. Once a positive diagnosis is established, the uncertainty of treatment becomes the patient’s main focus. Then, it is the treating physician who must help the patient deal with that anxiety. If we properly address questions such as “Is this going to hurt?” our patients will develop a sense of trust in our hospital and staff that will give them the hope they need at every stage of their journey with cancer.

OncoLog

The University of Texas
M. D. Anderson Cancer Center

President
John Mendelsohn, M.D.

Executive Vice President
and Chief Academic Officer
Margaret L. Kripke, Ph.D.

Vice President for Educational Programs
Stephen P. Tomasovic, Ph.D.

Director, Department of
Scientific Publications
Walter J. Pagel

Managing Editor
Dawn Chalaire

Contributing Editors
Mariann Crapanzano
David Galloway
Katie Matias
Michael Worley
Kerry L. Wright

Design
The Very Idea®

Photography
Jim Lemoine

Editorial Board
Rena Sellin, M.D., Chair
Therese Bevers, M.D.
Thomas Burke, M.D.
David Callender, M.D.
Ka Wah Chan, M.D.
Steven Curley, M.D.
Eduardo Diaz, Jr., M.D.
Larry Driver, M.D.
Frank Fossella, M.D.
Lewis Foxhall, M.D.
Robert Gagel, M.D.
Sergio Giral, M.D.
Martyn Howgill
Jeffrey Lee, M.D.
Charles Levenback, M.D.
Moshe Maor, M.D.
Shreyaskumar Patel, M.D.
Geoffrey Robb, M.D.
Eric Strom, M.D.
Christopher Wood, M.D.
Alan Yasko, M.D.

Published by the Department of Scientific
Publications-234, The University of Texas
M. D. Anderson Cancer Center, 1515 Holcombe
Boulevard, Houston, Texas 77030, 713-792-3305.

Made possible in part by a gift from the late
Mrs. Harry C. Wiess. Not printed at state expense.

NCI® A Comprehensive Cancer
CCC Center Designated by the
National Cancer Institute