

# Professional Standards in Medical Ultrasound – EFSUMB Position Paper (Long Version)

## General Aspects

## Professionelle Standards im medizinischen Ultraschall – EFSUMB Positionspapier

### Allgemeine Aspekte

#### Authors

Matthias Wüstner<sup>1</sup>, Maija Radzina<sup>2,3</sup>, Fabrizio Calliada<sup>4</sup>, Vito Cantisani<sup>5</sup>, Roald Flesland Havre<sup>6,7</sup>, Klaus-Vitold Jenderka<sup>8</sup>, Adnan Kabaalioglu<sup>9</sup>, Milan Kocian<sup>10,11</sup>, Christian Kollmann<sup>12</sup>, Julian Künzel<sup>13</sup>, Adrian Lim<sup>14</sup>, Giovanni Maconi<sup>15</sup>, Vladimir Mitkov<sup>16</sup>, Alina Popescu<sup>17</sup>, Adrian Saftoiu<sup>18</sup>, Paul S. Sidhu<sup>19</sup>, Christian Jensen<sup>20</sup>

#### Affiliations

- 1 Central Interdisciplinary Sonography, Krankenhaus der Barmherzigen Brüder, Trier, Germany
- 2 Radiology Research laboratory, Riga Stradins University, Riga, Latvia
- 3 Diagnostic Radiology Institute, Paul Stradins Clinical University Hospital, Riga, Latvia
- 4 Department of Radiology, Policlinico San Matteo, Pavia, Italy
- 5 Department of Radiology, “Sapienza” University of Rome, ROME, Italy
- 6 Department of Medicine, Haukeland University Hospital, Bergen, Norway
- 7 National Centre for Ultrasound in Gastroenterology, Haukeland University Hospital, Bergen, Norway
- 8 FB INW, Hochschule Merseburg, Germany
- 9 Radiology, Istanbul Medeniyet University, Istanbul, Turkey
- 10 Anästhesie und Intensiv, Asklepios Klinik, Burglengenfeld, Germany
- 11 Visual Medicine s. r. o., Olomouc, Czech Republic
- 12 Center for Medical Physics & Biomedical Engineering, Medical University Vienna, Austria
- 13 Otorhinolaryngology, University of Regensburg, Germany
- 14 Imaging, Imperial College, London, United Kingdom of Great Britain and Northern Ireland
- 15 Gastroenterology Unit, Department of Biomedical and Clinical Sciences, “L. Sacco” University Hospital, “L. Sacco” University Hospital, Milan, Italy
- 16 Diagnostic Ultrasound Division, Russian Medical Academy of Continuous Professional Education, Moscow, Russian Federation
- 17 Gastroenterology, University of Medicine and Pharmacy, Timisoara, Romania
- 18 Res Ctr Gastroenterol Hepatol, University of Medicine and Pharmacy of Craiova, Romania
- 19 Radiology, King’s College London, United Kingdom of Great Britain and Northern Ireland

20 Klinik für Innere Medizin, Krankenhaus Märkisch Oderland Strausberg/Wriezen, Germany

#### Key words

ultrasound, education, training, quality assurance, imaging

received 28.07.2021

accepted 09.05.2022

published online 2022

#### Bibliography

Ultraschall in Med

DOI 10.1055/a-1857-4435

ISSN 0172-4614

© 2022, Thieme. All rights reserved.

Georg Thieme Verlag KG, Rüdigerstraße 14, 70469 Stuttgart, Germany

#### Correspondence

Dr. Matthias Wüstner

Central Interdisciplinary Sonography, Krankenhaus der Barmherzigen Brüder, Trier, Krankenhaus der Barmherzigen Brüder, Nordallee 1, 54292 Trier, Germany

Tel.: +49/6 51/2 08 18 80

m.wuestner@mail.de

#### ABSTRACT

This first position paper of the European Federation of Societies for Ultrasound in Medicine and Biology (EFSUMB) on professional standards presents a common position across the different medical professions within EFSUMB regarding optimal standards for the performing and reporting of ultrasound examinations by any professional ultrasound operator. It describes general aspects of professionalism that ensure procedure quality, effectiveness, efficiency, and sustainability in virtually all application fields of medical ultrasound. Recommendations are given related to safety and indication of ultrasound examinations, requirements for examination rooms, structured examination, systematic reporting of results, and

management, communication and archiving of ultrasound data. The print version of this article is a short version. The long version is published online.

## ZUSAMMENFASSUNG

Dieses erste Positionspapier der European Federation of Societies for Ultrasound in Medicine and Biology (EFSUMB) zu professionellen Standards beschreibt eine gemeinsame Position der verschiedenen medizinischen Berufe innerhalb der EFSUMB zu optimalen Standards, wie Ultraschall-Untersuchungen von jedem professionellen Untersucher durch-

geführt und befundet werden sollten. Beschrieben werden allgemeine Aspekte der Professionalität, die die Qualität, Effektivität, Effizienz und Nachhaltigkeit in praktisch allen Anwendungsbereichen des medizinischen Ultraschalls gewährleisten. Empfehlungen werden gegeben zur Sicherheit und Indikationsstellung von Ultraschall-Untersuchungen, zu Anforderungen an Untersuchungsräume, zur strukturierten Untersuchung und systematischen Befundung sowie zur Verarbeitung, Kommunikation und Archivierung von Ultraschalldaten. Die gedruckte Version dieses Artikels ist eine kurze Version. Die lange Version wird online veröffentlicht.

## 1. Introduction

In 2006, the Education and Practical Standards Committee (EPSC) of the European Federation of Societies in Medicine and Biology (EFSUMB) developed a set of minimum training requirements [1] recommending structured theoretical and practical training for gynecological, obstetric, gastroenterological, nephro-urological, breast, and vascular ultrasound (US). Three levels of training and expertise were proposed, and a curriculum for each of the three levels of training was developed for the many different fields of US application. The paper also acknowledged that a systematic recording of findings of any US examination in the patient records was mandatory.

Now, the EFSUMB has described a concept of professionalism, which aims to make medical US a reliable professional service based on common and uniform quality standards with respect to regular service structures and management when US examinations are performed. This includes a relevant clinical indication, followed by a thorough and structured US examination with reliable and comprehensible storage of images/cine-loops and a clear systematic report.

The presented standards may appear demanding and not all US professionals currently in practice may achieve them. Nevertheless, the EFSUMB is committed to the approach of developing optimal rather than minimal professional standards with respect to exemplary patient care.

Professional medical US practitioners in Europe, including physicians and non-physicians who specialize in US, must all have completed comprehensive curricular training and received formal approval by the different national regulatory authorities to comply with legal regulations.

This EFSUMB position paper has been prepared following the EFSUMB regulations for the preparation of policy documents [2] and has been approved by the EFSUMB Executive Bureau. Therefore, the paper presents a common position across the different medical professions within the EFSUMB regarding the optimal standards for the performing and reporting of US examinations reported by any professional US operator regardless of where and “who performs your scan” [3] and other variable conditions in the respective national health care systems.

## 2. Legal Aspects and Indication for Medical Ultrasound

All medical facilities providing US services, i. e., hospitals, doctor's offices, outpatient clinics, and other health service institutions, under whose legal responsibility medical ultrasonography is carried out, are legally and ethically responsible for the proper training of personnel to safely use equipment of appropriate quality with an understanding of the limitations of medical ultrasound [1].

US devices, including hand-held devices, are subject to a medical device regulation – Regulation (EU) 2017/745 of the European parliament and of the council of April 5, 2017 on medical devices [4] – and national implementation is undertaken under the Medical Product laws of the individual countries, e. g. [5, 6]. A special institution (notified body) within Europe certifies if the device is in compliance with these directives before the product is sold by the manufacturer or importer. After a positive evaluation the CE-mark is given with a 4-digit number to identify this notified body [7]. Additional information about the possible output values (thermal/mechanical index) of this device for the user is also integrated into this CE-mark evaluation.

In the USA medical devices are regulated by the Food and Drug Administration (FDA) [8]. These regulations classify the application risk of a device and can define upper output limits (e. g., spatial peak temporal averaged intensity  $720 \text{ mWcm}^{-2}$  for all US applications except ophthalmology with only  $50 \text{ mWcm}^{-2}$ ) or output values that have to be displayed by the manufacturer for users. Additionally, information about compliance with international/national standards concerning general requirements for basic safety and essential performance is required to be stated [9–11].

In practice, the user can see the active output with regard to two indices: the mechanical (MI) and thermal index (TI) that have to be displayed on the monitor. Depending on the individual settings, these indices are changed online and should not exceed the maximum values specified as “Good Practice” for the specific medical application. In general, for all applications the ALARA principle (as low as reasonably achievable) is always the best choice according to a benefit/risk-analysis in unclear situations.

In any situation, US practitioners should follow the safety recommendations given by national and international societies and their special committees [12, 13].

Regular long-term certified maintenance of US equipment and transducers is mandatory to ensure optimal function of the different US techniques. Maintenance should be performed within the optimal standards described by equipment manufacturers.

**Position Statement 1: Medical facilities are responsible for safety, legal aspects of ultrasound services, and the regular maintenance of medical ultrasound equipment (agree/disagree/abstain: 17/0/0).**

As with any medical imaging procedure, a US examination should only be performed for a reasonable medical indication. Although the risk is very low, the potentially harmful physical effects of US energy on examined body tissues [14] must be taken into account when establishing the indication. The purpose, procedure, limits, and complications of the US examination, particularly for invasive US-guided procedures, for which informed written or verbal consent is required, should be explained to the patient. "Preventive" whole-body US examinations of asymptomatic persons are not recommended. They have no medical indication and are controversial as part of a general health check, owing to incidental findings which may be of uncertain clinical relevance and false-positive findings with potentially negative psychological, medical, and economic effects [15, 16].

**Position Statement 2: Every ultrasound examination requires an appropriate medical indication and justification (17/0/0).**

### 3. Organization of Medical Ultrasound Service

Medical facilities dedicated to training doctors or other healthcare professionals who perform ultrasound scans, such as university clinics, teaching hospitals, and other medical training centers, departments, sections, or similar work units providing medical US services, should have a responsibility hierarchy. They should be managed and headed by a responsible US practitioner with the highest level of expertise. The organization of the US service must allow for continuous training, supervision, and quality assurance of novices and practitioners with less experience. The most suitable and beneficial manner in which this teaching and expertise development can occur is the "mentoring" system, where two practitioners, one senior and one junior, take turns performing scanning in the same room in order to ensure supervision, teaching, continuous learning, and professional development to keep the diagnostic professional standard of the staff stable over a long period.

Previous patient examination findings and clinical information should be available to the examiners before starting any new patient examination. This applies to images and written reports for diagnostic imaging – not only previous US exams but also other relevant imaging (CT, MRI, X-ray, endoscopy, laboratory findings, etc.) – and the patients' clinical records. In a digitalized workflow this requires access to a Picture Archiving and Communication System (PACS) and hospital information system in the US room.

Activities that can be delegated to (non-scanning) US assistants include all organizational work regarding patient appointment scheduling, patient transport organization, patient reception, in-department management of patients, examination

preparation, environmental maintenance and material supply organization, patient support to the examination couch, and routine documentation.

**Position Statement 3: Medical ultrasound services with a training mandate should facilitate continuous training and mentoring, ideally delivered in teams of two practitioners (16/1/0).**

### 4. Medical Ultrasound Scanning Room

The spatial design of US rooms and departments should take into account the spectrum and workload with respect to performed examinations and interventions. An efficient workflow, adequate lighting conditions, compliance with hygienic working conditions, and patient safety must be ensured through appropriate room design. Each examination room should provide sufficient space for US equipment, stretcher and/or patient bed, examiner, documentation station, disinfectant facilities and must also allow for emergency patient care. Intervention rooms require additional space for assistance, intervention equipment, preparation and processing of biological material, resuscitation equipment, and patient transfer. A working surface for sterile material, patient monitoring, oxygen supply, and infusion, as well as dimmable room lighting and a movable spotlight are preconditions for US-guided interventions.

The size of dedicated rooms needed to ensure an ideally efficient workflow in medical ultrasound depends on several sub-functions and where to place them. The following paragraph lists typical sub-functions and their space requirements [17, 18].

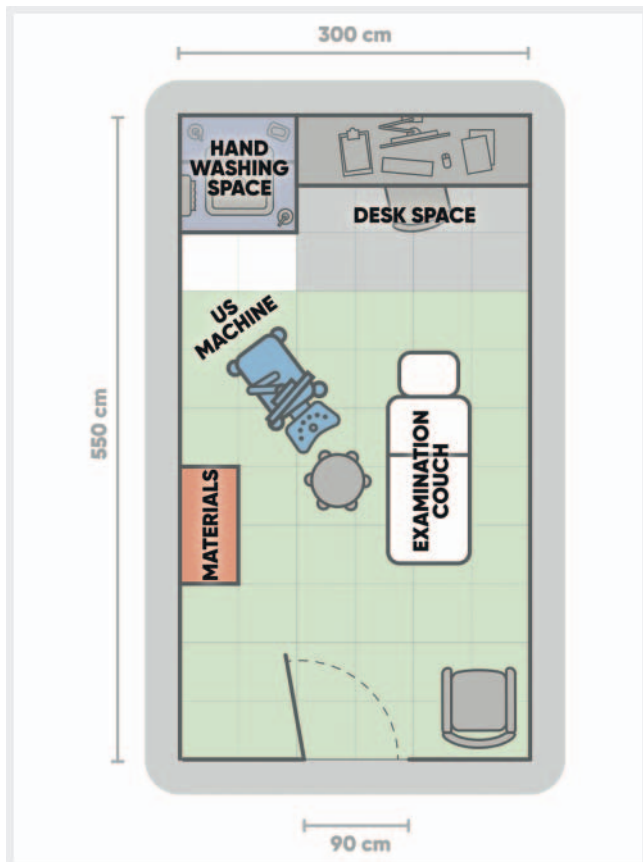
Single US room:

A) Core space:

- US workstation for ambulatory patients alone: the examination couch plus 1 m in every direction, including the space for the US unit (referred to in the figures as a light green rectangle) makes 12 m<sup>2</sup> [18]. With the addition of a desk and a handwashing sink, 16 m<sup>2</sup> of space are required (► Fig. 1)
- US workstation for both ambulatory and bedridden patients: e. g. 25 m<sup>2</sup> for additionally placing a bed perpendicular to the examination couch. The examination couch should not have to be moved away to make space for a patient bed. The US system can be turned 90° towards either the couch or the patient's bed (► Fig. 2).

B) Additional space requirements for:

- Organizational assistant desk space: e. g., 3 m<sup>2</sup>
- Reporting desk space: e. g., 3 m<sup>2</sup>
- Staff hand washing sink space: e. g., 1.5 m<sup>2</sup>
- Patient hand washing sink space: e. g., 1.5 m<sup>2</sup>
- Teamwork space for junior US practitioner in training: e. g., 2 m<sup>2</sup>
- Patient's changing room(s): e. g., 2 m<sup>2</sup> each
- Simple interventions such as fine needle punctures including preparation and handling of potentially infectious aspirated biological material: e. g., 2 m<sup>2</sup> (► Fig. 3)
- Complex interventions such as drainage procedures with sterile instrument table plus 1 m free space around for sterile dressed assistant person: e. g., 8 m<sup>2</sup> (► Fig. 4)



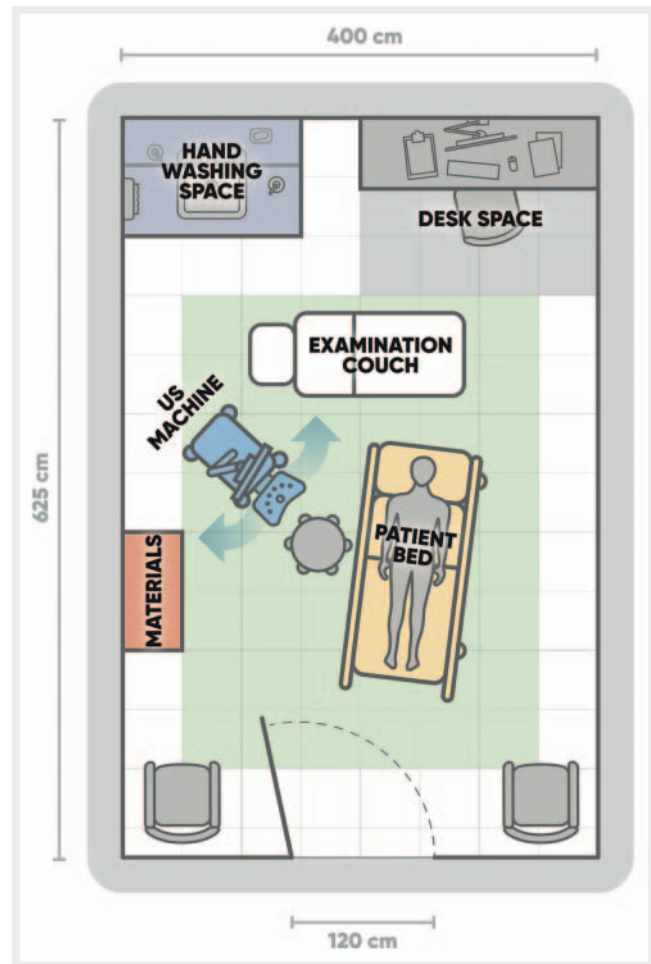
► **Fig. 1** Minimum requirement for a basic ultrasound room for outpatients only: for an examination couch plus 1 meter in each direction and the ultrasound machine,  $3 \times 4$  m are required ( $12 \text{ m}^2$ , light green area, to reappear in the following bigger room figures). To additionally include a desk area and hand washing area, the space requirement is approximately  $17.5 \text{ m}^2$  (e. g.  $5.5 \times 3$  m).

The specified numbers are net space requirements. Additional space will be necessary for walls to separate certain areas, for example

- Patient changing rooms
- Separation of certain work processes for hygienic reasons
- Separation of reporting and communication of patient data and findings for organizational/privacy/data protection reasons.

The space required for medical US can be calculated by combining the modular functional parts that are needed, e. g.,  $16.5 \text{ m}^2$  for a US room for ambulatory patients only (► **Fig. 1**), while  $25 \text{ m}^2$  are needed for a US room with one desk for one US practitioner in a hospital (► **Fig. 2**), with or without one changing room.

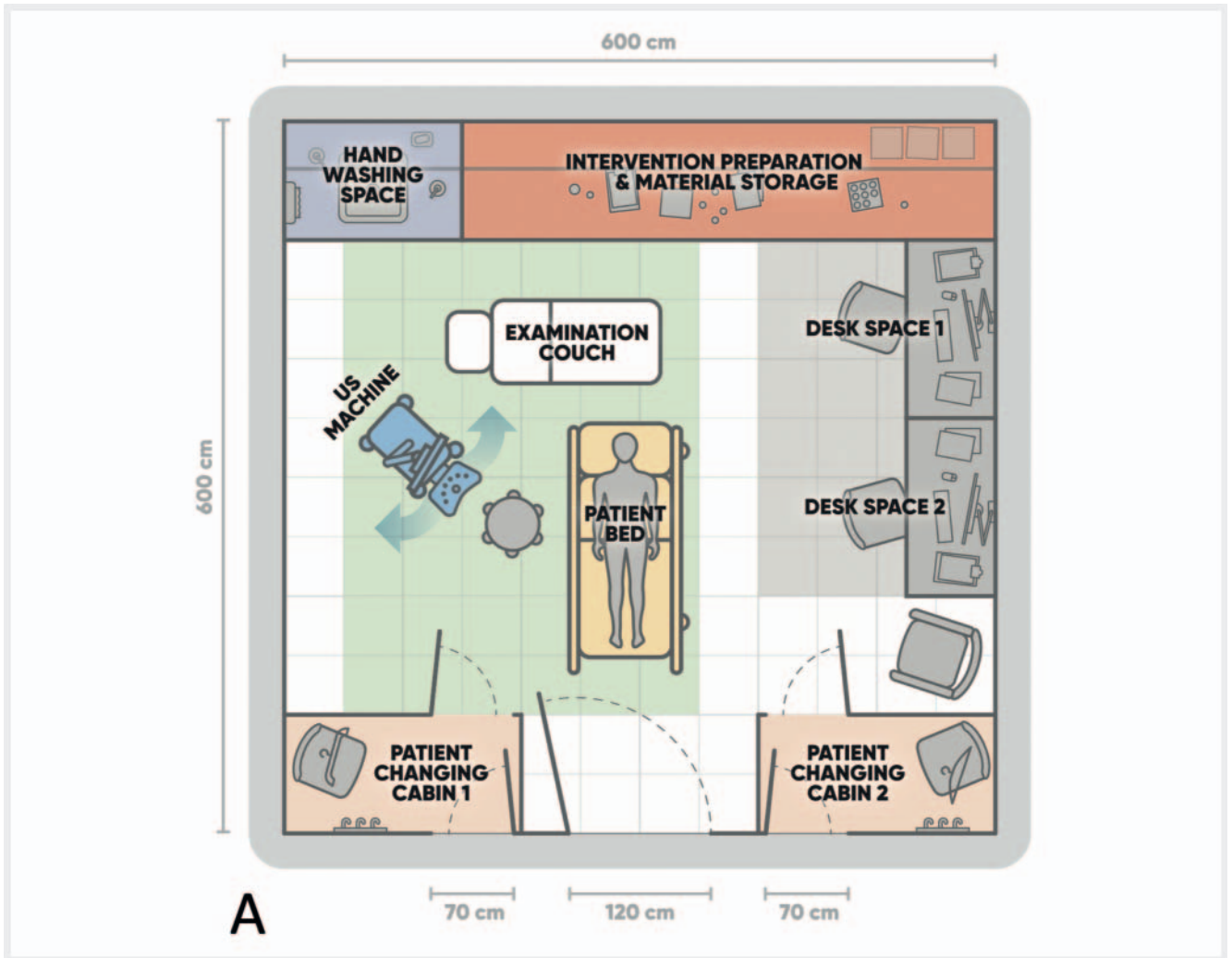
The optimal size of an efficient US room in a hospital, including space for a team of two US practitioners, two changing rooms for a quick workflow, space for an organizational/documentation assistant, space for performing simple interventions, is at least  $36\text{--}42 \text{ m}^2$  (► **Fig. 3**) or  $45 \text{ m}^2$  (► **Fig. 4**), when complex interventions with a sterile instrument table setup are to be performed [17]. Providing privacy for focused work on the report and telephone communication separate from the patient will need even more space either inside the room or in an extra room.



► **Fig. 2** Minimum requirement for a basic clinical ultrasound room for ambulatory and bedridden patients in a hospital:  $20 \text{ m}^2$  ( $4 \times 5$  m, light green area plus adjacent white area) must be provided for an examination couch and patient bed, the ultrasound machine (to be turned  $90^\circ$  towards either the couch or the patient's bed) plus 1 m in each direction of the examination couch and the patient bed. Together with a small desk space and hand washing area, the space requirement amounts to approximately  $25 \text{ m}^2$  (e. g.  $6.25 \times 4$  m).

C) Important technical equipment for a professional workflow in an US room:

- Ventilation technology with heating and cooling to ensure a comfortable room temperature for an undressed patient including a sufficient cleaning rate of aerosols (downward airflow better than upward airflow)
- Dimmable ceiling light with remote control
- Movable ceiling mounted spotlight source for interventions
- One computer workstation per person working in the room, typically two, one for the organization and documentation assistant and one for the US practitioner for reporting and documentation, double-screen workstations superior to single screens.
- PACS workstation(s)
- In rooms for complex interventions (e. g., biopsies, drainage, etc.), movable, ceiling-mounted secondary PACS screen to



► **Fig. 3A** Examples of clinical ultrasound room plans for ambulatory and bedridden patients, suitable for performing simple US-guided interventions such as fine needle aspiration and biopsy and for working in a team of two practitioners plus one assisting person for reasons of workflow efficiency, education, and quality assurance. **A** Approximately 36 m<sup>2</sup> (e. g. 6 × 6 m) are required for the examination couch, an additional patient bed, the ultrasound machine, two desk spaces, two patient changing rooms, hand washing space, and a combined bench and cupboard for intervention preparation and material storage.

provide other imaging of the patient (e. g. CT) during intervention near the US system monitor

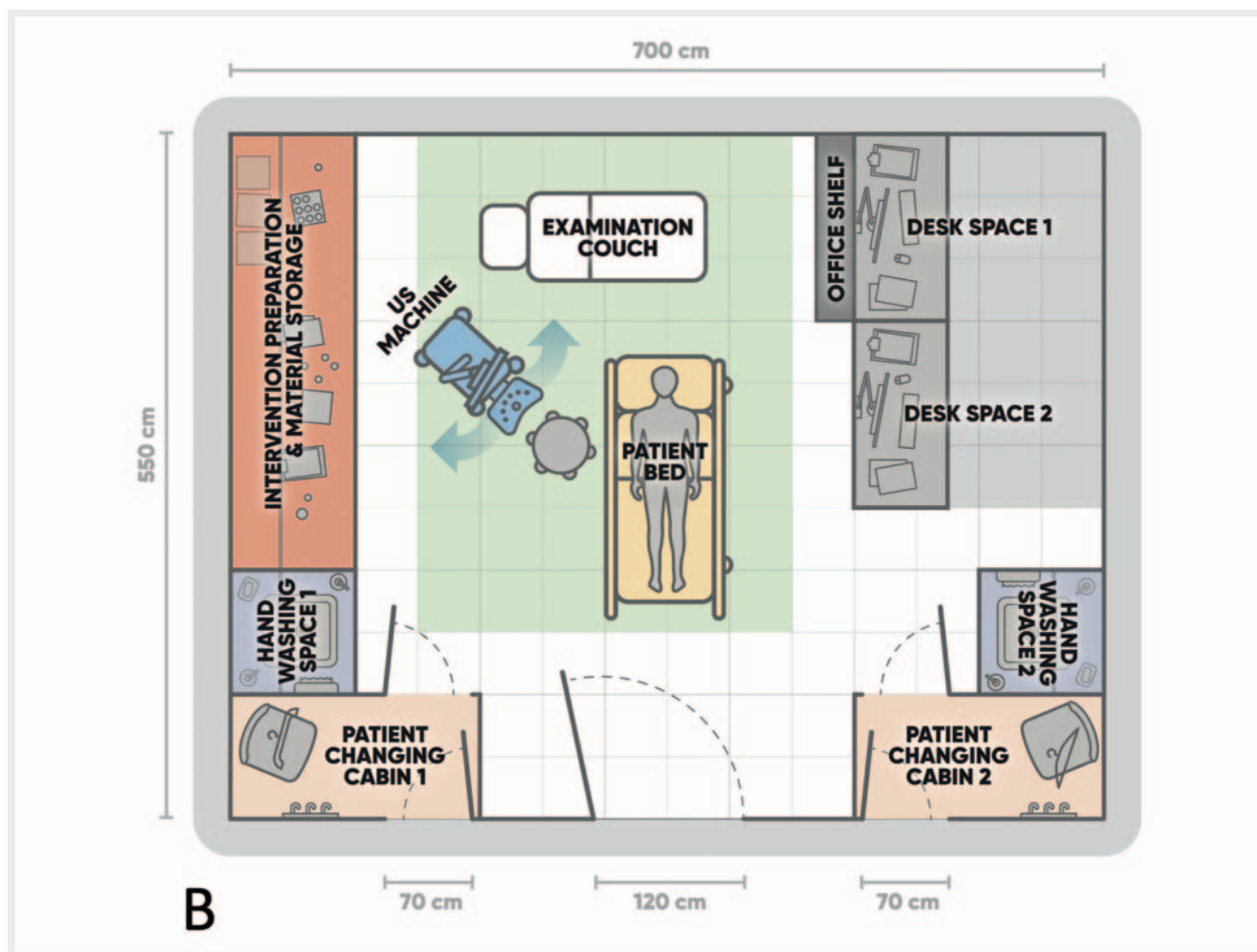
- Stainless steel mobile instrument table
- Ceiling-mounted connection sockets for cables and supply hoses for the US system and the patient as precondition to avoid cables and hoses getting under the wheels of US system, bed, stools, etc.:
  - Power supply for US system and additional technical equipment
  - Network cable to US system/Wi-Fi transponder
  - Oxygen supply
  - Air supply
  - Suction

The following figures show examples of efficient US room designs for different purposes:

**Even more space will be required than the numbers provided in these examples**

- when reporting is to be performed in a separate room, divided from the scanning room by a wall with a door,
- when endocavitary examinations or any other additional aspects need to be included
- when national regulations on hygiene require certain space or even a separate room for cleaning and disinfection of transducers and materials used,
- when structural architecture conditions in an existing building like load-bearing walls or pillars do not allow placement of all modular functions with optimal density.

Further facilities may possibly be placed in additional room(s), especially if there is more than one US scanning room in an institution:



► **Fig. 3 B** Examples of clinical ultrasound room plans for ambulatory and bedridden patients, suitable for performing simple US-guided interventions such as fine needle aspiration and biopsy and for working in a team of two practitioners plus one assisting person for reasons of workflow efficiency, education, and quality assurance. **B** A more comfortable solution can be achieved by moving the desks away from the wall and facing them into the room and placing an office shelf in front of the back desk to prevent the person writing the report from being observed by the patient. To allow clinical observation of the patient, the second desk for the assistant should not be separated by an office shelf. Adding separate hand washing basins for patients and staff requires a total area of at least 38.5 m<sup>2</sup> (e. g. 7 × 5.5 m).

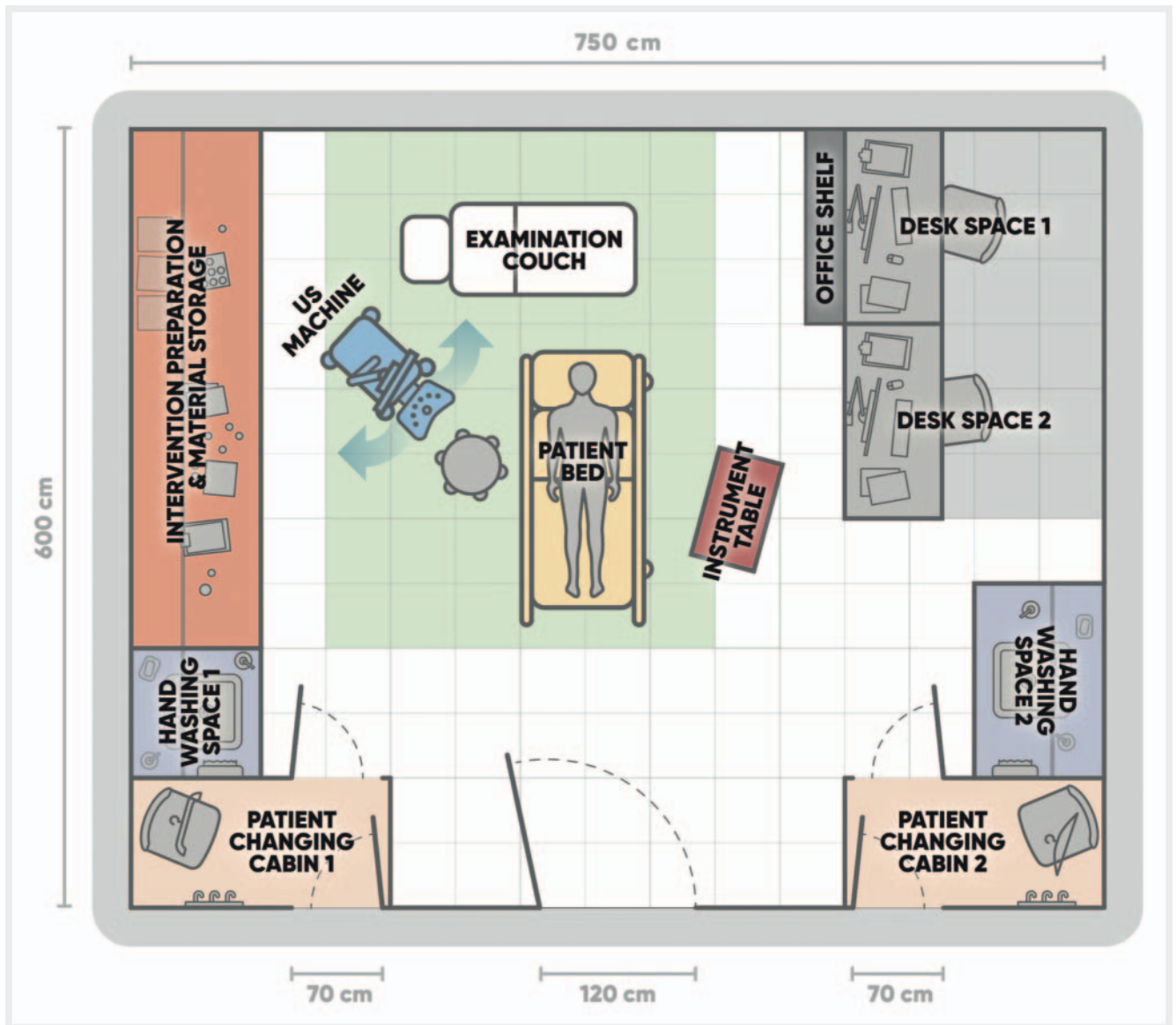
- Material supply storage
- Staff toilet (e. g., 1.5 × 3 m)
- Patient toilet (e. g., 1.5 × 3 m, handicapped accessible: e. g., 4 × 3 m)
- Facilities for disposal and cleaning (excrement from bedridden patients and infectious materials and instruments)
- Staff changing rooms
- Reception desk
- Office for secretariat/administration.

**Position Statement 4: Specifically designed medical ultrasound rooms of appropriate size are recommended for an optimally safe and efficient workflow (17/0/0).**

## 5. Medical Ultrasound Hygiene

Adequate preparation and cleaning of the transducer, US unit and the examination couch are required to avoid potential infection transmission [19–24]. Adherence to published protocols for the cleaning and reprocessing of medical US equipment varies considerably among US practitioners worldwide and is disadvantageous to good practice [25].

Guidelines for transducer and scan hygiene predominantly refer to the use of non-sterile gel as a coupling agent [19–24]. The standard use of spray or liquid disinfectants, which are used to disinfect the transducers before and after use, as coupling agents instead of gel can simplify the workflow and shorten the examination duration per patient. Care should be taken to ensure that only disinfectants compatible with the transducer materials, as documented in the manufacturers' guidelines, are used. Disinfectant sprays and liquids specifically designed for disinfecting mucous membranes (e. g., octenidine) may be superior to alcohol-based disinfectant



► **Fig. 4** Clinical ultrasound room for ambulatory and bedridden patients with two patient changing rooms and two desks, suitable for complex interventions such as drainage procedures: approximately 45 m<sup>2</sup> (e. g. 7.5 × 6 m) are required for an examination couch, an additional patient bed, the ultrasound machine, one desk space for the person to write the report divided from the rest of the room at least by an office shelf, a second desk space for the assistant person with an open view of the patient, two patient changing rooms, two separate hand washing spaces for personnel and patients, a combined bench and cupboard for intervention preparation and material storage and additional space for sterile setup (including sterile instrument table).

coupling agents because they form a lubricating layer on the skin for the transducer instead of evaporating rapidly.

**Position Statement 5: Hygiene plans and standards for cleaning and disinfecting ultrasound equipment should be implemented for every ultrasound service with monitoring of compliance (17/0/0).**

## 6. Structured Medical Ultrasound Examination

US examinations should follow a predefined standardized scheme in which all relevant organs and/or structures are imaged completely and systematically on two planes and in different patient

positions, if appropriate. In addition to normal organs and structures relevant to the indication, all pathological findings should be examined with US when encountered. Complementary US techniques such as Doppler US, elastography, and contrast-enhanced ultrasound (CEUS) should be applied selectively, when necessary, to answer the clinical question or to characterize pathological findings according to accepted practice guidelines [26–29].

Algorithms with predefined transducer positions have been published for almost all US applications, in particular for abdominal US [30–34], thoracic US [35, 36], joint US [37], thyroid US [38, 39], echocardiography [40], vascular US [41–44], and US-guided

interventions [45, 46]. If standard examination algorithms have not been published for a particular US application, the US practitioner should follow an institutional or at least an individual standardized examination scheme to ensure that it is retrospectively clear what was examined and how.

**Position Statement 6: A structured medical ultrasound examination based on standard algorithms is recommended (17/0/0).**

## 7. Acquisition of Medical Ultrasound Images and Cine-Loops

In institutions with a digitized workflow, the complete image bundle of any US examination should be stored digitally, primarily as a DICOM dataset in the system, that ideally covers the patient's entire US examination. The raw data should be available for dedicated software analysis if further processing of the dataset is required (e. g., CEUS or volumetric post-processing). All single images, representative cine-loops, and/or 3 D volume datasets selected by the examiner to demonstrate his diagnostic conclusions should be sent to the PACS unit.

**The still images dataset must include:**

- all organs to be assessed on at least two, ideally perpendicular, planes, both showing the maximal extension of the organ including measurements in 3 dimensions for volume calculation, if applicable,
- all pathologic findings on at least two, ideally perpendicular, planes, both showing the maximal extension of the lesion/pathologic change including measurements in at least 3 dimensions. In case of multiplicity of pathologic lesions, image storage may be limited to a selection, showing the range of variety, including one or more typical "reference lesions" with size/volume measured for follow-up purposes.
- the target lesion/target organ should be:
  - in the center of the image
  - in optimal size
  - with optimal achievable contrast (adjust transducer frequency, frame rate, dynamic range, gain and time gain compensation (TGC) setting)
  - with optimal achievable image definition (adjust transducer frequency and use compounding techniques)
  - measured on each plane with two maximal diameters
  - Organs/lesions too wide to fit into a single transducer aperture width should be recorded with an image widening/panoramic technique or additional cine-loops
- Topographic pictograms are better and more rapidly understood than written transducer position labels, with the advantage of being independent of any language differences.

**Video sequences should be used**

- for complete volume acquisition: ideally two steady sweeps should be taken in the same perpendicular planes as used for the still image documentation of, e. g., a whole organ, organ section, a tumor, or other defined pathologic entity.
- for documentation of certain physiologic or pathologic dynamic phenomena (e. g., heart action, fetal movements, bowel wall movements, blood flow, contrast enhancement, lung sliding):

the respective organ/structure should be taken with the transducer held still in an adapted plane.

- for anatomical representation of an organ/anatomical structure/pathology: The organ/lesion view should be taken in only one steady sweep from the outside of one margin to the outside of the other margin, in a recognizable direction.
- for representation of a dynamic phenomenon (e. g., inner movements, blood flow, contrast enhancement) the cine-loop should contain a representative time period [44].

### 3D volume datasets

may replace cine-loops of steady sweeps through organs or pathologic findings obtained for complete volume acquisition.

### Labeling

Still images and cine-loops should be labeled with appropriate pictograms/terminology/abbreviations (standardized at least on the local US service level). Topographic pictograms are better and more rapidly understood than written transducer position labels, with the advantage of being independent of language differences.

**Non-image information** which must be provided with any still image or cine-loops include:

Patient identification data, institution/examiner identification data, date and time of the examination image or cine-loop

**Additional data** to specify technical details of the exam:

US system/model, US transducer, frequency, mechanical and thermal index, and other technical pre- and post-processing settings used, focus position(s), if applicable.

**Position statement 7: Ultrasound images and cine-loops from all standard ultrasound views and any abnormal finding should be stored and reported (16/0/1).**

## 8. Medical Ultrasound Reporting

The main purpose of the written US report is to communicate findings, conclusions, and the relevance to the clinical enquiry to the referring clinician. In medical facilities, where patient records are kept electronically, US findings should be recorded, reported, and archived electronically, too.

Beside patient identification data, each report should contain relevant information about when, where, and by whom the examination was performed, for what indication, and which equipment was used. Subsequently normal and pathological findings must be documented in a systematic approach. Limitations of the examination quality and confidence level should be indicated.

What to communicate to the patient during, or shortly after the examination, depends on the circumstances of the examination.

A **structured report** using standardized reporting templates that is either self-designed or from commercially available software solutions, designed specifically for US, using globally accepted lexicons is recommended for a medical US examination. Conventional reports are basically written as long sentences, with certain fixed expressions describing normal and pathological findings. Structured reporting using digital "report templates" standardizes and simplifies reports by sometimes exchanging the sentences with short phrases and giving the examiner a chance to



► **Table 1** Mandatory content of ultrasound examination reports.

1.	<i>Institutional identification (name of hospital/practice/referring physician and investigator identification)</i>
2.	<i>Patient identification (family name, first name, sex, birth date. Patient's address may, in hospitals, be replaced by internal file number to relate patient data to medical history and address data stored in central system: e. g. HIS)</i>
3.	<i>Date and time of US examination</i>
4.	<i>Relevant anamnestic and clinical information stating the indication for the examination</i>
5.	<i>Diagnostic question(s) to be solved by the US examination</i>
6.	<i>Scanning conditions and, if so, limitations of the examination, e. g., regions/organs not seen</i>
7.	<i>Descriptions of US appearance of organs and pathologies The report should describe image characteristics in grayscale or Doppler US using standardized terminology, but not clinical diagnoses. It is advised to use text modules for normal findings and frequent pathologies. The description should use these categories for organs or structures: Position – Size – Shape – Contours – Echogenicity – Echo Texture – Tubular Structures (vessels, ducts) – phase-specific enhancement pattern with US contrast agent, relative stiffness with US elastography.</i>
8.	<i>Summary or interpretation including (suspected) diagnoses Three parts are advised: a) Answering the clinical question(s) raised b) Listing other pathologic findings possibly in the order of their clinical relevance (e. g., potential malignancies prior to simple cysts) c) Closing remark about the remainder of the examined areas, excluding other abnormalities in relation to possible limitations, e. g., due to unfavorable examination conditions A cautious interpretation of images is advised to avoid potentially false conclusions. Diagnostic statements should not predetermine the absolute diagnosis, e. g., "patient has metastases", but instead keep the relation to the method used: e. g., "typical sonographic appearance of metastases".</i>
9.	<i>Diagnostic and/or therapeutic consequences, possibly including suggestions for further diagnostic workup or follow-up Imperative instructions for further patient management within the examination report derived from US findings may cause medicolegal problems if a recommended action is not implemented by the clinically responsible physician. Therefore, considerations regarding further medical management should be formulated as suggestions rather than recommendations (e. g., not "surgery is necessary" but instead "surgery is worth considering").</i>

select different options quickly [47–52]. Structured documentation has proven to be a promising approach to standardizing findings, improving the overall reporting quality of various diagnostic modalities, and facilitating interdisciplinary communication [53–58]. In addition, referring physicians and US practitioners generally prefer structured reports over free-text findings [59–61]. Since US plays a key role in patient follow-up and treatment planning, comprehensive and understandable reports are essential. Complete and unequivocally interpretable initial findings are the basis for follow-up examinations and are essential for the subsequent examiner to evaluate the presence of any changes.

Inexperienced examiners, in particular, can benefit from the use of structured documentation, as relevant content and the naming of anatomical structures are indicated and the recommended terminology is offered during the preparation of the report, thus serving as a checklist for the examiner [52, 60, 61]. It is the responsibility of senior physicians to supervise the preparation and quality of findings during specialty training. The report templates must correspond to a systematic standardized US examination of the respective examination type (e. g., abdominal, echocardiography, joint, obstetric, endoscopic, etc.). Some manufacturers have initiated the incorporation of report templates in the US equipment. US report templates are also provided by several Radiology Information Systems (RIS).

For particular examination types, "Imaging Reporting and Data Systems", with the goal of standardizing malignancy risk stratification criteria for reliable US assessment and reducing interpretation variability, e. g. Breast Imaging Reporting and Data System, BI-RADS [53], Thyroid Imaging Reporting and Data System, TI-RADS [55], or Liver Imaging Reporting and Data System,

LI-RADS [56–58] may be used as key elements of structured US reporting [53].

Future perspectives are in a line with Artificial Intelligence (AI) developments, where trained software would help to increase scanning time in lieu of time spent reporting. Successful AI implementation in standardized reporting requires a globally uniform lexicon, although diversity of languages may contribute to delay of the implementation of an AI solution in a US reporting routine. The methodology of developing weighted criteria, e. g., "I-RAD" systems is the same as for deep machine learning computer systems, which are trained for medical imaging artificial intelligence [62].

The US imaging spectrum is so large that recommendation of a single common "report form" that covers all fields, is not possible. However, there are a number of mandatory rules to follow (► **Table 1**):

The text volume of a US report may range from summary notes in the patient's file, e. g., focused thoracic US: "No pleural effusion found on right side", to very extensive versions with recording of all cine-loops to be archived together with a detailed report, with all nine categories, e. g., in second-trimester obstetric US screening, the summary may be three to five pages long.

**Position Statement 8: Structured ultrasound reporting and the use of templates and text modules is recommended (17/0/0).**

## Communication of Medical US Findings

Selected relevant image material should be demonstrated, explained, and discussed with the responsible clinician(s) as in the practice with all other imaging modalities. This may happen

via an individual personal exchange between the examiner and referring clinician or in multi-disciplinary clinico-radiological meetings. To influence immediate clinical management, in cases of high clinical urgency, a verbal report highlighting the salient findings should be given directly to the responsible clinician prior to issuing a formal report or even better by the presence and involvement of the responsible clinician during the examination of the patient.

The complete digitally stored medical US image material and the report should be available for all clinicians involved in patient care. Depending on national regulations, the patient and other medical personnel may also have access to the images and the associated report of the US examination.

**Position Statement 9: The digitally stored and reported medical ultrasound data should be available for all involved parties in the patient's care and should be communicated in a timely manner (17/0/0).**

## 9. Medical Ultrasound Data Management and Archiving

DICOM (Digital Imaging and Communication in Medicine) has been established as a non-proprietary standard for the storage, communication and management of medical imaging information and related data [63, 64]. It is implemented in all modern medical US systems and, therefore, should be used for digital documentation and archiving of medical US imaging. PACS (Picture Archiving and Communication System) is the software solution that enable storages and reproduction of any kind of medical DICOM imaging material and digital reports, which should be used to archive and manage medical imaging data. Thus, US images and cine-loops are available on an equal par with image files from other imaging modalities, allowing demonstration in multidisciplinary meetings, direct comparison with findings from cross-sectional imaging, follow-up imaging, the application of image-fusion techniques, and the partial replacement of imaging involving radiation exposure. However, PACS use and implementation may be variable among countries for a number of different reasons [65].

Reluctance to archive US images digitally in an attempt to avoid the significant computer server-based expenses is not acceptable, as the cost of memory modules has reduced substantially. US practitioners from specialties other than radiology should seek advice from their local information technology units and specialists, in order to implement DICOM storage and PACS archiving in the hospital and outpatient setting as well as in private clinic settings. All US scanners should be connected to PACS, and patients preferably can be selected from a "worklist" to avoid basic data errors [66].

**Position Statement 10: Digital image archiving of ultrasound examinations is mandatory. In institutions use of the standard PACS is recommended (17/0/0).**

## 10. Quality Considerations

Patients and referring physicians should expect to receive the best achievable quality of medical US. As providers of medical US, the objective is to achieve a diagnostic reliability level comparable to the level published in guidelines and other high-quality review publications. Quality assurance reviews and maintenance of US equipment should meet the accepted original manufacturer standards.

In comparison to other imaging modalities, US is more operator-dependent. This is often perceived as a failure to examine the relevant area with the transducer or as being the result of the region being obscured, e. g., by gas or bone. US examinations can be as informative as other imaging modalities or even better and may even have the advantage of superior spatial resolution, real-time live presentation, and the ability to readily repeat the examination. It is vital that the target organ/region is stored as an image or video file, because without this, there can be no re-evaluation by a second expert. Every US practitioner must strive to achieve a level of imaging reliability similar to other imaging modalities. An attempt should be made with US to obtain images of all aspects of the target region/organ, to ensure that the examination is reliable with respect to identifying or dismissing abnormalities. Where a full examination is not possible, a thorough description of the regions/organs/aspects that were not clearly imaged or where there was limited diagnostic quality should be stated and the report should be written in a way that makes the limitations of the examination clear. This applies not only to items 6. Scanning conditions and 7. Descriptions of US appearance of organs and pathologies (▶ **Table 1**), but also in particular to item 8. Conclusion part c). The value of a summarizing statement regarding the other examined organs and regions without pathologies and therefore not mentioned in parts a) and b) of the conclusion (e. g., "The remainder of the ultrasound examination demonstrated no findings of clinical significance") must be put into perspective by an indication of any patient-specific or methodological limitations of the examination of these organs and regions.

US diagnoses in parts a) and b) of the report's conclusion should be formulated as precisely and definitively as possible, but in a patient-specific manner, with relevant differential diagnoses taken into account. To minimize loss of examiner reputation, even the most typical sonographic appearance should only be referred to as such: e. g., "typical sonographic aspect like liver metastases", not just "liver metastases".

In order to be able to obtain pooled statistical data for quality assurance of a medical institution and its qualified US practitioners (sensitivity, specificity, positive/negative predictive value, and overall accuracy of US diagnoses), it is necessary to classify the final diagnosis correctly according to the International Classification of Diseases (ICD). Currently, there are a number of medical diagnostic procedures with mandatory national quality databases, e. g., endoscopic US, and US departments can benchmark against these national standards. It is recommended to perform quality assurance as a regular activity in order to confirm the practice quality and be compared to other institutions.

## Position Statement 11: Regular critical review of medical ultrasound reports is recommended (16/0/1).

### 11. Conclusion and Future Perspectives

The practice of medical US still varies considerably in the areas of procedure, image storing, and reporting. Most practices will have some areas where they could improve. In this manuscript we have described the areas that the EFSUMB considers to be an optimum standard for all US practitioners to attain. Practitioners should also be aware of existing guidelines and position papers, to continually assess and improve their US practice.

The ability to store and share US images and videos in a standardized digital database, co-joined with a report from the operator, is crucial to improve the applicability and clinical yield of this modality, in terms of economic value, quality, and educational value. Adhering to these standards makes the US examination a more reliable, reproducible, and standardized imaging modality in line with other cross-sectional imaging methods.

With large datasets becoming available, US may benefit in the near future from deep learning artificial intelligence solutions that could help to improve implementation of unified standards and quality, thereby helping US practitioners to scan and report readily, precisely, and accurately [62].

With a standardized approach, there are also better opportunities for appropriate reimbursement and the timing of equipment update or renewal.

#### Conflict of Interest

The authors disclose reimbursement of travel expenses by EFSUMB or national scientific societies, resulting from their involvement in EFSUMB ExB or related committee activities. Further disclosures: Matthias Wuestner: Lecture fees in Ultrasound courses and congresses from Ultrasound academy of DEGUM, Campus ACADEMY, SonoABCD – UEC & Partners Medical Education GmbH, Landesärztekammer Niedersachsen, Falk Foundation, Support to perform ultrasound courses from Philips and Mindray. Vito Cantisani: Lecturer fee as speaker for Bracco, Samsung, Canon. Klaus Jenderka: shares of GAMPT mbH (Company for Applied Medical Physics and Technique). Julian Kuenzel: fees for participation in expert meetings from BMS and for performing DEGUM certified ultrasound courses by SonoForKlinik. Support to perform ultrasound courses by GE Healthcare, travelling support by Merz. Adrian Lim: Fees for lectures and articles from Canon Medical Systems, Siemens Medical Systems and Bracco. Research Grants and Support – Philips Medical Systems and Canon Medical Systems. Vladimir Mitkov: Lecture fees in Ultrasound courses, webinars and congresses from Canon Medical Systems (Japan), GE Healthcare (USA), Mindray (China), Philips. Adrian Saftoiu: Lecture fees in Ultrasound/EUS courses and congresses from Bracco Suisse and Pentax Medical Singapore. 100% shares held in EchoEndoPlus company, involved in Romania in healthcare. Christian Jenssen: fees for lectures and/or participation in expert meetings from FALK Foundation, Hitachi Medical Ultrasound, GE Healthcare, Bracco and Ultrasound Academy of DEGUM. Support to perform ultrasound courses by Canon, Hitachi, GE Healthcare and Bracco.

#### References

- [1] Education and Professional Standards Committee, European Federation of Societies for Ultrasound in Medicine and Biology. Minimum training recommendations for the practice of medical ultrasound. *Ultraschall in Med* 2006; 27 (1): 79–105
- [2] Jenssen C, Gilja OH, Serra AL et al. European Federation of Societies for Ultrasound in Medicine and Biology (EFSUMB) Policy Document Development Strategy – Clinical Practice Guidelines, Position Statements and Technological Reviews. *Ultrasound Int Open* 2019; 5 (1): E2–E10
- [3] Edwards HM, Sidhu PS. Who's doing your scan? A European perspective on ultrasound services. *Ultraschall in Med* 2017; 38 (5): 479–482
- [4] Regulation (EU) 2017/745 of the European Parliament and of the Council of 5 April 2017 on medical devices, amending Directive 2001/83/EC, Regulation (EC) No 178/2002 and Regulation (EC) No 1223/2009 and repealing Council Directives 90/385/EEC and 93/42/EEC (Consolidated version): EUR-Lex – 32017R0745 – EN – EUR-Lex (europa.eu) (accessed April 17, 2021).
- [5] Gesetz über Medizinprodukte (Medizinproduktegesetz – MPG, BGBl. I p. 1133) 7.8.2002, adopted 18.7.2017; Germany. <https://www.gesetze-im-internet.de/mpg/MPG.pdf> (accessed April 17, 2021)
- [6] Bundesgesetz betreffend Medizinprodukte (Medizinproduktegesetz – MPG, Fassung v. 12.9.2018, BGBl. No. 657/1996), Austria. RIS – Medizinproduktegesetz – Bundesrecht konsolidiert, Fassung vom 22.05.2021 (bka.gv.at) (accessed April 17, 2021).
- [7] European Commission, Single Market and Standards, Notified Bodies, Brussels. [https://ec.europa.eu/growth/singlemarket/goods/building-blocks/notified-bodies\\_en](https://ec.europa.eu/growth/singlemarket/goods/building-blocks/notified-bodies_en)
- [8] FDA. FDA Basics. <https://www.fda.gov/aboutFDA/transparency/fda-basics/> (accessed April 17, 2021)
- [9] International Electrotechnical Commission (IEC). IEC 60601-1-2. Medical electrical equipment – Part 1-2: General requirements for basic safety and essential performance – Collateral Standard: Electro-magnetic disturbances – Requirements and tests. International Standard, Geneva.
- [10] International Electrotechnical Commission (IEC). IEC 60601-2-37. Medical electrical equipment – Part 2-37: Particular requirements for the safety of ultrasonic medical diagnostic and monitoring equipment. International Standard, Geneva.
- [11] International Electrotechnical Commission (IEC). IEC/TR 80002-1:2009 Medical device software – Part 1: Guidance on the application of ISO 14971 to medical device software. Geneva.
- [12] Kollmann C, Jenderka KV, Moran C et al. EFSUMB clinical safety statement for diagnostic ultrasound – (2019 revision). *Ultraschall in Med* 2020; 41 (4): 387–389
- [13] EFSUMB – ECMUS Safety Statements. <https://www.efsumb.org/safety-statements> (accessed April 17, 2021)
- [14] Schiavone C, Grassi R, Bertolotto M et al. The sonographic medical act. *J Ultrasound* 2020; 23 (4): 445–447
- [15] Livingston CJ, Freeman RJ, Mohammad A et al. Choosing Wisely® in preventive medicine: The American College of Preventive Medicine's top 5 list of recommendations. *Am J Prev Med* 2016; 51 (1): 141–149
- [16] Dietrich CF, Westerway S, Nolsoe C et al. Commentary on the World Federation for Ultrasound in Medicine and Biology project "incidental findings". *Ultrasound Med Biol* 2020; 46 (7): 1815–1820
- [17] Hayward C. Sizing Imaging and Procedure Rooms, January 2, 2021. <https://blog.spacemed.com/sizing-imaging-and-procedure-rooms/> (accessed March 26, 2022)
- [18] Facility Guidelines Institute with assistance from the U.S. Department of Health and Human Services. 2.2-3.4.5 Ultrasound, in: 2010 Guidelines for Design and Construction of Health Care Facilities. <https://www.aapm.org/meetings/amos2/pdf/49-14367-84348-888.pdf> (accessed March 26, 2022)

- [19] EFSUMB. Best Practice recommendation for cleaning and disinfection of ultrasound transducers whilst maintaining transducer integrity. 2019. Available at (accessed April 17, 2021): [https://www.efsumb.org/wp-content/uploads/2020/12/2019-probe\\_cleaning\\_recommendation.pdf](https://www.efsumb.org/wp-content/uploads/2020/12/2019-probe_cleaning_recommendation.pdf)
- [20] Nyhsen CM, Humphreys H, Koerner RJ et al. Infection prevention and control in ultrasound – best practice recommendations from the European Society of Radiology Ultrasound Working Group. *Insights Imaging* 2017; 8 (6): 523–535
- [21] American Institute of Ultrasound in Medicine. Guidelines for Cleaning and Preparing External- and Internal-Use Ultrasound Transducers and Equipment Between Patients as well as Safe Handling and Use of Ultrasound Coupling Gel. <https://www.aium.org/officialStatements/57> (accessed April 17, 2021)
- [22] Müller T, Martiny H, Merz E et al. DEGUM recommendations on infection prevention in ultrasound and endoscopic ultrasound. *Ultraschall in Med* 2018; 39 (3): 284–303
- [23] Basseal M, Westerway SC, Juraja M et al. Guidelines for reprocessing ultrasound transducers. *Australas J Ultrasound Med* 2017; 20: 30–40
- [24] American College of Emergency Physicians. Guideline for Ultrasound Transducer Cleaning and Disinfection. *Ann Emerg Med* 2018; 72: e45–e47
- [25] Westerway SC, Basseal JM, Abramovicz JS. Medical ultrasound disinfection and hygiene practices: WFUMB global survey results. *Ultrasound Med Biol* 2019; 45: 344–352
- [26] Dietrich CF, Bamber J, Berzigotti A et al. EFSUMB Guidelines and Recommendations on the Clinical Use of Liver Ultrasound Elastography, Update 2017 (Long Version). *Ultraschall in Med* 2017; 38 (4): e16–e47
- [27] Săftoiu A, Gilja OH, Sidhu PS et al. The EFSUMB Guidelines and Recommendations for the Clinical Practice of Elastography in Non-Hepatic Applications: Update 2018. *Ultraschall in Med* 2019; 40 (4): 425–453
- [28] Sidhu PS, Cantisani V, Dietrich CF et al. The EFSUMB Guidelines and Recommendations for the Clinical Practice of Contrast-Enhanced Ultrasound (CEUS) in Non-Hepatic Applications: Update 2017 (Long Version). *Ultraschall in Med* 2018; 39 (2): e2–e44
- [29] Dietrich CF, Nolsøe CP, Barr RG et al. Guidelines and Good Clinical Practice Recommendations for Contrast Enhanced Ultrasound (CEUS) in the Liver – Update 2020 – WFUMB in Cooperation with EFSUMB, AFSUMB, AIUM, and FLAUS. *Ultraschall in Med* 2020; 41 (5): 562–585
- [30] Atkinson NSS, Bryant RV, Dong Y et al. How to perform gastrointestinal ultrasound: Anatomy and normal findings. *World J Gastroenterol* 2017; 23 (38): 6931–6941
- [31] American Institute of Ultrasound in Medicine. AIUM practice guideline for the performance of an ultrasound examination of the abdomen and/or retroperitoneum. *J Ultrasound Med* 2012; 31 (8): 1301–1312
- [32] Walas MK, Skoczylas K, Gierbliński I. Standards of the Polish Ultrasound Society – update. The liver, gallbladder and bile ducts examinations. *J Ultrason* 2012; 12 (51): 428–445
- [33] Ćwik G. Standards of the Polish Ultrasound Society – update. Pancreas examination. *J Ultrason* 2013; 13 (53): 167–177
- [34] Tyloch JF, Woźniak MM, Wieczorek AP. Standards of the Polish Ultrasound Society – update. Ultrasound examination of the kidneys, ureters and urinary bladder. *J Ultrason* 2013; 13 (54): 293–307
- [35] Laursen CB, Clive A, Halifax R et al. European Respiratory Society Statement on Thoracic Ultrasound. *Eur Respir J* 2020: 2001519
- [36] Gargani L, Volpicelli G. How I do it: lung ultrasound. *Cardiovasc Ultrasound* 2014; 12: 25
- [37] Möller I, Janta I, Backhaus M et al. The 2017 EULAR standardised procedures for ultrasound imaging in rheumatology. *Ann Rheum Dis* 2017; 76 (12): 1974–1979
- [38] Kwak JY, Han KH, Yoon JH et al. Thyroid imaging reporting and data system for US features of nodules: a step in establishing better stratification of cancer risk. *Radiology* 2011; 260 (3): 892–899
- [39] Trzebińska A, Dobruch-Sobczak K, Jakubowski W et al. Standards of the Polish Ultrasound Society – update. Ultrasound examination of thyroid gland and ultrasound-guided thyroid biopsy. *J Ultrason* 2014; 14 (56): 49–60
- [40] Mitchell C, Rahko PS, Blauwet LA et al. Guidelines for Performing a Comprehensive Transthoracic Echocardiographic Examination in Adults: Recommendations from the American Society of Echocardiography. *J Am Soc Echocardiogr* 2019; 32 (1): 1–64
- [41] Santos SND, Alcantara ML, Freire CMV et al. Vascular Ultrasound Statement from the Department of Cardiovascular Imaging of the Brazilian Society of Cardiology – 2019. *Arq Bras Cardiol* 2019; 112 (6): 809–849
- [42] Małek G, Nowicki A. Standards of the Polish Ultrasound Society – update. Sonography of the lower extremity veins. *J Ultrason* 2014; 14 (58): 287–296
- [43] Małek G, Elwertowski M, Nowicki A. Standards of the Polish Ultrasound Society – update. Ultrasound examination of the aorta and arteries of the lower extremities. *J Ultrason* 2014; 14 (57): 192–202
- [44] Elwertowski M, Małek G. Standards of the Polish Ultrasound Society – update. Examination of the extracranial carotid and vertebral arteries. *J Ultrason* 2014; 14 (57): 179–191
- [45] Millington SJ, Colvin MO, Shiloh AL et al. How I Do It: Ultrasound-Guided Internal Jugular and Femoral Central Venous Catheter Insertion. *Chest* 2020; 158 (6): 2425–2430
- [46] Troianos CA, Hartman GS, Glas KE et al. Guidelines for performing ultrasound guided vascular cannulation: recommendations of the American Society of Echocardiography and the Society of Cardiovascular Anesthesiologists. *J Am Soc Echocardiogr* 2011; 24 (12): 1291–1318
- [47] Armas RR. Qualities of a good radiology report. *Am J Roentgenol* 1998; 170 (4): 1110
- [48] Brady AP. Radiology reporting – from Hemingway to HAL? *Insights Imaging* 2018; 9 (2): 237–246
- [49] Weiss DL, Langlotz CP. Structured Reporting: Patient Care Enhancement or Productivity Nightmare? *Radiology* 2008; 249 (3): 739–747
- [50] European Society of Radiology. ESR paper on structured reporting in radiology. *Insights Imaging* 2018; 9 (1): 1–7
- [51] Kuhn K, Zemmler T, Reichert M et al. Structured data collection and knowledge-based user guidance for abdominal ultrasound reporting. *Proc Annu Symp Comput Appl Med Care* 1993: 311–315
- [52] O'Connor SD, Kulkarni NM, Griffin MO Jr et al. Structured reporting in ultrasound. *Ultrasound Q* 2020; 36 (1): 1–5
- [53] An JY, Unsdorfer KML, Weinreb JC. BI-RADS, C-RADS, CAD-RADS, LI-RADS, Lung-RADS, NI-RADS, O-RADS, PI-RADS, TI-RADS: Reporting and Data Systems. *Radiographics* 2019; 39 (5): 1435–1436
- [54] Ernst BP, Hodeib M, Strieth S et al. Structured reporting of head and neck ultrasound examinations. *BMC Med Imaging* 2015; 19: 25
- [55] Russ G, Bonnema SJ, Erdogan MF et al. European Thyroid Association Guidelines for Ultrasound Malignancy Risk Stratification of Thyroid Nodules in Adults: The EU-TIRADS. *Eur Thyroid J* 2017; 6 (5): 225–237
- [56] Chernyak V, Fowler KJ, Kamaya A et al. Liver Imaging Reporting and Data System (LI-RADS) Version 2018: Imaging of Hepatocellular Carcinoma in At-Risk Patients. *Radiology* 2018; 289 (3): 816–830
- [57] Kono Y, Lyschik A, Cosgrove D et al. Contrast Enhanced Ultrasound (CEUS) Liver Imaging Reporting and Data System (LI-RADS®): the official version by the American College of Radiology (ACR). *Ultraschall in Med* 2017; 38 (1): 85–86
- [58] Geyer T, Rübenthaler J, Marschner C et al. Structured Reporting Using CEUS LI-RADS for the Diagnosis of Hepatocellular Carcinoma (HCC)-Impact and Advantages on Report Integrity, Quality and Interdisciplinary Communication. *Cancers (Basel)* 2021; 13 (3): 534
- [59] Schwartz LH, Panicek DM, Berk AR et al. Improving communication of diagnostic radiology findings through structured reporting. *Radiology* 2011; 260 (1): 174–181

- [60] Ernst BP, Katzer F, Kunzel J et al. Impact of structured reporting on developing head and neck ultrasound skills. *BMC Med Educ* 2019; 19: 102
- [61] Ernst BP, Strieth S, Katzer F et al. The use of structured reporting of head and neck ultrasound ensures time-efficiency and report quality during residency. *Eur Arch Otorhinolaryngol* 2020; 277: 269–276
- [62] Cantisani V, Grani G, Tovoli F et al. Artificial Intelligence: What is it and how can it expand the ultrasound potential in the future? *Ultraschall in Med* 2020; 41 (4): 356–360
- [63] Bidgood WD Jr, Horii SC, Prior FW et al. Understanding and using DICOM, the data interchange standard for biomedical imaging. *J Am Med Inform Assoc* 1997; 4 (3): 199–212
- [64] Graham RN, Perriss RW, Scarsbrook AF. DICOM demystified: a review of digital file formats and their use in radiological practice. *Clin Radiol* 2005; 60 (11): 1133–1140
- [65] Foord K. Year 2000: status of picture archiving and digital imaging in European hospitals. *Eur Radiol* 2001; 11 (3): 513–524
- [66] Busch HP (Ed.). *Management-Handbuch für Radiologen* (German). Stuttgart: Thieme; 2008