

THE EFFECTIVENESS OF ELECTRO-ACUPUNCTURE IN OVARIAN ISCHEMIA REPERFUSION INJURY

1 Seda Keskin, **Ass.Prof.** Ordu University, Faculty of Medicine, Department of Obstetrics and Gynecology; Ordu, 52200, Turkey; Cumhuriyet Ave., Mustafa Kemal Blvd., No:478, 52200 Altınordu/Ordu/ Turkey; Tel number: +905056273412; Fax number: +904522265228 adesniksek@gmail.com , **Correspondence**

2. Deha Denizhan Keskin; **Ass.Prof.** Ordu University, Faculty of Medicine, Department of Obstetrics and Gynecology; Ordu, 52200, Turkey dehadenizhankeskin@gmail.com

3. Muhammet Değermenci; **Ass.Prof;** Ordu University , Faculty of Medicine, Department of Anatomy; Ordu, 52200, Turkey ; mdegermenci@yahoo.com.tr

4. Hatice Hancı; **Ass.Prof.;** Ordu University, Faculty of Medicine, Department of Embryology and Histology; Ordu, 52200, Turkey; haticehancii@gmail.com

5. Nuket Göçmen Karabekir; **Professor;** Dokuz Eylül University; Faculty of Medicine, Department of Anatomy; İzmir, 35000, Turkey; nuketmas@gmail.com

6. Mehtap Atak; **Ass.Prof.;** Recep Tayyip Erdoğan University, Faculty of Medicine, Department of Medical Biochemistry; Rize, 53950, Turkey; mehtap.atak@erdogan.edu.tr

7. Orhan Baş; **Professor;** Ordu University, Faculty of Medicine, Department of Anatomy; Ordu, 52200, Turkey; orhanbas55@hotmail.com

(Date of manuscript received: 21.04.2021) (Date of acceptance: 21.07.2021)

Abstract

Electro-acupuncture is widely used in gynecology. Adnexal torsion is an important threat to ovarian reserves in women of reproductive age. This is the first study to investigate whether electro-acupuncture is beneficial in protecting ovarian reserves in case of adnexal torsion resulting in reperfusion injury. Thirty-two female Wistar Albino rats were randomized into four groups: the first group—sham operation, the second group—torsion/detorsion model, the third group—pre-acupuncture + torsion/detorsion + post-acupuncture, and the fourth group—torsion/detorsion + post-acupuncture. The acupoints used were CV4 and bilateral SP6 Ex-CA1, Kid3, and ST36. In the third group, the acupoints were needled for two weeks before torsion, continuing for a further two weeks after torsion. In the fourth group, needling began after torsion and was maintained for two weeks. Both histological and biochemical parameters indicating ovarian reserves showed that electro-acupuncture applied to the above points exhibited an ameliorating effect on ovaries injured during ischemia/reperfusion. Electro-acupuncture may be capable of protecting against and preventing ischemia/reperfusion injury in case of ovarian torsion.

Keywords: Ovarian torsion; Ovarian ischemia/reperfusion injury; Electro-acupuncture; AMH; Ovarian reserve; Complementary and traditional medicine

1. Introduction

Ovarian torsion is an important emergency in the second to fourth decades of women's reproductive lives. The condition occurs in approximately 3% of all gynecological emergency conditions [1]. Ovarian torsion refers to twisting of the ovary. Venous return is first interrupted, followed by tissue edema and internal hemorrhage. If the torsion continues, the arterial supply to the ovary also ceases, leading to tissue necrosis and follicular depletion [2]. In previous decades, the recognized therapeutic option in case of a necrotic and swollen ovary was salpingo-oophorectomy. However, in the last two decades, it has been recognized that follicles can be preserved even in swollen and purple-blue necrotic ovaries. Conservative management with detorsion is therefore recommended [3]. After the entry into use of detorsion therapy for adnexal torsion, the question of reperfusion ischemic injury came to prominence. Tissue oxidative products accumulate in the interval between torsion and detorsion and damage the ovarian tissue following reperfusion [4]. Consequently, researchers have started to explore various agents, plant extracts, or methods for reversing such reperfusion ovarian injury without resulting in ovarian follicular depletion.

In gynecology practice, acupuncture has been investigated in a number of clinical randomized studies, for the purpose of increasing retrieved oocytes in assisted reproduction, for improving pregnancy rates and live birth rates in IVF cycles [5], for thickening the endometrium [6], for enhancing diminished ovarian reserve (DOR) [7], and for improving fertility in polycystic ovary syndrome (PCOS) [8]. Previous research has reported that acupuncture lowered follicle-stimulating hormone (FSH) and luteinizing hormone (LH) levels, and increased serum levels of anti-Müllerian hormone (AMH) and estradiol (E2) in patients with DOR [9]. Previous studies have shown that electro-acupuncture (EA) regulates ovarian blood flow in rats, as well as modulating uterine artery blood flow in humans [10]. Furthermore, in terms of reproductive organ blood supply, the efficacy of abdominal acupuncture in increasing human testicular blood flow has also been investigated. Increased testicular blood flow was observed when the acupoint Gulai (S-29) was stimulated at a 10 Hz frequency [11]. In addition to the reproductive system, EA has also been shown to exhibit ameliorating effects on oxidative stress in the liver [12], spinal cord [13], and also EA is studied in diabetic rats [14] and even in obesity there have been shown ameliorating effects [15]. An experimental study of testicular torsion/detorsion also reported amelioration of oxidative stress following bilateral stimulation of acupoint S-29 in male rats [16].

Numerous studies have investigated the efficacy of acupuncture or EA in female reproductive system diseases such as PCOS, premature ovarian failure (POF), and DOR. However, this is the first study to investigate the efficacy of EA in ovarian reperfusion injuries in rats.

2. Materials and methods

2.1. Animals:

Thirty-two female Wistar Albino rats, aged eight weeks and weighing 180-250 g, were purchased from the Samsun 19 Mayıs University Experimental Animal Science Department, Turkey. Wistar Albino rats have generally been used for experimental studies of the female reproductive system, and rat acupuncture mapping is more practical than using mice. The local Ordu University Animal Ethics Committee approved the experimental stages (Date of approval: 12/09/2019; Approval number 82678388/07).

Rats were housed in a controlled manner (12 h light/12 h dark, 22⁰C, 55-65% humidity, with free access to nutrient sand food), in plastic cages containing four animals each. During the first week, following the purchase and transfer of rats from the Samsun 19 Mayıs University Animal Science Department to the Ordu University Animal Science Laboratory where the experiments would be conducted, the rats were left to acclimatize to their new conditions and housing. After the adaptation week, all rats were immobilized in a special setup for adaptation to EA application, for 20 min a day, thus mimicking the experiment. The setup consisted of a handmade wood plate with attachment sites for cords in all four corners. Rats were held down and tied using smooth, non-traumatic cords from all four distal extremities, the ventral region facing the investigator.

Electro-acupuncture stimulations were conducted with a professional six-ducted EA stimulation and transcutaneous electrical nerve stimulation devices (Product code: AKU130, China). Stainless steel needles 0.20*13 mm in size were applied to the acupoints at depths of 5-8mm. The needles were then linked to a device emitting a continuous wave frequency of 2 Hz and 2 mA current producing vibration around the acupuncture area. EA stimulations (displayed in Figure 1.) on the bilateral Sanyinjiao (SP6), Zusanli (ST36), Taixi (Ki3), Zigong (ExCA-1) points and the Guanyuan (CV4) point were conducted at fixed time points for each group of rats (16.00 p.m. - 19.00 p.m.), 20 min for each rat, in line with previous acupuncture studies [17,18].

Animals were randomized into four groups of eight animals each, using a computer-based random order generator. The first group (n=8, sham operation group) was the sham operation group in which a midline incision below the umbilicus was made, the internal organs were manipulated, and the incision was then closed after 3 h, similarly to the other ovarian torsion groups. The second group (n=8, torsion/detorsion model) underwent ovarian torsion/detorsion with sham acupoint needling. The first sham acupoint was on the inner face of the leg, four body units down to the popliteal fold, the second on the posterior of the leg, six body units down to the popliteal fold and one body unit lateral to the midline, and the third was located one body unit laterally to the anterior midline, and one body unit above the umbilicus, in agreement with previous study reports [19,20]. These acupoints were stimulated for the same duration (20 minutes) as the original acupoints used in those studies. The third group (n=8, pre-acupuncture treatment + torsion/detorsion + post-acupuncture) received pretreatment with EA. At the end of the adaptation week, EA was initiated with the CV4 and bilateral SP6, Ex-CA1, Kid3, and ST36 acupoints. Application was performed from Monday to Friday, between 16.00 p.m. and 19.00 p.m., for two weeks, over a total of 10 sessions. The ovarian torsion/detorsion model was then applied, and EA was administered for a further two weeks using the same acupoints as described above. The fourth group (n=8, torsion/detorsion+post acupuncture) was the post-EA treatment group. One day after torsion-detorsion, EA was applied from Monday to Friday, for two weeks, between 16.00 p.m. and 19.00 p.m. at the same acupoints as described above.

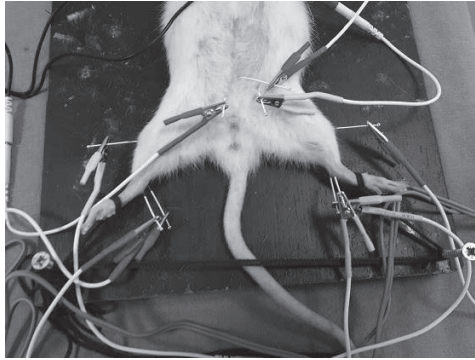


Figure 1. Ex-CA1: Supine position; 3 cun lateral to and 1 cun above the upper margin of the pubic bone. Ki-3: On the inner aspect of the foot, posterior to the medial malleolus, in the excavation between the medial malleolus and tendo calcaneus. CV4: The lower 1/5 of an imaginary line between the xiphoid and pubic symphysis. SP6: Approximately 1 cm above the top of the medial malleolus and anterior to the rear border of the tibia. ST36: Directly below the capitulum fibulae on the posterior side of the knee joint, the needle being inserted at a depth of 5-7 mm.

2.2. Ovarian Ischemia–Reperfusion Modelling (torsion/detorsion):

Rats were food-deprived for 16 h before surgery, but were allowed access to water. A mixture of 40 mg/kg ketamine (Ketalar, Eczacıbaşı, Turkey) and 10 mg/kg xylazine hydrochloride (Alfazyne, Alfasan, Holland) was employed for general anesthesia. Ophthalmic ointment was used to prevent corneal drying. Depth of anesthesia was evaluated every 5 min based on various reflexes (corneal touch and pedal flexion). Intra cardiac blood sampling was first performed for the investigation of hormone profiles. After removing the bristles on the lower abdomen and cleaning with povidone-iodine, a 1.5-2 cm midline and vertical incision was made to the lower abdomen in order to explore the ovaries and uterine horns. In the sham operation group, the incision was closed following manipulation and observation of uterine horns and ovaries. In the other three groups, ischemia was induced for 3 h with the application of atraumatic clips to the vascular pedicle 1 cm superior and inferior to the right ovary. Following 3-h ischemia, the abdomen was opened. The presence of swollen and dark purple ovaries (Figure 2) was regarded as successful application of the ischemia model, and detorsion was then performed. The abdominal incisions were closed with 3-0 vicryl sutures (polyglactin 910, Ethicon, NJ, USA). Daily wound care was applied on the following days. At the end of the acupuncture treatments, the rats were anesthetized, and oophorectomy was carried out for histological sampling after intra cardiac blood collection. Finally, the rats were sacrificed via cervical dislocation under painless anesthesia. Blood and tissue samples were stored at -80°C in a deep freeze until analysis.

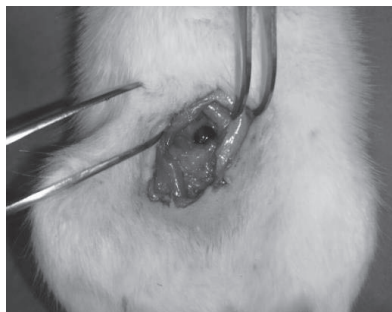


Figure 2. Successful Torsion Injury

2.3. Histopathological evaluations:

Ovarian tissues were fixed in 10% formalin for light microscopy, passed through consecutive 70%, 90%, 96%, and 100% alcohol series, cleared with xylene, and embedded in paraffin. Tissue sections 5 μm in thickness were next cut from the paraffin blocks using a semi-automatic microtome (DiaPath Galileo Semi-Automatic Microtome, Italy) and stained with hematoxylin and eosin. All sections were photographed with an Olympus DP26 digital camera (Olympus, Tokyo, Japan) attached to an Olympus BX53F microscope (Tokyo, Japan). All preparations were photographed with CellSens imaging software (Olympus, Tokyo, Japan) and transferred to a digital medium. Histopathological evaluation was performed by a histology specialist blinded to the study groups.

2.4. Biochemical evaluations; Hormone Assay:

Intra cardiac blood samples were first collected immediately prior to the torsion/ detorsion operation, and again after the last day of EA. These samples were centrifuged at $1000 \times g$ for 20 min at 4°C . The resulting supernatants were aliquoted and stored at -80°C until the day of investigation. Serum follicular stimulating hormone (FSH, E-EL-R0391, 96 well, Elabscience, USA), serum luteinizing hormone (LH, E-EL-R0026; 96 well; Elabscience, USA), serum estradiol (E-EL-0152; 96 well; Elabscience, USA), and serum AMH (E-EL-R3022; 96 well; Elabscience, USA) were estimated in rat serum using sandwich enzyme-linked immunosorbent assay (ELISA) kits with the non-competitive sandwich ELISA method. The FSH assay measured concentrations in a detection range of 3.13-200 ng/mL. The sensitivity of the test was 1.88 ng/mL, and intra- and inter-coefficients of variation were $<10\%$. The LH assay measured concentrations in a detection range of 1.56-100 mIU/mL. The sensitivity of the test was 0.94 mIU/mL, and intra- and inter-coefficients of variation were $<10\%$. The estradiol assay measured concentrations in a detection range of 1.56-100 pg/mL. The sensitivity of the test was 1.00 pg/mL, and intra- and inter-coefficients of variations were $<10\%$. The AMH assay measured concentrations in a detection range of 62.50-4000 pg/mL. The sensitivity of the test was 37.50 pg/mL, and intra- and inter-coefficients of variation were $<10\%$. Optical density (OD) was measured spectrophotometrically at a wave length of $450 \text{ nm} \pm 2 \text{ nm}$. OD values reflected the concentrations of rat FSH, LH, estradiol, and AMH.

2.5. Statistical Analysis:

All values were represented as mean \pm standard deviation. Differences were considered significant at $p < 0.05$. SPSS Version 26 software was used for statistical analysis.

Biochemical variables were analyzed made using One-Way ANOVA and Tukey's post hoc honest significant difference test. The Shapiro-Wilk test was applied to detect the normality of distribution of variables. Levene's test was used to assess the homogeneity of the group variances. Multi-group comparisons of nonparametric variables were performed using the Kruskal-Wallis test.

3. Results

3.1. Biochemical Results:

The groups' hormone assay results are shown in Table 1. Due to the significant quantities of comparable data elicited, only statistically significant data are shown in the table as upper-case letters. Elevation in FSH and LH hormone levels was observed after two weeks in the torsion/detorsion group compared to the sham operation group, while AMH and estradiol levels had decreased. FSH hormone levels were significantly higher in the torsion model group than in the other three groups. FSH levels were lower in both acupuncture groups (group 3 and 4) than in the torsion/detorsion model group (shown as ^{p,q,r} in the table, $p=0.000$). LH hormone levels also increased in the torsion/detorsion model group (^b $p=0.002$). The increase in the torsion/detorsion+ post-acupuncture group (group 4) was also statistically significant (^c $p=0.02$). Estradiol levels decreased in the torsion/detorsion-model group, the pre-acupuncture + torsion/detorsion + post-acupuncture group, and the torsion/detorsion + post-acupuncture group (^d $p=0.003$, ^e $p=0.03$, and ^f $p=0.047$, respectively). However, while a significant difference was observed between the sham operation and torsion/detorsion-model groups, there were no differences between the sham group and either of the acupuncture groups. Estradiol levels in both acupuncture groups decreased after 15 days of torsion injury, but no significant difference was observed with the sham group. Finally, AMH levels decreased significantly in the torsion/detorsion model group after 15 days of torsion injury (^j $p=0.000$), and significant differences were determined between both acupuncture groups and the torsion/detorsion-model group (^m $p=0.000$, and ⁿ $p=0.000$). In terms of AMH, a significant difference was observed between the torsion/detorsion model group and third group (torsion/detorsion + post-acupuncture group) (^k $p=0.004$), but no significant difference was determined compared with the pre-acupuncture + torsion/detorsion + post-acupuncture group.

3.1. Histological Results:

All rats were subjected to histological evaluation to detect differences in tissue edema, follicular growth, and atretic follicles between the groups and represented in Figure 3. In the sham group, the ovaries exhibited no macroscopic or microscopic pathological changes. Follicles at different stages of maturation (primordial, primary, secondary, tertiary follicles and corpus luteum) were observed inside the normal ovarian stroma. In the torsion/detorsion group, the majority of follicles had become atretic, exhibiting intense vacuolization and edema, hemorrhagic areas, and cystic-degenerated follicles. In the pre-acupuncture + torsion/detorsion + post-acupuncture group, the ovaries were very similar in appearance to those of the control group, exhibiting anormal structure and developing follicles inside the stroma. In the torsion/detorsion + post-acupuncture groups, occasional atretic follicles were observed, but the normal follicle structure was largely preserved.

Table 1. Hormone assay results

	FSH(1) (ng/mL)	FSH(2) (ng/mL)	LH (1) (mIU/mL)	LH (2) (mIU/mL)	E2(1) (pg/mL)	E2(2) (pg/mL)	AMH (1) (pg/mL)	AMH (2) (pg/mL)
Sham (n=8)	161.8 ±3.9	167.6± 6.2 ^p	75.0 ±11.2	67.8 ±7.5	33.8± 4.9	36.8± 7.4 ^h	3623.6± 370.5	3571.5± 467.7 ^k
Torsion/detorsion Model(n=8)	172.2± 5.1 ^a	195.0 ± 4.6 ^{a,p,q,r}	72.0 ± 5.7 ^b	89.5 ± 5.9 ^b	35.8± 4.7 ^d	15.5± 1.8 ^{d,g,h}	3223± 486 ^j	1721± 280.8 ^{l,m,n}
Preacupuncture+ Torsion/detorsion + postacupuncture (n=8)	169.0± 8.1	170.5 ± 4.9 ^f	71.7 ± 8.5	76.1 ± 3.7	46.7± 10.9 ^e	33.0 ± 3.3 ^{e,g}	3489.1± 424	3092± 250.3 ^m
Torsion/detorsion + Postacupuncture (n=8)	170.2± 8.5	174.1 ± 7.3 ^a	66.2 ± 6.1 ^c	79.6 ± 3.3 ^c	38.8± 9.0 ^f	30.1 ±2.6 ^f	3317.7± 397	2718± 291.9 ^{k,n}

^ap=0.000, ^bp=0.002, ^cp=0.02, ^dp=0.003, ^ep=0.03, ^fp=0.047, ^gp= 0.008, ^hp= 0.002, ⁱp=0.000, ^kp= 0.004, ^mp=0.000, ⁿp= 0.000, ^pp=0.000, ^qp=0.000, ^rp=0.000

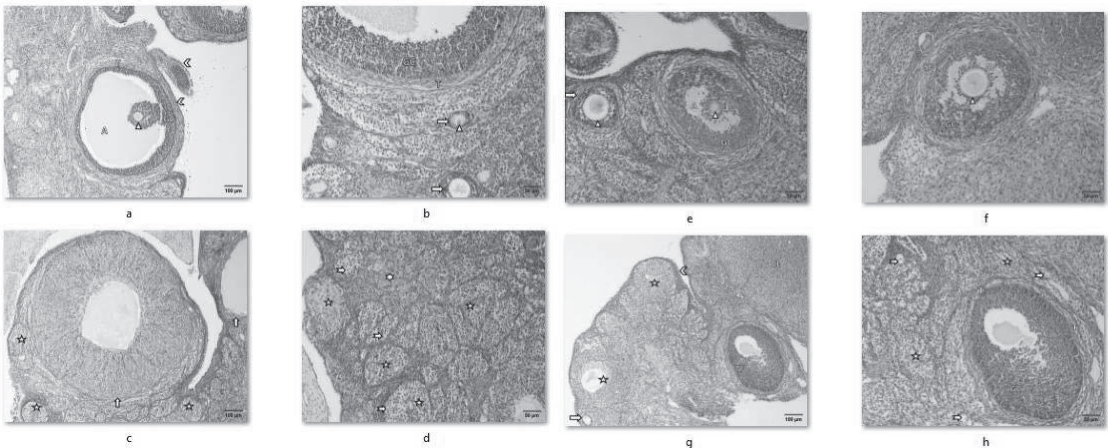


Figure 3. Histopathological results. (a) **Sham group (K-10x):** Germinative epithelium (chevrons), Tertiary follicles (TF); Theca layer (T), Granulosa cells (GC), Antrum (A), Oosit (arrowhead), H&E; x100. (b) **Sham group(K-20x):** Theca layer(T), granulosa cells (GC), Antrum (A), Primary follicle (right arrow), oocyte (arrowhead), H&E; x200. (c) **Torsion/detorsion-Model (T-10x):** Atretic follicle (star), Cystic follicle (up arrow), H&E; x100. (d) **Torsion/detorsion-Model (T-20x):** Atretic follicle (star), Vacuolisation (Rightwards Arrow with Notched Tail), edema and haemorrhagic area (6-pointed star), H&E; x200. (e) **Pre-acupuncture + Torsion/detorsion + Post-acupuncture(PA-20x-1):** Tertiary follicles (TF); Theca layer (T), Granulosa cells (GC), Antrum (A), oocyte (arrowhead), Primary follicle (right arrow) H&E; x200. (f) **Pre-acupuncture + Torsion/detorsion + Post-acupuncture(PA-20x-1):** Secondary follicles (SF); Theca layer (T), Granulosa cells (GC), antral vesicles (AV), oocyte (arrowhead), H&E; x200. (g) **Torsion/detorsion + Post-acupuncture(T-A-10x):** Germinative epithelium (chevrons), Corpus luteum (CL), Tertiary follicles (TF), Primary follicle (right arrow), Atretic follicle (star), H&E; x100. (h) **Torsion/detorsion + Post-acupuncture(T-A-20x):** Tertiary follicles (TF); Theca layer (T), Granulosa cells (GC), Atretic follicle (star), Vacuolisation (Rightwards Arrow with Notched Tail), H&E; x200.

Delivered by Ingenta

IP: 79.123.161.141 On: Sun, 16 Oct 2022 17:15:19

4. Discussion

In case of ovarian torsion, the reperfusion state in which accumulated ROS attack the ovarium following detorsion surgery is particularly responsible for follicular apoptosis [21]. Numerous pharmaceutical agents have been investigated for the purpose of reducing inflammation, protecting the follicles from apoptosis, and enhancing the antioxidant capacity of the ovary [22]. The anti-apoptotic and anti-inflammatory effects of EA have been studied under various conditions. EA has been shown to reduce the infarct area and nerve cell apoptosis in cerebral ischemia [23]. The cardio-protective effect of EA has also been studied in a rat model of myocardial injury, and the mechanisms, such as regulation of mitochondrial autophagy and inhibition of NLRP3 inflammasome activation have also been investigated [24]. EA pre-treatment has been shown to inhibit apoptosis by the mitochondrial dependent pathway in a rat cervical disc degradation model [25].

The reproductive organs display a high degree of vascularization, that blood supply being highly important for ovulation in both humans and animals [26]. Studies investigating the effect of EA on ovarian blood flow in animals have shown that low frequency EA at intensities of both 3 mA and 6 mA increased ovarian blood flow through mediation via the sympathetic nerves, and that maintenance of high OBF is necessary for ovulation. EA reduces sympathetic ovarian activity by modulating sensory, motor and autonomic outflow at the segmental level [27].

EA points in this study were selected in accordance with previous studies. Ovarian torsion is capable of progressing to POF (Premature Ovarian Failure), but neither POF nor ovarian torsion have been described in acupuncture medicine. The acupoints selected in the present study were therefore generally those used in the treatment of amenorrhea and infertility, for increasing ovarian and endometrial blood flow, and for improving follicular growth. TCM explains these diseases or disturbances in terms of insufficient transformation of blood of the spleen and stomach, and consumption of yin blood, the main deficiency observed being kidney deficiency and dysfunction. CV4 (Guan Yuan) is described as the site where yin and yang meet, while ST36 (Zusanli) warms the spleen and stomach, and provides Qi and blood nourishment. SP6 (Sanyinjiao) is an acupoint frequently used in female disorders and that harmonizes liver functions and nourishes renal Qi. A combination of acupoints CV4, ST36, SP6 and KI3 was used to study POF in a previous human study, the authors reporting decreases in FSH and LH hormones and increases in estradiol hormones. Similar biochemical results were observed in the present study, AMH and estradiol hormones decreasing significantly in the torsion/detorsion-model group, while the decreases in the both acupuncture groups (group 3 and 4) were not significant [28,29,30].

The present study, the first of its kind in the literature, was intended to investigate the protective effect of EA in a rat model of ovarian ischemia-reperfusion injury resulting in decreased ovarian reserves. The results suggest that the acupuncture points studied may be effective in ameliorating the histological and biochemical effects of ischemia on the ovary in terms of ovarian reserve markers. While AMH and estradiol decreased significantly in the torsion/detorsion model group, the decreases in the both acupuncture groups (group 3 and 4) were not statistically significant. Only a slight difference was observed between the sham operation group and torsion/detorsion + post-acupuncture groups in terms of AMH. FSH levels increased in both acupuncture groups, but not statistically significantly compared with the sham group. The number of experimental studies investigating the effects of reperfusion injury on ovarian reserve markers to date is limited. One study investigated N-acetylcysteine (NAC) and enoxaparin in terms of ovarian reserve marker preservation after torsion and detorsion injury. The authors reported higher AMH values in the NAC administration group compared with the enoxaparin and control groups [31]. Moreover, histologically similar

results to those in the sham group were observed in the preacupuncture + torsion/detorsion + postacupuncture group. Follicular structure was protected, and no atretic follicles were observed in the third group. Occasional atretic follicles were observed in the post-acupuncture group (group 4), but no edema, hemorrhage, cystic degradation or vacuolization comparable to those detected in the torsion/detorsion-model group occurred.

In addition to the ameliorating effects of EA on ischemic liver, brain, and heart injuries, its effects on torsion-ischemia have also studied in a testicular torsion model. In that study, the researchers investigated the blood flow modulation effect in twisted arteries using 3D ultrasound imaging and observed significant improvement in bilateral testicular blood flow following electrical stimulation [32]. The modulation of blood flow to the pelvic and genital organs by EA in various conditions has been investigated in both human and animal studies [33,34]. Both histological and ovarian reserve marker results were satisfactory in both the pre-acupuncture (group3) and post-acupuncture (group4) groups compared to the torsion/detorsion -model group in terms of follicular reserve protection. AMH and estradiol levels decreased, albeit not statistically significantly, compared to the sham group.

There are a number of limitations to the present study. First, only a limited number of animals was approved by the animal ethics committee for comparing the effectiveness of different acupoints. Second, financial constraints meant that it was not possible to investigate apoptosis markers. We believe that studying oxidative stress parameters, which are already investigated in such research, is an inefficient use of resources, since the main aim in case of torsion is to prevent apoptosis as a result of accumulating oxidative stress. Another concern, in addition to apoptosis, is the level to which ovarian reserve markers are affected. Despite the limitations described above, this study reveals the preventive and complementary effects of acupuncture on ovarian reperfusion damage.

In contrast to other ischemia-reperfusion studies investigating the effects various pharmaceutical agents for only a limited period, the present study continued for two weeks after torsion-detorsion in order to observe the effect of injury on ovarian reserve markers. Since the rat estrous cycles lasts approximately 4-5 days, a period of two weeks corresponds to 3-4 menstrual cycles. In future studies we intend to reduce the number of acupoints in one group and to identify the most efficacious points by comparing their effects. We are also considering investigating which signaling pathways or molecular basis may provide ovarian protection by preventing apoptosis in case of ovarian torsion.

5. Conclusions

In conclusion, the answer to the main question of the present study, whether EA, which has previously been investigated in various gynecological diseases, is also effective in ameliorating ovarian ischemia-reperfusion injury is 'possibly'. Further clinical studies involving human participants are now needed in order increase our knowledge of evidence-based acupuncture protocols for treating ovarian ischemic injury.

6. Acknowledgments: We thank to Associated Professor Dr. Ülkü Karaman for extending her technical support and laboratory materials. There exists no source of funding.

7. Conflicts of Interest: The authors declare no conflict of interest.

8. Abbreviations: IVF (In Vitro Fertilisation), DOR (Diminished Ovarian Reserve), PCOS (Polycystic Ovarian Reserve), AMH (Anti Mullerian Hormone) ,FSH (Follicular Stimulating Hormone) ,LH (Luteinising Hormone) ,E (Estradiol), OBF (Ovarian Blood Flow) ,TCM (Traitional Chinese Medicine) ,NAC (N-acetyl Cysteine) ,GSH (Glutation) ,MPO(Myeloperoxidase) ,ELISA(Enzyme-linked Immunosorbent Assay), EA (Electro-Acupuncture)

9. Ethics approval: The study was conducted according to the Guiding Principles in the Care and Use of Animals, and approved by The local Ordu University Animal Ethics Committee (Date of approval: 12/09/2019; Approval number 82678388/07).

References:

1. Becker JH, de Graaff J, Vos MC. Torsion of the ovary: a known but frequently missed diagnosis. European Journal of Emergency Medicine.2009 Jun;16(3):124-6. doi: [10.1097/MEJ.0b013e32831cbaf8](https://doi.org/10.1097/MEJ.0b013e32831cbaf8). Erratum in: Eur J Emerg Med. 2014 Jun;21(3):243. Vos, Caroline M [corrected to Vos, M Caroline]. PMID: 19262396.
2. McWilliams GD, Hill MJ, Dietrich CS 3rd (2008) Gynecologic emergencies. Surgical Clinics of North America 88(2):265–283, vi. <https://doi.org/10.1016/j.suc.2007.12.0074-1>
3. Huchon C, Fauconnier A. Adnexal torsion: a literature review. European Journal of Obstetrics & Gynecology and Reproductive Biology. 2010 May;150(1):8-12. doi: [10.1016/j.ejogrb.2010.02.006](https://doi.org/10.1016/j.ejogrb.2010.02.006). Epub 2010 Feb 26. PMID: 20189289.
4. Ingeç M, Isaoglu U, Yilmaz M, Calik M, Polat B, Alp HH, Kurt A, Gundogdu C, Suleyman H. Prevention of ischemia-reperfusion injury in rat ovarian tissue with the on-off method. Journal of Physiology and Pharmacology. 2011 Oct;62(5):575-82. PMID: 22204806.
5. Xie ZY, Peng ZH, Yao B, Chen L, Mu YY, Cheng J, Li Q, Luo X, Yang PY, Xia YB. The effects of acupuncture on pregnancy outcomes of in vitro fertilization: a systematic review and meta-analysis. BMC Complementary and Alternative Medicine. 2019 Jun 14;19(1):131. doi: [10.1186/s12906-019-2523-7](https://doi.org/10.1186/s12906-019-2523-7). PMID: 31200701; PMCID: PMC6570865.
6. Li, F., Lu, H., Wang, X., Zhang, Q., Liu, Q., & Wang, T. (2021). Effectiveness of electroacupuncture for thin endometrium in infertile women: study protocol for a single-blind, randomized controlled trial. Trials. 22(1), 73. <https://doi.org/10.1186/s13063-021-05029-7>
7. Xu, H., Zheng, C., He, L., Su, T., Wang, H., Li, Y., Zhao, C., Zhang, C., Bai, Y., Tong, G., Chen, L., Zhao, F., Yang, H., Hao, M., Yin, Y., Yang, L., Fang, Y., & Liu, B. (2020). Effect of acupuncture on women with poor ovarian response: a study protocol for a multicenter randomized controlled trial. Trials. 21(1), 775. <https://doi.org/10.1186/s13063-020-04690-8>
8. Johansson J, Redman L, Veldhuis PP, Sazonova A, Labrie F, Holm G, Johansson G, Stener-Victorin E. Acupuncture for ovulation induction in polycystic ovary syndrome: a randomized controlled trial. American Journal of Physiology Endocrinology Metabolism. 2013 May 1;304(9): E934-43. doi: [10.1152/ajpendo.00039.2013](https://doi.org/10.1152/ajpendo.00039.2013). Epub 2013 Mar 12. PMID: 23482444; PMCID: PMC4116535.
9. Zhou L, Xia Y, Ma X, Tang L, Lu J, Tang Q, Wang Y. Effects of "menstrual cycle-based acupuncture therapy" on IVF-ET in patients with decline in ovarian reserve. Zhongguo Zhen Jiu. 2016 Jan;36(1):25-8. Chinese. PMID: 26946729.
10. Stener-Victorin E, Fujisawa S, Kurosawa M. Ovarian blood flow responses to electroacupuncture stimulation depend on estrous cycle and on site and frequency of stimulation in anesthetized rats. Journal of Applied Physiology (1985). 2006 Jul;101(1):84-91. doi: [10.1152/jappphysiol.01593.2005](https://doi.org/10.1152/jappphysiol.01593.2005). Epub 2006 Mar 2. PMID: 16514000.
11. Cakmak YO, Akpınar IN, Ekinci G, Bekiroglu N. Point- and frequency-specific response of the testicular artery to abdominal electroacupuncture in humans. Fertil Steril. 2008 Nov;90(5):1732-8. doi: [10.1016/j.fertnstert.2007.08.013](https://doi.org/10.1016/j.fertnstert.2007.08.013). Epub 2008 Feb 20. PMID: 18076881.

Delivered by Ingenta

IP: 79.123.161.141 On: Sun, 16 Oct 2022 17:15:19

12. Silva AH, Figueiredo LM, Dias PA, Prado Neto AX, Vasconcelos PR, Guimarães SB. Electroacupuncture attenuates liver and kidney oxidative stress in anesthetized rats. Acta Cirurgica Brasileria. 2011;26 Suppl 1:60-5. doi.org/10.1590/S0102-86502011000700013. PMID: 21971660.
13. Wu Y, Sun Z, Li Z, Zhao Y, Sun S. Effect of acupuncture on free radicals in rats with early experimental spinal cord injury. Journal of Traditional Chinese Medicine. 2002 Mar; 22(1):51-4. PMID: 11977524.
14. Ebrahimi B, Forouzanfar F, Azizi H, Khoshdel-Sarkarizi H, Sadeghnia H; Rajabzadeh A. Effect of Electroacupuncture and Glibenclamide on Blood Glucose Level and Oxidative Stress Parameters in Streptozotocin-Induced Diabetic Rats and Possible Human Implications. Acupuncture & Electro-Therapeutics Research, Volume 44, Numbers3-4, 2020, pp. 213-228(16) DOI: <https://doi.org/10.3727/036012920X15779969212955>
15. Ercan Z, Deniz G; Caf F; Algul S; Gazioglu A; Kavakli A. The beneficial effect of electro acupuncture on obesity may be associated with irisin, nesfatin-1 and preptin levels. Acupuncture & Electro-Therapeutics Research, Volume 44, Number 2, 2019, pp. 105-118(14) DOI: <https://doi.org/10.3727/036012919X15650315071924>
16. Acioli PC, Albuquerque Ade O, Guimarães IB, Araujo RW, Vasconcelos PR, Guimarães SB. Protective effects of abdominal electroacupuncture on oxidative stress and inflammation due to testis torsion/detorsion in rats. Acta Cirurgica Brasileria. 2014 Jul;29(7):450-6. doi: 10.1590/s0102-86502014000700007. PMID: 25054876.
17. Kwon YB, Lee JD, Lee HJ, Han HJ, Mar WC, Kang SK, Beitz AJ, Lee JH. Bee venom injection into an acupuncture point reduces arthritis associated edema and nociceptive responses. Pain. 2001 Feb 15;90(3):271-280. doi: 10.1016/S0304-3959(00)00412-7. PMID: 11207399.
18. Cui L, Ding Y, Feng Y, Chen S, Xu Y, Li M, Hu M, Qiu Z, Ding M. MiRNAs are involved in chronic electroacupuncture tolerance in the rat hypothalamus. Molecular Neurobiology. 2017 Mar;54(2):1429-1439. doi: 10.1007/s12035-016-9759-8. Epub 2016 Feb 4. PMID: 26846282.
19. Zaslowski C, Rogers C, Garvey M, Ryan D, Yang CX, Zhang SP. Strategies to maintain the credibility of sham acupuncture used as a control treatment in clinical trials. Journal of Alternative and Complementary Medicine. 1997 Fall;3(3):257-66. doi: 10.1089/acm.1997.3.257. PMID: 9430329.
20. Yu JB, Dong SA, Gong LR, Wang M, Mu R, Li C, Zhang Y, Li ZD. Effect of electroacupuncture at Zusanli (ST36) and Sanyinjiao (SP6) acupoints on adrenocortical function in etomidate anesthesia patients. Medical Science Monitor. 2014 Mar 12; 20:406-12. doi: 10.12659/MSM.890111. PMID: 24621826; PMCID: PMC3958570.
21. Li C Jackson RM. Reactive species mechanisms of cellular hypoxia-reoxygenation injury. American Journal of Physiology Cell Physiology. 2002;282:C227-C241.
22. Melekoglu R, Ciftci O, Eraslan S, Alan S, Basak N. The Protective Effects of Glycyrrhetic Acid and Chrysin against Ischemia-Reperfusion Injury in Rat Ovaries. Biomed Research International. 2018 May 14; 2018:5421308. doi: 10.1155/2018/5421308. PMID: 29862276; PMCID: PMC5976983.
23. Wu CX, Feng YH, Yang L, Zhan ZL, Xu XH, Hu XY, Zhu ZH, Zhou GP. Electroacupuncture exerts neuroprotective effects on ischemia/reperfusion injury in JNK knockout mice: the underlying mechanism. Neural Regeneration Research. 2018 Sep;13(9):1594-1601. doi: 10.4103/1673-5374.235294. PMID: 30127120; PMCID: PMC6126120.

24. Xiao Y, Chen W, Zhong Z, Ding L, Bai H, Chen H, Zhang H, Gu Y, Lu S. Electroacupuncture preconditioning attenuates myocardial ischemia-reperfusion injury by inhibiting mitophagy mediated by the mTORC1-ULK1-FUNDC1 pathway. Biomedicine and Pharmacotherapy. 2020 Jul; 127:110148. doi: 10.1016/j.biopha.2020.110148. Epub 2020 Apr 25. PMID: 32344255.
25. Liao J, Ke M, Xu T, Lin L. Electroacupuncture inhibits apoptosis in annulus fibrosis cells through suppression of the mitochondria-dependent pathway in a rat model of cervical intervertebral disc degradation. Genetics and Molecular Biology. 2012;35(3):686–692. doi: 10.1590/s1415-47572012005000046.
26. Stener-Victorin E, Fujisawa S, Kurosawa M. Ovarian blood flow responses to electroacupuncture stimulation depend on estrous cycle and on site and frequency of stimulation in anesthetized rats. Journal of Applied Physiology (1985). 2006 Jul;101(1):84-91. doi: 10.1152/jappphysiol.01593.2005. Epub 2006 Mar 2. PMID: 16514000.
27. Stener-Victorin E, Waldenström U, Andersson SA, Wikland M. Reduction of blood flow impedance in the uterine arteries of infertile women with electro-acupuncture. Human Reproduction. 1996 Jun;11(6):1314-7. doi: 10.1093/oxfordjournals.humrep.a019378. PMID: 8671446.
28. Shi Y, Li L, Zhou J, Sun J, Chen L, Zhao J, Wu L, Cui Y, Wu L, Wu H. Efficacy of electroacupuncture in regulating the imbalance of AMH and FSH to improve follicle development and hyperandrogenism in PCOS rats. Biomedicine and Pharmacotherapy. 2019 May; 113:108687. doi: 10.1016/j.biopha.2019.108687. Epub 2019 Mar 6. PMID: 30851546.
29. Chen Y, Fang Y, Yang J, Wang F, Wang Y, Yang L. Effect of acupuncture on premature ovarian failure: a pilot study. Evidence Based Complementary and Alternative Medicine. 2014; 2014:718675. doi:10.1155/2014/718675
30. Chen W, Chen J, Xu M, Zhong Z, Zhang Q, Yang W, Huang G. Electroacupuncture facilitates implantation by enhancing endometrial angiogenesis in a rat model of ovarian hyperstimulation. Biology of Reproduction. 2019 Jan 1;100(1):268-280. doi: 10.1093/biolre/iy0176. PMID: 30084973; PMCID: PMC6335210.
31. Sahin Ersoy G, Eken M, Tal R, Oztekin D, Devranoglu B, Isik Kaygusuz E, Cevik O. N-acetylcysteine leads to greater ovarian protection than enoxaparin sodium in a rat ovarian torsion model. Reproductive Biomedicine Online. 2016 Jul;33(1):93-101. doi: 10.1016/j.rbmo.2016.03.009. Epub 2016 Apr 7. PMID: 27083693.
32. Acar O, Esen T, Colakoglu B, Camli MF, Cakmak YO. Improving testicular blood flow with electroacupuncture-like percutaneous nerve stimulation in an experimental rat model of testicular torsion. Neuromodulation. 2015 Jun;18(4):324-8; discussion 328. doi: 10.1111/ner.12246. Epub 2014 Oct 6. PMID: 25284428.
33. Acioli PC, Albuquerque Ade O, Guimarães IB, Araujo RW, Vasconcelos PR, Guimarães SB. Protective effects of abdominal electroacupuncture on oxidative stress and inflammation due to testis torsion/detorsion in rats. Acta Cirurgica Brasileira 2014 Jul;29(7):450-6. doi: 10.1590/s0102-86502014000700007. PMID: 25054876.
34. Zackrisson U, Mikuni M, Peterson MC, Nilsson B, Janson PO, Brännström M. Evidence for the involvement of blood flow-related mechanisms in the ovulatory process of the rat. Human Reproduction. 2000 Feb;15(2):264-72. doi: 10.1093/humrep/15.2.264. PMID: 10655295.