



## Evaluation of Prevalence and Dimension of Pineal Gland Calcification by Cone-Beam Computed Tomography (CBCT)

Muazzez Süzen<sup>1,a\*</sup>, Emrah Dilaver<sup>1,b</sup>, Sina Uçkan<sup>1,c</sup>

<sup>1</sup>Department of Oral and Maxillofacial Surgery, Faculty of Dentistry, Istanbul Medipol University, Istanbul, Türkiye

\*Corresponding author

### Research Article

#### History

Received: 30/04/2022

Accepted: 07/09/2022

### ABSTRACT

**Objectives:** This study aimed to investigate the prevalence and dimensions of pineal gland calcification on cone-beam computed tomography (CBCT) in patients undergoing dental treatment.

**Materials and Methods:** We retrospectively examined CBCT scans in which the pineal gland appeared in the field of view and noted the presence of pineal gland calcification (PGC). Anteroposterior, lateral, and area measurements of the PGCs were made by the same observer. Variables such as age and gender were recorded for each patient from previous clinical examination data.

**Results:** Among 220 patients (135 females, 85 males), the prevalence of pineal gland calcification was 33.6%. There was no significant difference between males and females ( $p>0.05$ ). PGC was strongly associated with older age ( $p<0.001$ ). The PGCs had mean anteroposterior and lateral dimensions of  $2.56\pm0.98$  mm and  $3.39\pm1.29$  mm, respectively, and the mean total calcified area was  $5.45\pm3.75$  mm<sup>2</sup>.

**Conclusions:** This study showed no correlation between age, gender, and PGC size. However, the average calcified area was found to be significantly larger in men than women.

**Keywords:** Pineal Gland Calcification, CBCT, Dental Treatment.

## Konik Işınli Bilgisayarlı Tomografi ile Pineal Bez Kalsifikasyonunun boyutu ve prevalansının incelenmesi (KIBT)

#### Süreç

Geliş: 30/04/2022

Kabul: 07/09/2022

### ÖZ

**Amaç:** Bu çalışmada diş tedavisi yapılan hastalarda konik ışınli bilgisayarlı tomografi (KIBT) ile Pineal bez kalsifikasyonunun prevalansı ve boyutlarının değerlendirilmesi amaçlandı.

**Materyal ve Metot:** Bu retrospektif çalışmada pineal bezin fov aralığında olduğu konik ışınli bilgisayarlı tomografiler seçilmiştir. Pineal bez kalsifikasyonu görünürlüğü not edilmiştir. Anteroposterior, lateral ve alan ölçümleri tek bir gözlemci tarafından yapılmıştır. Her hastanın yaş, cinsiyet gibi değişkenleri, klinik muayene verileri kullanılarak kaydedilmiştir.

**Bulgular:** 220 hastada (135 kadın, 85 erkek) pineal bez kalsifikasyonu prevalansı %33.6'dır. Erkekler ve kadınlar arasındaki fark anlamlı değildir. Pineal bez kalsifikasyonu, genç hastalarla karşılaştırıldığında yaşlı hastalarda yüksek oranda görüldü. PGC'nin ortalama anteroposterior, lateral uzunluğu sırasıyla  $2,56\pm0,98$  mm ve  $3,39\pm1,29$  mm idi. Ortalama toplam kalsifiye alan  $5,45\pm3,75$  mm<sup>2</sup> idi.

**Sonuçlar:** Bu çalışmada yaş, cinsiyet ve lineer ölçümler arasında herhangi bir ilişki bulunmadı. Ancak erkeklerde ortalama kalsifiye alan kadınlara göre anlamlı derecede yüksek bulunmuştur.

**Anahtar Kelimeler:** Pineal Bez Kalsifikasyonu, Konik Işınli Bilgisayarlı Tomografi, Diş Tedavisi.

#### License



This work is licensed under  
Creative Commons Attribution 4.0  
International License

<sup>a</sup> [muazzez.suzen@gmail.com](mailto:muazzez.suzen@gmail.com)

<sup>c</sup> [suckan@yahoo.com](mailto:suckan@yahoo.com)

<sup>b</sup> <https://orcid.org/0000-0001-5121-9158>

<sup>c</sup> <https://orcid.org/0000-0003-1077-7342>

<sup>b</sup> [emrahdilaver@gmail.com](mailto:emrahdilaver@gmail.com)

<sup>b</sup> <https://orcid.org/0000-0003-4522-1424>

**How to Cite:** Süzen M, Dilaver E, Uçkan S. (2022) Evaluation of Prevalence and Dimension of Pineal Gland Calcification by Cone-Beam Computed Tomography (CBCT), Cumhuriyet Dental Journal, 25(3): 258-262

## Introduction

The pineal (epiphysis) gland is a neuroendocrine organ that is embryologically developed from the posterior upper part of the third ventricle. It weighs 100-180 mg, is 5-9 mm in length, 3-6 mm in width, and 3-5 mm in depth, and is surrounded by connective tissue of the pia mater.<sup>1-3</sup> This gland is responsible for regulating physiological cycles by sending time signals to other parts of the body in circadian rhythm by secreting melatonin during darkness.<sup>4,5</sup>

Pineal gland calcification (PGC) was first described in the cranial X-rays of autopsy specimens in 1918.<sup>6,7</sup> Age is reported to be the most critical factor in the incidence of PGC in humans.<sup>8</sup> In previous studies, the frequency of PGC was reported to range from 1.3% to 16.7% and was shown to increase with age.<sup>8-10</sup> Although uncommon, PGC can also be seen in children under 5 years of age.<sup>11,12</sup>

Pineal calcification also depends on environmental factors, such as altitude and sunlight exposure. However, the reasons for differences in calcification between different populations is not fully understood.<sup>8,13</sup> Factors such as age, gender, race, geographical region, lifestyle, nutrition, and social behavior may also affect the calcification process.<sup>10</sup>

Melatonin secretion decreases with PGC and age. A decrease may also be related to cancer or various neurodegenerative diseases such as migraine, schizophrenia, Alzheimer's, Parkinson's, epilepsy, depression, and stroke.<sup>14-16</sup> Therefore, identifying physiological and pathological calcifications is essential for early diagnosis.

Intracranial calcifications can be detected by cranial X-ray, computed tomography (CT), magnetic resonance imaging (MRI), and ultrasonography. However, CT is the most sensitive method. In recent years, the use of cone-beam CT (CBCT) has been widely adopted in dentistry practice for various reasons, including implant therapy, wisdom teeth, and jaw cysts. Thus, it may be clinically helpful to detect calcifications.<sup>13,17</sup>

This retrospective study investigated the prevalence and dimensions of PGC according to age and gender patients who underwent CBCT of the upper face.

## Materials and Method

This retrospective study was approved by the Ethics Committee of Istanbul Medipol University (ethics approval number 10840098-604.01.01-E.15729).

A total of 1176 CBCT images obtained between 2014 and 2019 were screened, and those that included the pineal gland in the field of view were analyzed. Patients with bone

disease, drug use, congenital disorders, trauma history, history of tumor or malignancy, and previous surgery were excluded from the study.

All images were obtained using the i-CAT 17-19 Imaging System (Imaging Sciences International, Inc., Hatfield, PA, USA) at 120 kVp and 5 mA. CBCT images were evaluated in Invivo5 software (Anatomage Inc., San Jose, CA, USA). PGC was identified within the cranium at the midline in the posterior cranial fossa in the axial, coronal, and sagittal planes (Figure 1). Linear measurements (anteroposterior and lateral dimensions) and area of calcification were calculated in the axial plane (Figure 2). Measurements were repeated three times for reliability by the same observer. The patients' age and gender at time of CBCT examination were noted from their medical records. For age group analysis, the prevalence of PGC was determined in patients aged  $\leq 10$ , 11-20, 21-30, 31-40, 41-50, 51-60, 61-70, and  $\geq 71$  years of age.

## Statistical Analysis

Study data were analyzed using IBM SPSS Statistics version 22 (IBM Corp, Armonk, NY) software. Data distributions were evaluated with the Kolmogorov-Smirnov and Shapiro Wilks tests, and it was determined that the parameters did not show normal distribution. Data were summarized using descriptive statistical methods (mean, standard deviation, frequency). Quantitative data were analyzed using Kruskal-Wallis test with post-hoc Dunn's test for comparisons among multiple groups and using Mann-Whitney U test for comparisons between two groups. Chi-square tests were used to compare qualitative data. Spearman's rho correlation analysis was used to examine the relationships between parameters. Significance was evaluated at the level of  $p < 0.05$ .

## Results

Out of 1176 records, 220 CBCT scans were evaluated in this retrospective study. There were 135 females (61.4%) and 85 males (38.6%) with a mean age of  $28.79 \pm 17.76$  years. PGC was seen in 29 (34.1%) of the male patients and 45 (33.3%) of the female patients, with no significant difference between genders ( $p > 0.05$ ) (Table 1). The mean age of patients with PGC was  $39.34 \pm 18.49$  years, compared to  $23.45 \pm 14.79$  years in those without PGC ( $p < 0.001$ ). There was a statistically significant positive relationship between age and PGC, with a steady increase in the rate of PGC detection between age groups ( $p < 0.001$ ) (Table 1).

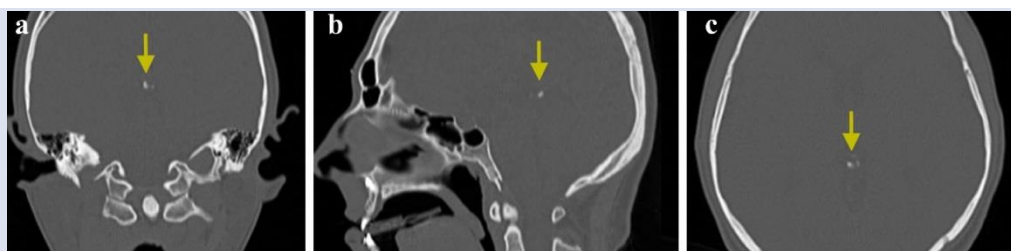


Figure 1. Coronal (a), sagittal (b), and axial (c) cone-beam computed tomography sections showing pineal gland calcification.

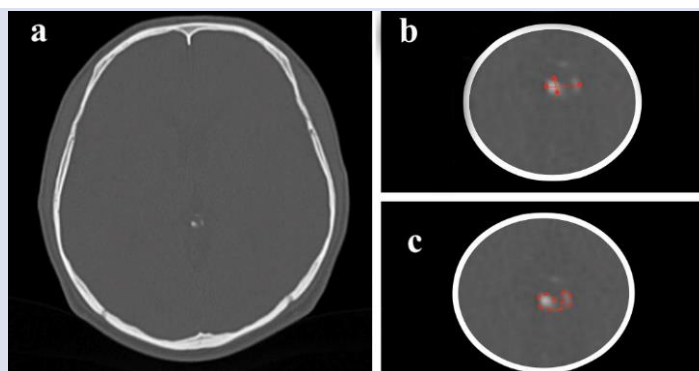


Figure 2. Axial cone-beam computed tomography (CBCT) section (a) and measurements of the anteroposterior and lateral dimensions (b) and area (c) of pineal gland calcification.

Table 1. Evaluation of pineal gland calcification (PGC) according to age and gender

		PGC		P
		No n (%)	Yes n (%)	
Gender	Female	90 (66.7%)	45 (33.3%)	1.000
	Male	56 (65.9%)	29 (34.1%)	
Age	<10	5 (100%)	0 (0%)	<0.001*
	10-19	79 (83.2%)	16 (16.8%)	
	20-29	31 (73.8%)	11 (26.2%)	
	30-39	13 (54.2%)	11 (45.8%)	
	40-49	7 (38.9%)	11 (61.1%)	
	50-59	5 (25%)	15 (75%)	
	60-69	2 (20%)	8 (80%)	
	>70	4 (66.7%)	2 (33.3%)	

Chi-square test\* p<0.05

Table 2 Mean values of linear measurements of pineal gland calcification

	n	Min	Max	Mean±SD
Horizontal (mm)	74	1.72	7.31	3.39±1.29
Vertical (mm)	74	1.22	6.79	2.56±0.98
Area (mm <sup>2</sup> )	74	1.18	20.19	5.45±3.75

Abbreviations: SD: Standard Deviation

Table 3. Correlation of age and pineal gland calcification dimensions

	Age	
	r	p
Horizontal	0.073	0.537
Vertical	0.139	0.239
Area	0.119	0.313

Spearman's rho correlation test

Based on linear measurements, the PGCs had a mean anteroposterior dimension of 3.39±1.29 mm, mean lateral dimension of 2.56±0.98 mm, and mean calcified area of 5.45±3.75 mm<sup>2</sup> (Table 2). There was no statistically significant correlation between age and PCG anteroposterior, lateral, or area measurements (p>0.05) (Table 3).

## Discussion

Melatonin is an essential mediator of bone formation that inhibits bone resorption by interfering with osteoclasts. Melatonin may also play a physiological role in tooth development/growth by regulating the cellular function of odontogenic cells in tooth germs.<sup>29</sup> It has been shown that melatonin has high antioxidant and anti-inflammatory properties because it suppresses interleukin-6 and nitric oxide production.<sup>18</sup> Theoretically, increased

melatonin concentrations in the plasma and saliva may decrease rates of periodontal disease and caries due to its protective effect. Additionally, more caries lesions develop in the spring and summer, when melatonin levels are lowest, and fewer caries occur in the autumn and winter, when melatonin levels are highest.<sup>19</sup> Several studies have investigated PGC, melatonin secretion, and their relationship with other diseases.<sup>20,21</sup> However, most studies on PGC in the dental literature have been based on prevalence. Few studies have investigated correlations between age, gender, and the extent of PGC.<sup>2,8,22</sup>

Sedghizadeh et al. reported intracranial calcification rates as high as 80%.<sup>22</sup> However, Abbassian et al. reported the prevalence of PCG as 18.3% in individuals over the age of 20 years,<sup>23</sup> while the prevalence of PGC in other studies ranged between 11.8% and 26.2%.<sup>24-27</sup> The prevalence rate in the present study (33.6%) was higher than in previous studies.

Some studies in the literature have indicated that PGC is more common in males than females.<sup>8,24</sup> However, another study showed that the occurrence rate was higher in females.<sup>13</sup> In the present study, the prevalence of calcification was similar in females (33.3%) and males (34.1%).

According to Whitehead et al., PGCs were punctate and single in all patients younger than 7 years old and were generally more extensive and numerous in patients older than 7 years.<sup>11</sup> In addition, Deepak et al. stated that PGC is rare in children younger than 6 years old, and a pineal gland tumor should be considered when calcification is detected before the age of 9 years and is larger than 1 cm in diameter.<sup>28,29</sup> Therefore, a careful examination is necessary in patients younger than 7 years of age with extensive PGC. In the present study, the youngest patient with PGC was a 14-year-old girl.

Similar to our results, in another study the average PGC dimensions were reported as 3.73 mm in the anteroposterior direction and 3.47 mm in the medio-lateral direction with a total area of 9.79 mm<sup>2</sup>, and no correlation was observed between calcification size and age.<sup>13</sup>

This study suggests that the prevalence of PGC as an incidental finding is high among patients undergoing dental therapy. Numerous studies show that melatonin can be an important factor in the development of caries and periodontal diseases.<sup>19,30-33</sup> However, as this was a retrospective study, we were unable to evaluate melatonin levels in these patients. Further studies including larger samples with more standardized and specific groups are needed to determine the relationships between PGC, melatonin production, and caries and periodontal diseases.

## Conclusions

In conclusion, detection of PGC was associated with older age, but age was not associated with the linear dimensions of the calcified area. In addition, the average calcified area was significantly larger in men than women.

## Conflicts of Interest

The authors declare no conflict of interest.

## Funding

None

## Author Contributions

Concept: M.S.; Supervision: M.S., S.U.; Materials: M.S., E.D.; Data Collection and Processing: M.S., E.D.; Analysis and Interpretation: M.S., E.D., S.U.; Writing: M.S., E.D

## References

- Reiter RJ. The Mammalian Pineal Gland: Structure and function. *Am J Anat* 1981; 162: 287-313.
- Kappers AJ. The mammalian pineal gland, a survey. *Acta neurochir* 1976; 34: 109-149.
- Palaoğlu S, Beşkonaklı, E. Pineal bez ve yaşlanma. *Turkish Journal of Geriatrics* 1998; 1:13-18.
- Pandi-Perumal SR, Srinivasan V, Maestroni GJM, Cardinali DP, Poeggeler B, Hardeland R. Melatonin: nature's most versatile biological signal? *The FEBS journal* 2006; 273: 2813-2838.
- Reiter RJ. Melatonin: clinical relevance. *Best practice & research clinical endocrinology & metabolism*.2003;17:273-285.
- Scharenberger K, and Liss L. The histological structure of the human pineal body. *progress in brain research* 1965; 10: 193-217.
- A. Schüller, *Roentgen Diagnosis of Diseases of the Head*, C.V. Mosby Comp., St. Louis, 1918: 156.
- Turgut A, Karakaş HM, Özsunar Y, Altın L, Çeken K, Alicioğlu B, et al. Age-related changes in the incidence of pineal gland calcification in Turkey: A prospective multicenter CT study. *Pathophysiology* 2008; 15: 41-48.
- Wurtman RJ, Axelrod J, Barchas JD. Age and enzyme activity in human pineal, *J. Clin. Endocrinol. Metab* 1964; 24: 299-301.
- Haghighi MH, Rezaei V, Zarrintan S, Pourfathi H. Intracranial physiological calcifications in adults on computed tomography in Tabriz, Iran. *Folia Morphol* 2007; 66: 115-119.
- Whitehead MT, Oh C, Raju A, Choudhri AF. Physiologic pineal region, choroid plexus, and dural calcifications in the first decade of life. *AJNR Am J Neuroradiol* 2015; 36: 575-580.
- Doyle AJ, Anderson GD. Physiologic calcification of the pineal gland in children on computed tomography: prevalence, observer reliability and association with choroid plexus calcification. *Acad Radiol* 2006; 13: 822-826.
- Mutalik S, Tadinada A. Prevalence of pineal gland calcification as an incidental finding in patients referred for implant dental therapy. *Imaging science in dentistry* 2017; 47: 175-180.
- Tharnpanich, T, Johns J, Subongkot S, Johns NP, Kitkhuandee A, Toomsan Y, Luengpailinc S. Association between high pineal fluoride content and pineal calcification in a low fluoride area. *Fluoride* 2016; 49: 472-484.
- Kitkhuandee A, Sawanyawisuth K, Johns NP, Kanpittaya J, Johns J. Pineal calcification is associated with symptomatic cerebral infarction. *J Stroke Cerebrovasc Dis* 2014; 23: 249-253.
- Mahlberg R, Walther S, Kalus P, Bohner G, Handel S, Reischies FM, et al. Pineal calcification in Alzheimer's disease: an in vivo study using computed tomography. *Neurobiol Aging* 2008; 29: 203-209.
- Yalcin A, Ceylan M, Bayraktutan O F, Sonkaya A R, Yuçe I. Age and gender related prevalence of intracranial calcifications in CT imaging; data from 12,000 healthy subjects. *Journal of chemical neuroanatomy* 2016; 78: 20-24.
- E. Y. Choi, J. Y. Jin, J. Y. Lee, J. I. Choi, I. S. Choi, and S. J. Kim, "Melatonin inhibits Prevotella intermedia lipopolysaccharide-induced production of nitric oxide and interleukin-6 in murine macrophages by suppressing NF-κB and STAT1 activity" *Journal of Pineal Research* 2011; 50: 197-206.
- C. Mechin and C. Toury, "Action of cariogenic diet on fixation and retention of skeleton and teeth strontium in rats," *Revue Odonto Stomatologique* 1973; 20: 55-59.
- Hossain MF, Uddin MS, Uddin GMS, Sumsuzzman DM, Islam MS, Barreto GE, Mathew B, Ashraf GM. Melatonin in Alzheimer's Disease: A Latent Endogenous Regulator of Neurogenesis to Mitigate Alzheimer's Neuropathology. *Mol Neurobiol.* 2019; 56: 8255-8276.
- Kay SR, Sandyk R. Experimental models of schizophrenia. *Int. J. Neurosci* 1991; 58: 69-82.

22. Sedghizadeh PP, Nguyen M, Enciso R. Intracranial physiological calcifications evaluated with cone beam CT. *Dentomaxillofac Radiol* 2012; 41: 675-678.
23. Abbassioun K, Aarabi B, Zarabi M. A comparative study of physiologic intracranial calcifications. *Pahlavi Med J* 1978; 9: 152-166.
24. Mohammed KA, Boakye EA, Ismail HA, Geneus CJ, Tobo BB, Buchanan PM, Zelicoff AP. Pineal gland calcification in Kurdistan: a cross-sectional study of 480 roentgenograms. *PloS one* 2016; 11: 1-9.
25. Barghan S, Tahmasbi Arashlow M, Nair MK. Incidental findings on cone-beam computed tomography studies outside of the maxillofacial skeleton. *Int J Dent* 2016; 2016: 1-9.
26. Pette GA, Norkin FJ, Ganeles J, Hardigan P, Lask E, Zfaz S, et al. "Incidental findings from a retrospective study of 318 cone-beam computed tomography consultation reports." *The International Journal of Oral& Maxillofacial Implants* 2012; 27: 595-603.
27. Admassie D, Mekonnen A. "Incidence of normal pineal and choroid plexus calcification on brain CT (computerized tomography) at Tikur Anbessa TeachingHospital Addis Ababa, Ethiopia," *Ethiopian Medical Journal* 2009; 47: 55-60.
28. Deepak S, Jayakumar B, Shanavas. "Extensive intracranial calcification," *Journal of Association of Physicians of India* 2005; 53: 948.
29. Grech, R, Grech S, Mizzi A. Intracranial Calcifications: A Pictorial Review. *The neuroradiology journal* 2012; 25: 427-451.
30. Mechin JA, Toury C. "Action of melatonin on caries development in rats," *Journal of Dental Research* 1976; 55: 555.
31. Reiter RJ, Rosales-Corral SA, Liu XY, Acuna-Castroviejo D, Escames G, Tan DX Melatonin in the oral cavity: physiological and pathological implications. *Journal of periodontal research* 2015; 50: 9-17.
32. Cutando A, Galindo P, Gomez-Moreno G et al. Relationship between salivary melatonin and severity of periodontal disease. *J Periodontol* 2006; 77: 1533-1538.
33. Almughrabi OM, Marzouk KM, Hasanato RM, Shafik SS. Melatonin levels in periodontal health and disease. *J Periodont Res* 2013; 48: 315-321.