

# Maxillofacial Radiology 196

SADJ February 2022, Vol. 77 No.1, p37-38

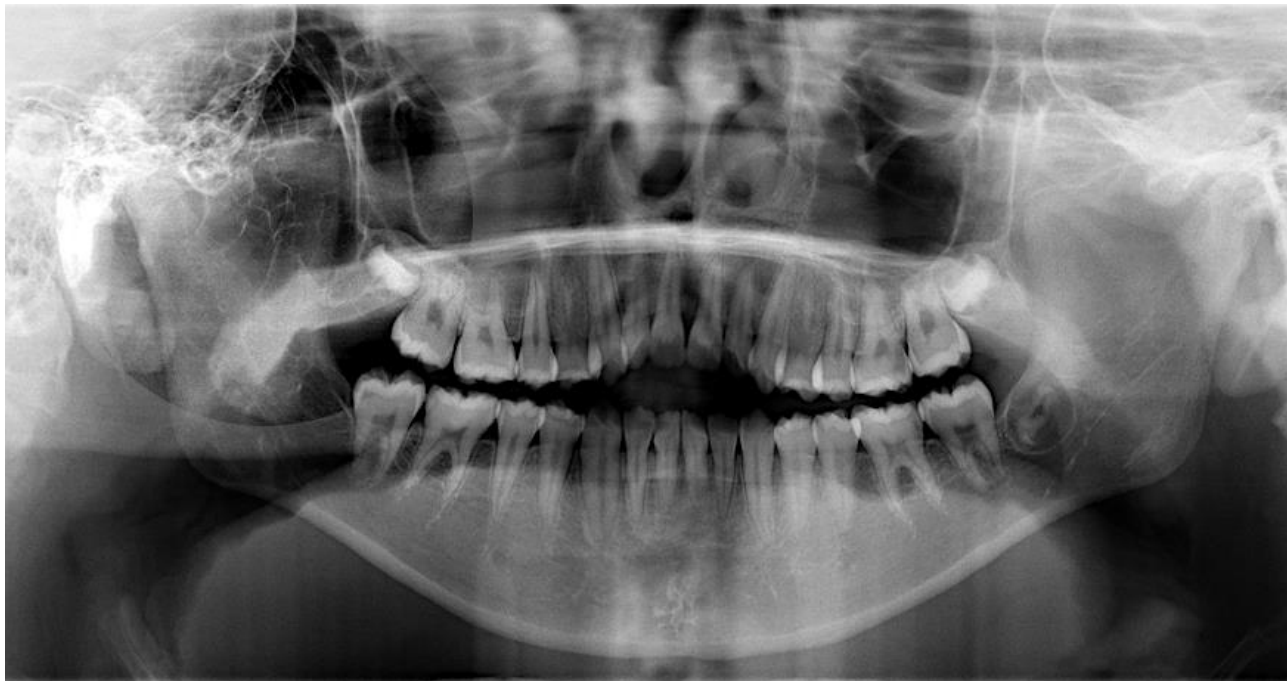C Smit<sup>1</sup>, A Uys<sup>2</sup>

## HYPERPNEUMATISATION OF THE SKULL BONES

### CASE

A healthy, 12-year-old female patient, presented with an anterior open bite requesting orthodontic treatment. A panoramic radiograph was requested for treatment planning (Figure 1). An incidental finding of well-defined multilocular radiolucencies were detected superimposed over the right ramus and middle cranial fossa region. The patient was asymptomatic with no clinical signs of facial asymmetry. A cone-beam computerised tomography (CBCT) scan was requested to exclude any occult pathology (Figure 2).

Figure 1. Panoramic radiograph



### INTERPRETATION

The CBCT images showed multiple air-filled spaces that are continuous with the mastoid air cells, affecting the temporal and sphenoidal bones (Figure 2 A-D). The airspaces were limited to the right side and were associated with areas of mild expansion, best visualised in the lateral and medial pterygoid plates (Figure 2C). Pneumatization is the process

of airspace formation within the bones of the cranium. Pneumatization or enlargement of the paranasal sinuses, as well as the extension of mastoid air cells anteriorly to involve the temporomandibular joint complex, are commonly reported.<sup>1</sup> However hyperpneumatization involving the temporal, occipital and parietal bones are rare with a reported prevalence of 0.0003%.<sup>2,3</sup> The aetiology is due to a combination of congenital and environmental factors, including increased pressure within the middle ear.<sup>3</sup>

These entities are often asymptomatic with infrequent reports of tinnitus or headaches. Radiologically they present with a multilocular/ honeycomb appearance with minimal expansion. Recognition of this entity is important as the structural integrity of the bone is affected with an increased risk of fracture after minor trauma.<sup>2</sup> Additionally, it should be differentiated from other pathological entities such as aneurysmal bone cysts or intrabony vascular malformations.

Valsalva manoeuvres in an attempt to relieve the tinnitus are discouraged in these patients as this can lead to damage to the tympanic membrane.<sup>3</sup> Placement of pressure-equalisation tubes can assist in the alleviation of symptoms.<sup>3</sup>

#### Author affiliations:

1. C Smit: BChD, MSc (Maxillofacial and Oral Radiology). Department of Oral Pathology and Oral Biology, Faculty of Health Sciences, University of Pretoria. ORCID: 0000-0003-4047-6356
2. A Uys: BSc, BChD, PGDipDent (Endodontics), PGDipDent (Aesthetic Dentistry), MSc (Maxillofacial Radiology), PhD (Anatomy). Department of Anatomy, Faculty of Health Sciences, University of Pretoria. ORCID: 0000-0001-8250-7662

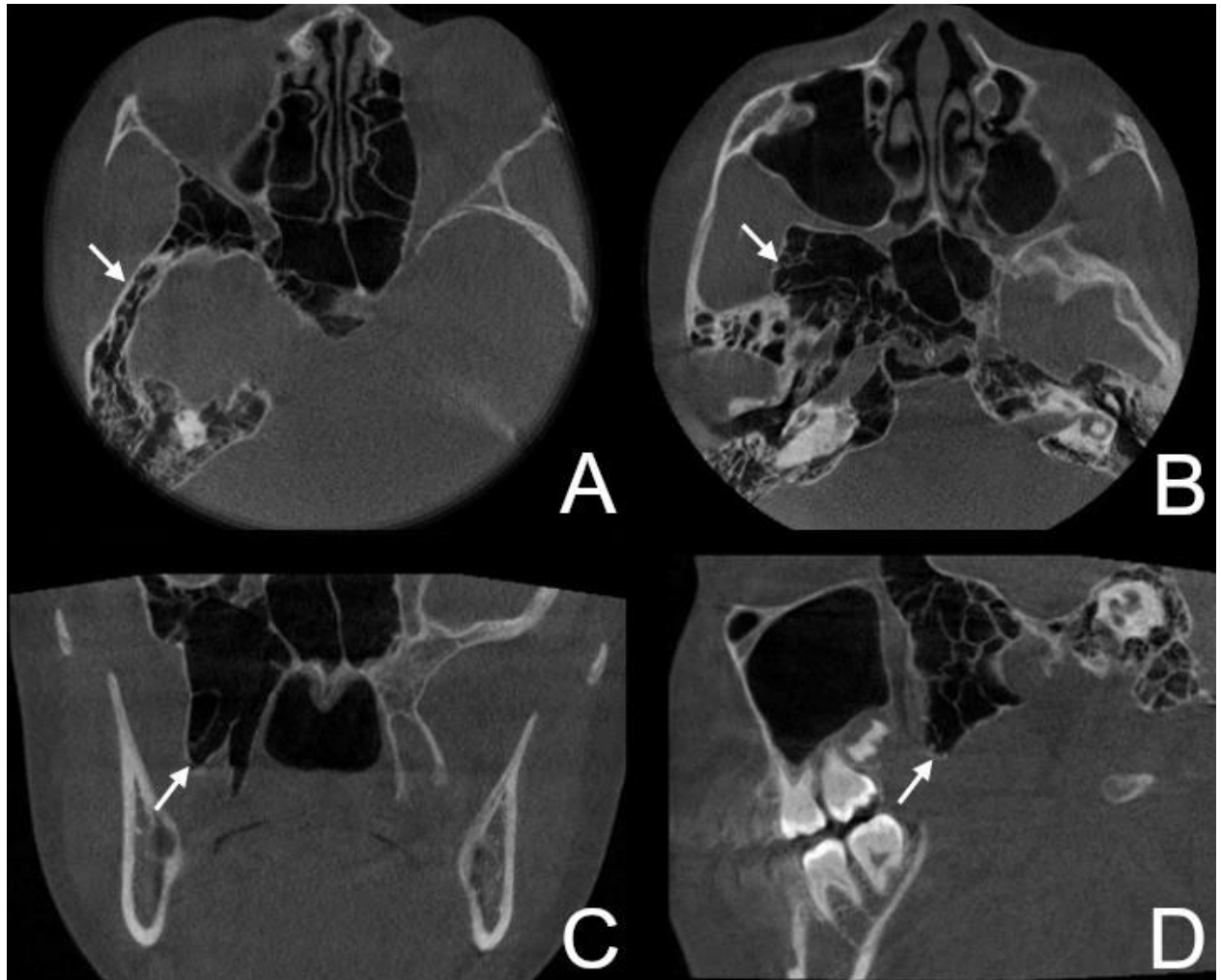
#### Corresponding author: Chané Smit

Department of Oral Pathology and Oral Biology, Faculty of Health Sciences.  
Email: chane.smit@up.ac.za, Tel: +27 (0)12 319 2311,

#### Authors contribution:

C Smit: 70%  
A Uys: 30%

Figure 2. (A,B) Axial, (C) coronal and (D) sagittal CBCT images



Cone beam computed tomography is an accessible modality which can be used for detailed assessment and measurement of air space volumes and surgical planning in these cases.

#### Authors declaration

**Funding:** This research did not receive any specific grant from funding agencies in the public, commercial, or not-for-profit sectors.

**Conflict of Interest:** The authors declare that they have no conflict of interest.

**Ethics approval:** This study was approved by the University of Pretoria, Faculty of Health Sciences Research Ethics Committee (Reference no.: 423/2021). All procedures followed the ethical standards of the Helsinki Declaration of 1975, as revised in 2008.

#### REFERENCES

1. Şallı GA, Özcan İ, Pekiner FN. Prevalence of pneumatization of the articular eminence and glenoid fossa viewed on cone-beam computed tomography examinations in a Turkish sample. *Oral Radiol.* 2020;36(1):40-46. doi:10.1007/s11282-019-00378-1
2. AbdulAzeez M, Huber P-Z, Alsaadi S, Vladimir C-N, Salazar LM, Hoz S. Cranio-cervical bone hyperpneumatization: An overview and illustrative case. *J Acute Dis.* 2018;7(4):145. doi:10.4103/2221-6189.241007
3. Tomblinson CM, Deep NL, Weindling SM, et al. Craniocervical pneumatization: Estimation of prevalence and imaging of treatment response. *Otol Neurotol.* 2016;37(6):708-712. doi:10.1097/MAO.0000000000001024

## CPD questionnaire on page 43



The Continuous Professional Development (CPD) section provides for twenty general questions and five ethics questions. The section provides members with a valuable source of CPD points whilst also achieving the objective of CPD, to assure continuing education. The importance of continuing professional development should not be underestimated, it is a career-long obligation for practicing professionals.