

This is a provisional PDF only. Copyedited and fully formatted version will be made available soon.

REPORTS OF PRACTICAL ONCOLOGY AND RADIOTHERAPY

ISSN: 1507-1367

e-ISSN: 2083-4640

Consideration of mouth opening when using positioning stents during radiotherapy for tongue cancer: a retrospective study

Authors: Kazuma Nakazawa, Junko Nakajima, Ken Ishizaki, Takayuki Ueda, Takeshi Nomura

DOI: 10.5603/RPOR.a2022.0107

Article type: Research paper

Published online: 2022-10-04

This article has been peer reviewed and published immediately upon acceptance. It is an open access article, which means that it can be downloaded, printed, and distributed freely, provided the work is properly cited.

Consideration of mouth opening when using positioning stents during radiotherapy for tongue cancer: a retrospective study

10.5603/RPOR.a2022.0107

Kazuma Nakazawa¹, Junko Nakajima², Ken Ishizaki³, Takashi Nomura⁴, Takayuki Ueda¹

¹Department of Removable Prosthodontics and Gerodontology, Tokyo Dental College, Tokyo, Japan

²Department of Oral Medicine and Hospital Dentistry, Ichikawa General Hospital, Tokyo Dental College, Chiba, Japan

³Department of Oral Rehabilitation and Maxillofacial Surgery, School of Medicine, International University of Health and Welfare, Chiba, Japan

⁴Department of Oral Oncology, Oral and Maxillofacial Surgery, Tokyo Dental College, Tokyo, Japan

Abstract

Background: The aim was to clarify the range of mouth opening required to minimize the development of oral mucositis on the palate while using a positioning stent during radiotherapy in patients with tongue cancer.

A positioning stent is used to reduce the severity of oral mucositis; however, requirements for fabricating the device have not been standardized. In particular, the range of mouth opening required while using a stent to prevent radiation-induced oral mucositis has not been determined.

Material and methods: We retrospectively analyzed medical records and computed tomography (CT) images of nine patients who had undergone radiotherapy for tongue cancer. Irradiation dose for the palate and range of mouth opening while using the positioning stent was calculated from CT images and the radiotherapy treatment planning program.

Results: The irradiation dose presented as medians and interquartile range (IQR) for the palate was 1.6 (IQR: 1.1–2.2) Gy with the use of the positioning stent and 37.2 (IQR: 17.5–44.1) Gy without the use of the positioning stent. The range of mouth opening was 19–37 [mean \pm standard deviation (SD): 26 ± 5.6] mm, and it correlated with the attenuation amount of irradiation dose to the palate ($r = 0.673$, $p = 0.0467$). Regression equation was $y = 0.21x + 19$.

Conclusions: Our study may be useful for deriving the relationship between the attenuation amount of irradiation of the palate with the positioning stent and the amount of mouth opening required for this attenuation.

Key words: tongue cancer; radiotherapy; positioning stent; oral mucositis

Introduction

Treatments for tongue cancer include surgery, radiotherapy, chemotherapy, and immunotherapy. For treatment of oral cancer, the preservation of mastication, swallowing function, speech, and aesthetics is desired. Chemoradiotherapy, the standard treatment for unresectable advanced oral cancer, can also preserve organ integrity and function in resectable advanced head and neck cancer (HNC) [1–6].

Radiotherapy can lead to complications, such as oral mucositis, xerostomia, hyposalivation, taste disorders, and osteoradionecrosis, which can seriously affect quality of life (QOL) [7]. It has been reported that 69% of patients who had received radiotherapy for

HNC experienced oral pain, and 23% experienced Grade 3 to 4 mucositis [8]. Radiation-induced oral mucositis is typically experienced after administering cumulative doses of 15 Gy and reaches full severity > 30 Gy [9]. Although distribution of oral mucositis is predominantly associated with the distribution of radiation dose, non-keratinized oral tissues (i.e., buccal mucosa, lateral tongue, soft palate, and the floor of the mouth) are more susceptible to oral mucositis than keratinized oral tissues [10].

In order to reduce the severity of oral mucositis, it is important to perform systematic oral hygiene management (oral care) before, during, and after radiotherapy [11, 12]. This safeguards against the interruption and dose reduction of radiotherapy to some extent and improves the prognosis of treatment itself. However, not all radiation-induced oral mucositis can be prevented by oral hygiene management.

Another approach to prevent radiation-induced oral mucositis is by using oral devices, such as the positioning stent (Fig. 1), which are effective at excluding healthy tissue from the irradiation field [12–14]. Nayar et al. reported that when radiotherapy using a positioning stent was performed in patients with HNC, there was a significant difference in the irradiation dose to the opposite jaw [15]. Verrone et al. reported on the use of a positioning stent during intensity-modulated radiation therapy (IMRT) for tongue and floor of mouth tumors and showed that it delayed the occurrence of severe mucositis [16]. However, the requirements for fabricating the device have not been standardized. In particular, the range of mouth opening required while using the stent to prevent radiation-induced oral mucositis has not been determined.

The objective of this study was to clarify the range of mouth opening required while using the positioning stent to prevent mucositis on the palate during radiotherapy in patients with tongue cancer.

Materials and methods

Subjects

A total of 107 patients diagnosed with tongue cancer at Ichikawa General Hospital, Tokyo Dental College between April 2016 and January 2019 participated in this study. The inclusion criteria were that radiotherapy was performed using a positioning stent, and exclusion criteria included missing data, interrupted treatment, upper jaw inclusion in the irradiation field, or irradiation to the neck only. Nine patients met these criteria, and their radiotherapy records were analyzed (Fig. 2). This study was approved by the ethics committee of the Ichikawa General Hospital, Tokyo Dental College (I 16-07RII).

Fabrication of positioning stent

Prior to radiotherapy, positioning stents were fabricated for each patient by an experienced dentist and a dental technician as follows. First, the size and location of the tumors were confirmed by a radiation oncologist. Positioning stents were custom-made so that healthy tissue was excluded from the irradiation field. For larger tumors or tumors close to the caudal palate, the range of mouth opening needed for using the positioning stent was also larger. Impressions were taken of the patient's maxilla and mandibular jaw using alginate impression material (Deguprint, Dentsply Sirona K.K., Tokyo, Japan), and definitive casts were made (NEW PLASTONE II LE, GC Corporation, Tokyo, Japan). The patients were instructed to hold their mouth open, and then a vinyl silicone impression material (EXAFINE (PUTTY TYPE), GC Corporation, Tokyo, Japan) was inserted between the maxillary and mandibular teeth to record the maxillomandibular relationship. The definitive casts were mounted on an articulator, with the vinyl silicone impression material as interocclusal recording materials

between the dental casts. The positioning stent was fabricated of transparent curing silicone (Odontsil, DREVE, Germany) and layers were built up between the maxillary and mandibular casts. It held the mouth open while covering the dentition or alveolar ridge of the maxilla and mandible, and positioning was tested before initiating radiotherapy. If necessary, adjustments were made. When the palate was included in the irradiation field due to trismus, a tongue depressor was used to maintain the distance between the tongue and palate.

Radiotherapy plan

A radiation oncologist prepared the radiotherapy plan according to the Radiation Treatment Planning Guideline (2016) of the Japanese Society for Radiation Oncology [17] and the radiotherapy treatment planning (RTP) program (XiO, Elekta AB, Sweden). First, the volume of tumor required for extraction was determined. Then, the gross tumor volume (GTV), clinical target volume (CTV), and planning target volume (PTV) were calculated. GTV was determined by clinical findings (physical examination, palpation) and imaging findings (CT images, MRI images, PET images) according to the tumor, nodes, and metastases (TNM) classification by Unio Internationalis contra Cancrum. CTV was defined to include suspected tumor invasion in addition to the clearly identifiable tumor. Sufficient doses were required to be delivered to GTV and CTV to obtain a curative treatment. PTV was determined by considering any uncertainties and was composed of an additional internal margin and set-up margin over CTV. The dose prescription for radiotherapy was based on reference points in PTV, per the International Commission Radiation Units and Measurements.

Three-dimensional radiotherapy plans were created based on CT images. The contour of CTV was superposed on the CT image, and the energy of the treatment beam, the irradiation direction, the irradiation field, and dose division were determined. Three-dimensional

conformal radiation therapy (3DCRT) was performed by using a linear accelerator (ONCOR Impression plus, SIMENS, Germany). The duration of radiotherapy delivery was approximately 5 minutes.

Measurements

In this retrospective study, the total irradiation dose for the palate and range of mouth opening was calculated using the RTP program. This study defined the irradiation dose as simulative calculated dose from the RTP program rather than the actual irradiation dose recorded from the patient's oral cavity.

In order to compare the effect of wearing a positioning stent, a pair of CT images for each patient was used in this study. One image (slice thickness: 3 mm) was taken with the mouth closed for diagnosis (therefore, no positioning stent was used), and the other (slice thickness: 3 mm) was taken with the mouth open using a positioning stent to plan the radiotherapy program. The CT images with and without a positioning stent were reconstructed by the RTP program to consist of the cross sections that pass through the center of the tumor (slice thickness: 3 mm). The radiotherapy plan was extracted from a CT image with a positioning stent. Then, it was superimposed on a CT image without a positioning stent. To decrease the error of superimposing non-standardized CT images, the central point of the tumor in each plane and the outline and maximum prominence of the tumor were used as the reference to superimpose.

The range of mouth opening was calculated on a CT image of the sagittal section using the distance between the anterior nasal spine and menton (Me) with and without utilizing the positioning stent. The point where a line perpendicular to that connecting the right and left maxillary first molars intersects (on the palatal surface of the coronal plane) was set as the

measuring point (Fig. 3). Of note, for the patient who had lost molars, we assumed that their maxillary second molars were located on the connecting line of the outermost protruding point¹⁸ of the coronal plane and, therefore, set a replacement line parallel to it but forward by 9 mm (the average mesiodistal width of the maxillary second molar¹⁸) as a means to connect the first molars.

The total irradiation dose was calculated by multiplying the irradiation dose at the measurement point by the number of irradiation doses for each patient. Attenuation amount of irradiation dose for the palate was defined as the difference between the with and without the positioning stent used. Attenuation rate of irradiation dose for the palate was defined as the difference between the with and without the positioning stent used that divided by the irradiation dose without the positioning stent used. The development of oral mucositis and status of oral intake during the therapy were inferred from medical records. The worst scores for each patient were used. Oral mucositis was evaluated according to Common Terminology Criteria for Adverse Events (CTCAE) version 5.0 using each patient's dental and medical records.

Statistical analysis

The irradiation dose of the palate with and without the use of the positioning stent was compared using the Wilcoxon's signed rank test. Pearson's correlation coefficients were calculated for the range of mouth opening and the attenuation amount of the irradiation dose of the palate. A single regression analysis was performed with the range of mouth opening as the response variable and the attenuation amount of the irradiation dose of the palate as the explanatory variable. A p-value of < 0.05 was considered statistically significant. All statistical analyses were performed with EZR (Saitama Medical Center, Jichi Medical

University, Saitama, Japan), which is a graphical user interface for R (The R Foundation for Statistical Computing, Vienna, Austria). More precisely, it is a modified version of R Commander designed to add statistical functions frequently used in biostatistics¹⁹.

Results

Of the nine patients analyzed, two had T2 lesions, three had T3 lesions, and four had T4 lesions according to the TNM classification. Six patients underwent chemoradiotherapy (CRT) as a radical treatment, three patients received radiotherapy as postoperative therapy, and eight patients received chemotherapy. All patients completed CRT (Tab. 1). The median total irradiation dose to the tumor site in the oral cavity was 65.6 Gy. The range was 60–67.4 Gy.

The calculated irradiation doses for the palate are presented as medians [interquartile range (IQR)]. The irradiation doses for the palate were 1.6 (IQR: 1.1–2.2) Gy with the use of the positioning stent, and 37.2 (IQR: 17.5–44.1) Gy without the use of the positioning stent. The irradiation dose for the palate decreased when the stent was used in all cases. There was a statistically significant difference in the radiation dose to the palate with and without the use of the positioning stent ($p = 0.00195$) (Fig. 4).

The range of mouth opening was 19–37 (mean \pm SD: 26 \pm 5.6) mm. The attenuation amount of irradiation dose to the palate was 3.7–55.6 Gy. The attenuation rate of irradiation dose to the palate was 78.7–97%. There was a moderate correlation between the range of mouth opening and the attenuation amount of irradiation dose to the palate ($r = 0.673$, $p = 0.0467$). Regression equation was $y = 0.21x + 19$ (Fig. 5).

In all cases, palate and maxilla mucositis did not develop during the therapy period. However, oral mucositis did occasionally develop on the tongue and adjacent mandibular

gingiva. In the middle of the treatment, dietary intake data revealed that two patients had to change, whereas nine patients were able to continue oral intake throughout the treatment and all patients completed treatment. In all cases, CTCAE 5.0 was determined to be Grade 2.

Discussion

The irradiation dose required to cause the onset of oral mucositis in patients with tongue cancer has not been reported. However, radiotherapy for treatment of HNC, which includes the same stratified squamous epithelium as the tongue, causes harmful mucosal changes at 10 Gy [20]. It has also been reported that oral mucositis develops when the irradiation dose exceeds 15 Gy [9]. Therefore, to preserve healthy tissues during radiotherapy, it is necessary not to exceed 15 Gy.

Irradiation to healthy tissue decreases with the distance from the irradiation field. Therefore, the irradiation dose to healthy tissues, such as the maxilla and palate, can be attenuated by increasing the distance as much as possible. However, as the number of doses increases, the extent of mucositis will expand and make it difficult to maintain a large mouth opening during radiotherapy. In addition, nausea is also induced by anticancer drugs, and it is not always possible to perform radiotherapy with the maximum opening. In this study, we decided to examine the minimum range of mouth opening necessary to suppress oral mucositis on the palate induced by radiotherapy.

During radiotherapy for tongue cancer, oral mucositis on the adjacent floor of the mouth and mandibular gingiva is unavoidable, even when using a positioning stent, because the irradiation field will hit the tongue. In a previous study on patients with tongue and floor of mouth cancers, a significant difference was reported in the irradiation dose required for the maxilla when a positioning stent was used [16]. Therefore, to examine the ability of the

device to reduce the irradiation dose required, we also set the palate as the measurement point, which is surely excluded from the irradiation field by using the device.

Our analyses showed a moderate positive correlation between the range of mouth opening and the attenuation amount. This supports related findings that by increasing the range of mouth opening, the distance between the tongue and palate increases and the irradiation dose decreases [12–14]. However, because the irradiation field distributes concentrically with the tumor receiving the maximum dose and the dose diminishing to 0 Gy at the edge of the field, it suggests that the range of mouth opening does not reduce the intensity of the dose beyond the irradiation field.

There has been no standard for the range of mouth opening via the positioning stent in previous studies. For example, one stent was made to open mouths to 15 mm [16] and another to open mouths to 75% of every patient's maximum ability [15]. It has been reported that the average value for maximum opening in young people is 52.02 ± 5.09 mm and 51.61 ± 8.14 mm [21, 22]. To open mouths to 75% of these maxima, a device would have to be fabricated to maintain a range of mouth opening of about 35 mm. There has been no basis reported for determining the range of mouth opening in other literature.

From the results of this study, the regression equation with the range of mouth opening as the response variable and the attenuation amount of the irradiation dose of the palate as the explanatory variable was $y = 0.21x + 19$. If the irradiation doses for the palate without the positioning stent are calculated by the pre-irradiation simulation, the attenuation amount to 15 Gy which lower risk of developing oral mucositis can also be determined. Once, the attenuation amount required to prevent the development of oral mucositis is known, the regression equation obtained in this study can be used to derive the required range of mouth opening. This may be useful for patients who have difficulty in opening their mouths.

Because a positioning stent was used for all patients in our hospital, it was not possible to have a true control group (a group in which no positioning stent was used). Therefore, we could not clinically evaluate the effect of wearing a positioning stent on the incidence of radiation-induced oral mucositis. Hence, we compared our irradiation dose for the palate while using the device against irradiation doses for the maxilla without the use of the device, as reported in previous studies. In a study investigating whether this oral device attenuates the irradiation dose to healthy tissues in patients with tongue and floor of mouth cancers, the maximum irradiation dose without using the device was determined to be 35.8 ± 21.1 Gy [16]. This was significantly more than what we observed, as the palatal irradiation dose when using the device was 0.4–9.6 Gy [median (IQR): 1.6 (1.1–2.2) Gy], which was lower than that observed without the use of the positioning stent.

All nine patients completed treatment and were able to continue oral intake at the end of the treatment. To date, to the best of our knowledge, no previous study has examined oral intake during radiation therapy without the use of an oral device. In this study, the range of oral mucositis was reduced by the use of the device, and oral intake was considered possible during the treatment period. Based on that, it is considered that the use of the positioning stent played a significant role in the management of oral mucositis and oral intake during radiotherapy.

There are several limitations in this study. Firstly, the total number of participants in this study was relatively low. Since this study is a retrospective study, the number of subjects could not be increased. Secondly, the measured value in the palate was not the real value in the oral cavity, but the predictive value measured by the simulation calculated it by superimposing the treatment plan for each patient on each CT image for this study. Nevertheless, the range of mouth opening obtained in this study is a useful finding in the

prevention of oral mucositis of the palate in tongue cancer.

The use of IMRT for treating HNC has been increasing in recent years. The positioning stent can be applied in IMRT because it not only stays in place and depresses the tongue during the radiotherapy but also separates healthy and malignant tissues for the ease of RTP. Future research is needed to consider the appropriate range of mouth opening when using a positioning stent in IMRT.

Conclusion

In our study, the regression equation with the range of mouth opening as the response variable and the attenuation amount of the irradiation dose of the palate as the explanatory variable was $y = 0.21x + 19$.

It was suggested that if the attenuation amount of the palate could be calculated by the pre-irradiation simulation, the required range of minimum mouth opening for the positioning stent to prevent oral mucositis on the palate induced by radiotherapy could be sought.

Acknowledgements

The authors would like to thank Mr. Takehide Onishi of the Division of Oral and Maxillofacial Surgery, Tokyo Dental College, Ichikawa General Hospital and Mr. Yasuyuki Yamasaki of the Department of Radiology, Tokyo Dental College, Ichikawa General Hospital, and Dr. Yutaka Aoyagi of the Department of Radiology, JR Tokyo General Hospital for their invaluable support in these experiments.

Conflicts of interest

The authors declare no conflict of interest in this study.

Funding

None declared

References

1. Pignon JP, Bourhis J, Domenge C, et al. Chemotherapy added to locoregional treatment for head and neck squamous-cell carcinoma: three meta-analyses of updated individual data. *Lancet*. 2000; 355(9208): 949–955, doi: [10.1016/s0140-6736\(00\)90011-4](https://doi.org/10.1016/s0140-6736(00)90011-4), indexed in Pubmed: [10768432](https://pubmed.ncbi.nlm.nih.gov/10768432/).
2. Soo KC, Tan EH, Wee J, et al. Surgery and adjuvant radiotherapy vs concurrent chemoradiotherapy in stage III/IV nonmetastatic squamous cell head and neck cancer: a randomised comparison. *Br J Cancer*. 2005; 93(3): 279–286, doi: [10.1038/sj.bjc.6602696](https://doi.org/10.1038/sj.bjc.6602696), indexed in Pubmed: [16012523](https://pubmed.ncbi.nlm.nih.gov/16012523/).
3. Adelstein DJ, Li Yi, Adams GL, et al. An intergroup phase III comparison of standard radiation therapy and two schedules of concurrent chemoradiotherapy in patients with unresectable squamous cell head and neck cancer. *J Clin Oncol*. 2003; 21(1): 92–98, doi: [10.1200/JCO.2003.01.008](https://doi.org/10.1200/JCO.2003.01.008), indexed in Pubmed: [12506176](https://pubmed.ncbi.nlm.nih.gov/12506176/).
4. Wendt TG, Grabenbauer GG, Rödel CM, et al. Simultaneous radiochemotherapy versus radiotherapy alone in advanced head and neck cancer: a randomized multicenter study. *J Clin Oncol*. 1998; 16(4): 1318–1324, doi: [10.1200/JCO.1998.16.4.1318](https://doi.org/10.1200/JCO.1998.16.4.1318), indexed in Pubmed: [9552032](https://pubmed.ncbi.nlm.nih.gov/9552032/).
5. Browman GP, Hodson DI, Mackenzie RJ, et al. Cancer Care Ontario Practice Guideline Initiative Head and Neck Cancer Disease Site Group. Choosing a concomitant chemotherapy and radiotherapy regimen for squamous cell head and neck cancer: A systematic review of the published literature with subgroup analysis. *Head Neck*. 2001; 23(7): 579–589, doi: [10.1002/hed.1081](https://doi.org/10.1002/hed.1081), indexed in Pubmed: [11400247](https://pubmed.ncbi.nlm.nih.gov/11400247/).
6. Argiris A, Karamouzis M, Raben D, et al. Head and neck cancer. *Lancet*. 2008; 371(9625): 1695–1709, doi: [10.1016/s0140-6736\(08\)60728-x](https://doi.org/10.1016/s0140-6736(08)60728-x), indexed in Pubmed: [18486742](https://pubmed.ncbi.nlm.nih.gov/18486742/).
7. Vissink A, Mitchell JB, Baum BJ, et al. Prevention and treatment of the consequences of head and neck radiotherapy. *Crit Rev Oral Biol Med*. 2003; 14(3): 213–225, doi: [10.1177/154411130301400306](https://doi.org/10.1177/154411130301400306), indexed in Pubmed: [12799324](https://pubmed.ncbi.nlm.nih.gov/12799324/).
8. Trotti A, Bellm LA, Epstein JB, et al. Mucositis incidence, severity and associated outcomes in patients with head and neck cancer receiving radiotherapy with or without chemotherapy: a systematic literature review. *Radiother Oncol*. 2003; 66(3): 253–262, doi: [10.1016/s0167-8140\(02\)00404-8](https://doi.org/10.1016/s0167-8140(02)00404-8), indexed in Pubmed: [12742264](https://pubmed.ncbi.nlm.nih.gov/12742264/).
9. Raber-Durlacher J, Elad S, Barasch A. Oral mucositis. *Oral Oncology*. 2010; 46(6): 452–456, doi: [10.1016/j.oraloncology.2010.03.012](https://doi.org/10.1016/j.oraloncology.2010.03.012).

10. Sroussi HY, Epstein JB, Bensadoun RJ, et al. Common oral complications of head and neck cancer radiation therapy: mucositis, infections, saliva change, fibrosis, sensory dysfunctions, dental caries, periodontal disease, and osteoradionecrosis. *Cancer Med.* 2017; 6(12): 2918–2931, doi: [10.1002/cam4.1221](https://doi.org/10.1002/cam4.1221), indexed in Pubmed: [29071801](https://pubmed.ncbi.nlm.nih.gov/29071801/).
11. Lalla RV, Saunders DP, Peterson DE. Chemotherapy or radiation-induced oral mucositis. *Dent Clin North Am.* 2014; 58(2): 341–349, doi: [10.1016/j.cden.2013.12.005](https://doi.org/10.1016/j.cden.2013.12.005), indexed in Pubmed: [24655526](https://pubmed.ncbi.nlm.nih.gov/24655526/).
12. Chen D, Chen X, Chen X, et al. The efficacy of positioning stents in preventing Oral complications after head and neck radiotherapy: a systematic literature review. *Radiat Oncol.* 2020; 15(1): 90, doi: [10.1186/s13014-020-01536-0](https://doi.org/10.1186/s13014-020-01536-0), indexed in Pubmed: [32345309](https://pubmed.ncbi.nlm.nih.gov/32345309/).
13. Beumer III J, Marunick MT, Esposito SJ. *Maxillofacial Rehabilitation. Vol. III.* Quintessence Publishing Co, Inc, Chicago 2011.
14. Goel A, Tripathi A, Chand P, et al. Use of positioning stents in lingual carcinoma patients subjected to radiotherapy. *Int J Prosthodont.* 2010; 23(5): 450–452, indexed in Pubmed: [20859562](https://pubmed.ncbi.nlm.nih.gov/20859562/).
15. Nayar S, Brett R, Clayton N, et al. The Effect of a radiation positioning stent (RPS) in the reduction of a radiation dosage to the opposing jaw and maintenance of mouth opening after radiation therapy. *Eur J Prosthodont Restorative Dent.* 2016; 24(2): 71–7, doi: [10.1922/EJPRD_00005Nayar07](https://doi.org/10.1922/EJPRD_00005Nayar07), indexed in Pubmed: [27424338](https://pubmed.ncbi.nlm.nih.gov/27424338/).
16. Verrone JR, Alves FA, Prado JD, et al. Benefits of an intraoral stent in decreasing the irradiation dose to oral healthy tissue: dosimetric and clinical features. *Oral Surg Oral Med Oral Pathol Oral Radiol.* 2014; 118(5): 573–578, doi: [10.1016/j.oooo.2014.08.008](https://doi.org/10.1016/j.oooo.2014.08.008), indexed in Pubmed: [25442494](https://pubmed.ncbi.nlm.nih.gov/25442494/).
17. Japanese Society for Radiation Oncology, Radiation treatment planning guidelines; 2016. <https://www.jastro.or.jp/medicalpersonnel/guideline/jastro/2016.html> (02/12/2020).
18. Kamijo Y. [Oral Anatomy]. Vol. 2. 3rd ed. Anatome Publishing Co, Tokyo 1997: 258.
19. Kanda Y. Investigation of the freely available easy-to-use software 'EZR' for medical statistics. *Bone Marrow Transplant.* 2013; 48(3): 452–458, doi: [10.1038/bmt.2012.244](https://doi.org/10.1038/bmt.2012.244), indexed in Pubmed: [23208313](https://pubmed.ncbi.nlm.nih.gov/23208313/).
20. Stephen TS. Pathobiology of oral mucositis: novel insights and opportunities. *J Support Oncol.* 2007; 5(9): 3–11, indexed in Pubmed: [18046993](https://pubmed.ncbi.nlm.nih.gov/18046993/).
21. Li XY, Jia C, Zhang ZC. The normal range of maximum mouth opening and its correlation with height or weight in the young adult Chinese population. *J Dent Sci.* 2017; 12(1): 56–59, doi: [10.1016/j.jds.2016.09.002](https://doi.org/10.1016/j.jds.2016.09.002), indexed in Pubmed: [30895024](https://pubmed.ncbi.nlm.nih.gov/30895024/).

22. Gbolahan OO, Osinaike BB, Udoye CI, et al. Range of mouth opening among three major ethnic groups in Nigeria. *Ann Ib Postgrad Med.* 2019; 17(2): 130-137, indexed in Pubmed: [32669989](https://pubmed.ncbi.nlm.nih.gov/32669989/).

Table 1. Clinical characteristics of study patients with tongue cancer

Variable	Number
Gender	
Male	5
Female	4
T Stage	
T2	2
T3	3
T4	4
N Stage	
N0	3
N1	2
N2	4
N3	0
Chemotherapy	
No chemotherapy	1
Tegafur/Gimeracil/Oteracil (oral administration)	1
Cisplatin (intravenous drip)	2
Cisplatin (superselective intra-arterial infusion)	5
Irradiation policy	
Radical irradiation	6
Postoperative irradiation	3
Nutrient intake status	
Ingested nutrients orally	9
Relied on tube feeding	0
CTCAE	
Grade 2	9

CTCAE — Common Terminology Criteria for Adverse Events

Figure 1. Positioning stent on an articulator

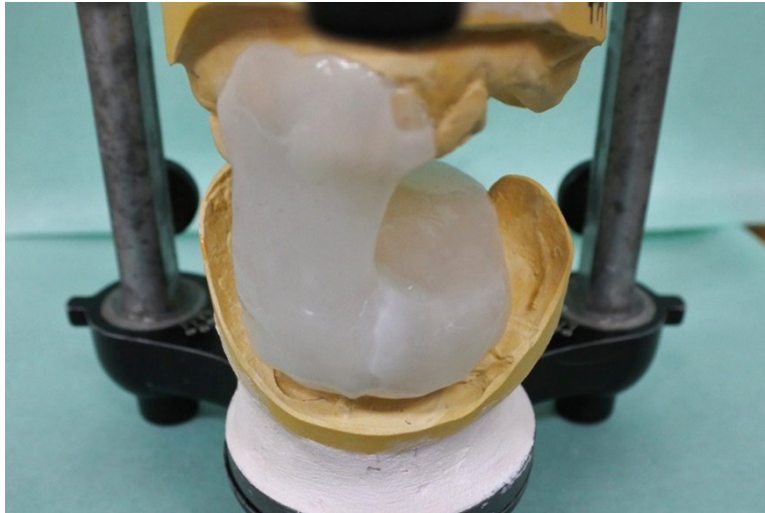


Figure 2. Flow diagram for subject selection

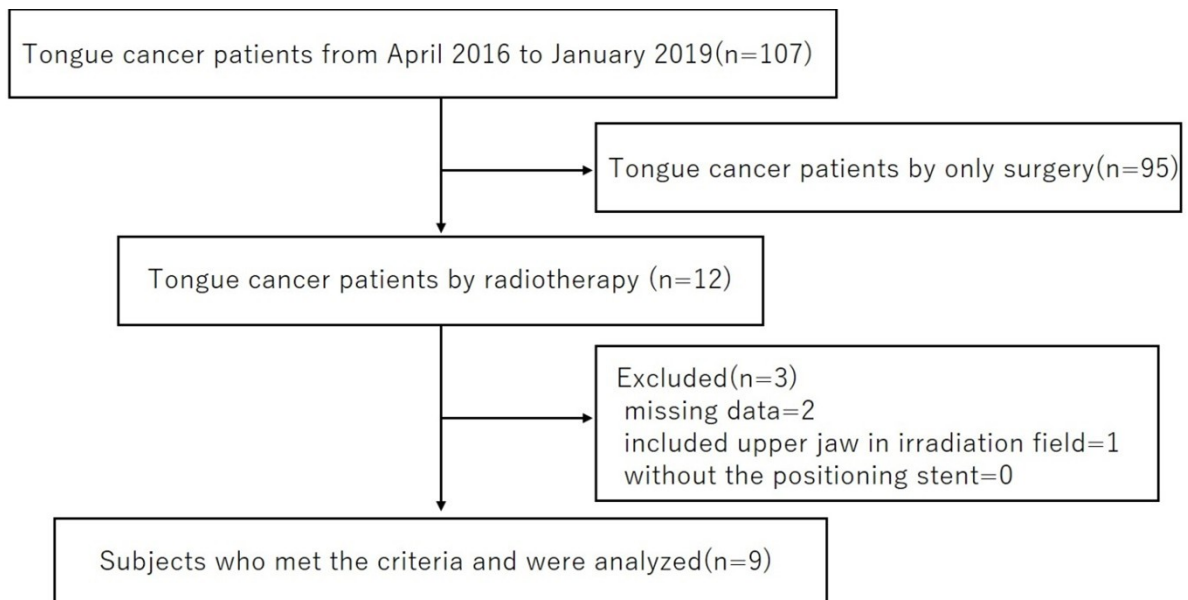


Figure 3. Computed tomography (CT) image for a treatment plan with a positioning stent attached. Each color and line represents the volume of the tumor and distribution of the dose, respectively. The red section is the gross tumor volume (GTV) on CT image (R); the blue section is the GTV on magnetic resonance imaging (MRI) (B); the dark purple line is the clinical tumor volume (CTV); the blue line is the planning target volume (PTV). The dose distribution map lies outside the lines and shows that the irradiation dose decreases as the distance from PTV increases (light green: 98%, yellow: 95%, light blue: 90%)

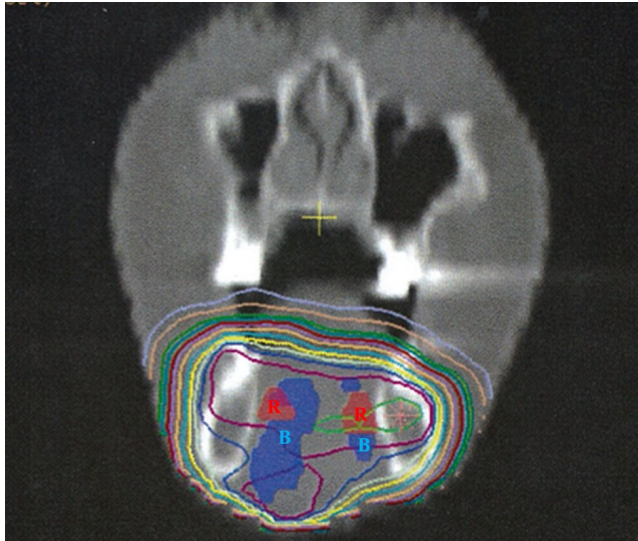


Figure 4. Irradiation dose on the palate with and without the use of the positioning stent

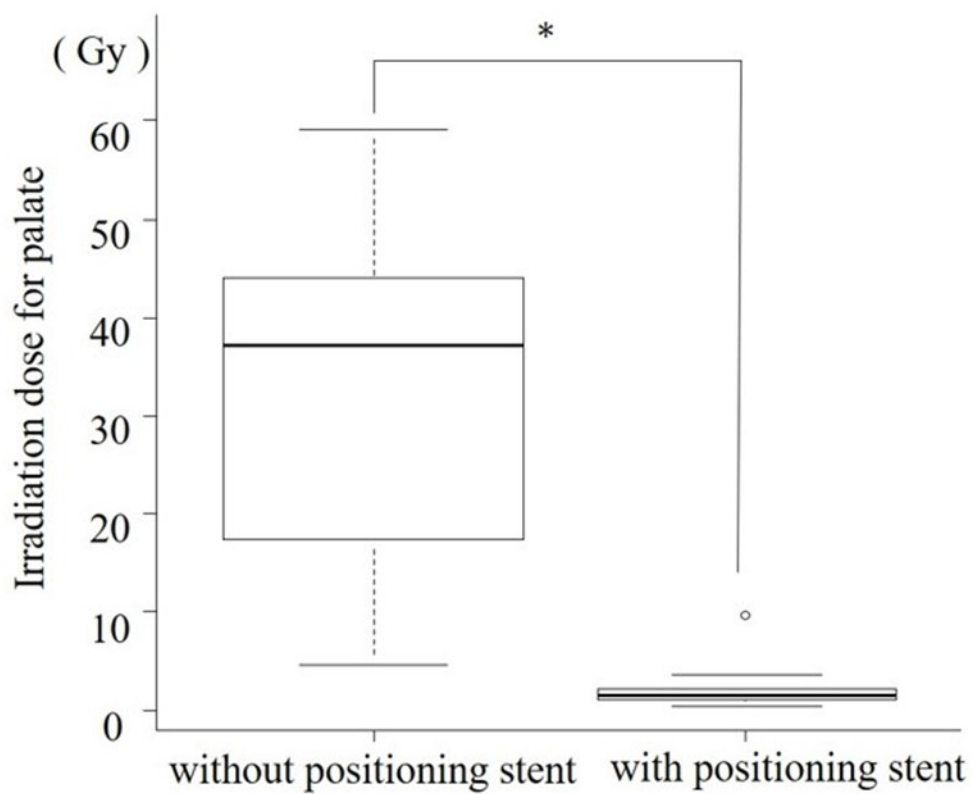


Figure 5. Diagram showing the moderate correlation between the range of mouth opening and the attenuation amount of irradiation dose to the palate ($r = 0.673$, $p = 0.0467$).

Regression equation was $y = 0.21x + 19$

