



## **Non-sustained ventricular tachycardia due to extreme road traffic stress in a healthy adult**

**Authors:** Wojciech Skorupski, Marek Grygier, Maciej Lesiak, Przemysław Mitkowski

**Article type:** Clinical vignette

**Received:** June 11, 2022

**Accepted:** August 29, 2022

**Early publication date:** October 27, 2022

This article is available in open access under Creative Common Attribution-Non-Commercial-No Derivatives 4.0 International (CC BY-NC-ND 4.0) license, allowing to download articles and share them with others as long as they credit the authors and the publisher, but without permission to change them in any way or use them commercially.

## **Non-sustained ventricular tachycardia due to extreme road traffic stress in a healthy adult**

**Short title:** Non-sustained ventricular tachycardia due to extreme stress

Wojciech Skorupski, Marek Grygier, Maciej Lesiak, Przemysław Mitkowski

1<sup>st</sup> Department of Cardiology, Poznan University of Medical Sciences, Poznań, Poland

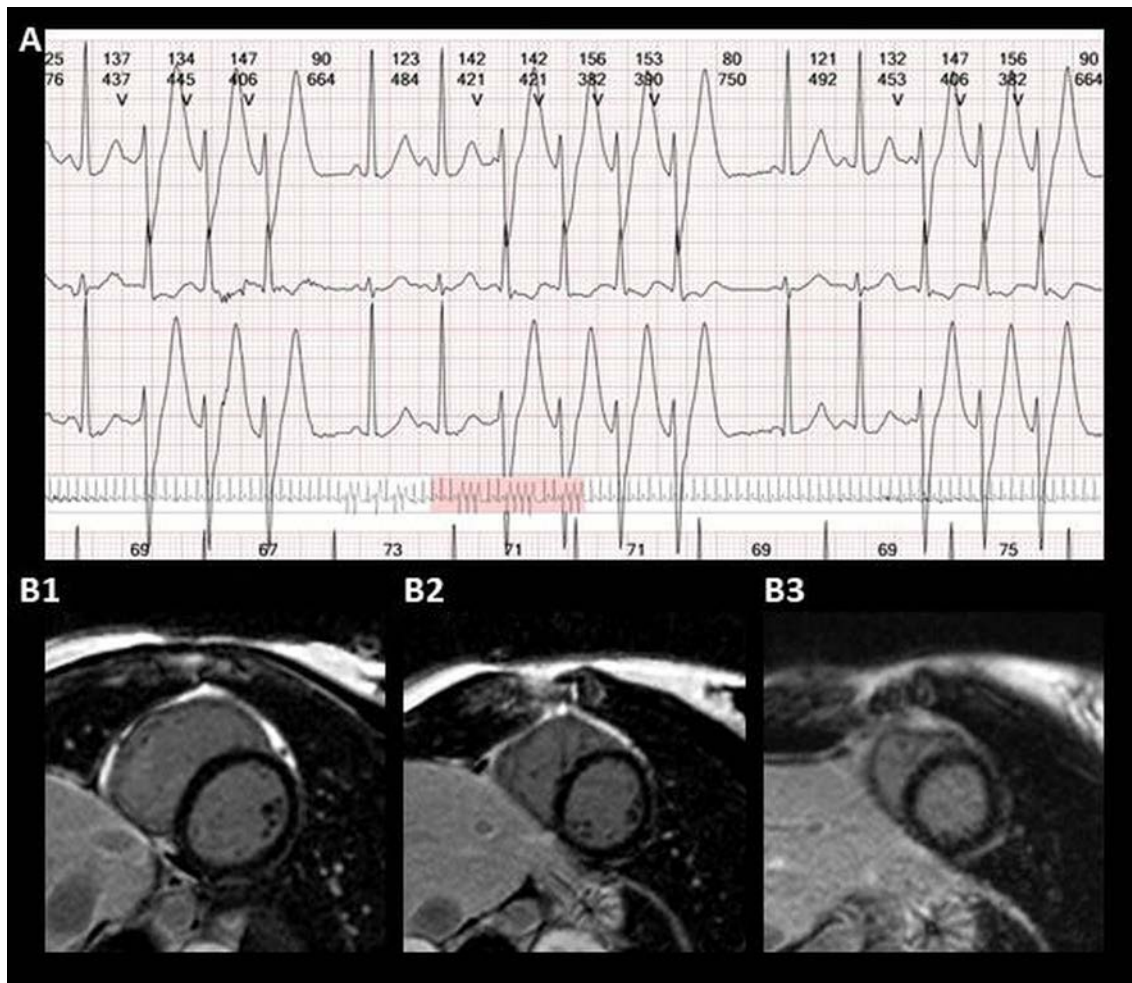
### **Correspondence to:**

Wojciech Skorupski, MD,  
1<sup>st</sup> Department of Cardiology,  
Poznań University of Medical Sciences,  
Długa 1/2, 61–848 Poznań,  
phone: +48 61 854 92 22,  
e-mail: wojtek.skorupski@wp.pl

Episodes of extreme emotional stress can have significant adverse effects on the heart. The incidence of sudden cardiac death increases in populations who experience disasters such as earthquakes or wars [1]. The physiological connection between mental stress and sudden cardiac death is not clear; one mechanism may be the direct effect of adrenergic stimulation on arrhythmias. Ventricular tachycardia (VT), and sudden cardiac death are more common in the morning, during the peak catecholamine levels and lowest vagal tone [2]. Negative emotions such as anger, anxiety and sadness may accelerate ventricular arrhythmias and myocardial infarction [3]. Acute emotional stress can produce left ventricular contractile dysfunction, myocardial ischemia, or disturbances of cardiac rhythm [4]. Although these abnormalities are often reversible, their consequences can be very harmful or in the worst case scenario — fatal. A previously healthy 24-year-old woman referred for the cardiological consultation because of non-specific chest discomfort. She did not have any risk factors for cardiovascular diseases. Blood tests, including the thyroid hormone levels were normal. She did not take any drugs. Non-invasive diagnostic examination protocol was introduced. ECG was normal, sinus rhythm of 75 beats per minute (bpm). Echocardiography showed no abnormalities and stress test confirmed good physical capacity. Finally, ambulatory 24 hour ECG Holter monitoring was implemented. Right after monitoring started, on the way back home, the patient almost caused

a fatal traffic accident . She did not notice the pedestrian crossing the lanes, who was stunned by the life-threatening situation, watched and froze in front of the patient's car. The patient avoided car accident and stopped the car at the last moment, right in front of the pedestrian's body. At this exact point, Holter recorded 3 episodes of non-sustained VT (NSVT) (3-4 ventricular beats) and the patient experienced cardiac palpitations unlike any other in her life (Figure 1A). After this surprising ECG recording, a control 72-hour Holter ECG was performed and this examination presented 0 ventricular extrasystoles. Aftermath cardiac magnetic resonance was implemented to confirm no uncommon congenital cardiac defects or myocarditis (Figure 1B1–1B3). The final decision on a strictly stressful cause without the need for invasive electrophysiology procedure or any treatment initiation was made.

According to the best of our knowledge, this is the first report of the healthy human being to present NSVT due to extreme stress. Our case documents that extreme short-term severe stress can induce severe cardiac arrhythmias. In patients with cardiac diseases, such arrhythmias can be life-threatening. The frequency of this phenomenon is unknown. Holter monitoring could in rare accidental conditions put the light into pathomechanism of stress/injury-arrhythmia-severe outcome pathway [5]. After an exclusion of organic heart disease previously symptoms presented by the patient prone to neurosis diagnosis and perhaps this subgroup of patients is more exposed to such incidents. Moreover, in our case NSVT episode was particularly short (3-4 ventricular beats). According to the guidelines there are currently no indication for the treatment of such cases.



**Figure 1. A.** 24 hour ECG Holter monitoring — episodes of non-sustained ventricular tachycardia. **B1–B3.** Cardiac magnetic resonance – no abnormalities

## REFERENCE

1. Leor J, Poole WK, Kloner RA. Sudden cardiac death triggered by an earthquake. *N Engl J Med.* 1996; 334(7): 413–419, doi: [10.1056/NEJM199602153340701](https://doi.org/10.1056/NEJM199602153340701), indexed in Pubmed: [8552142](https://pubmed.ncbi.nlm.nih.gov/8552142/).
2. Huikuri HV, Niemelä MJ, Ojala S, et al. Circadian rhythms of frequency domain measures of heart rate variability in healthy subjects and patients with coronary artery disease. Effects of arousal and upright posture. *Circulation.* 1994; 90(1): 121–126, doi: [10.1161/01.cir.90.1.121](https://doi.org/10.1161/01.cir.90.1.121), indexed in Pubmed: [8025987](https://pubmed.ncbi.nlm.nih.gov/8025987/).
3. Lampert R, Joska T, Burg MM, et al. Emotional and physical precipitants of ventricular arrhythmia. *Circulation.* 2002; 106(14): 1800–1805, doi: [10.1161/01.cir.0000031733.51374.c1](https://doi.org/10.1161/01.cir.0000031733.51374.c1), indexed in Pubmed: [12356633](https://pubmed.ncbi.nlm.nih.gov/12356633/).

4. Lampert R, Jain D, Burg MM, et al. Destabilizing effects of mental stress on ventricular arrhythmias in patients with implantable cardioverter-defibrillators. *Circulation*. 2000; 101(2): 158–164, doi: [10.1161/01.cir.101.2.158](https://doi.org/10.1161/01.cir.101.2.158), indexed in Pubmed: [10637203](https://pubmed.ncbi.nlm.nih.gov/10637203/).
5. Marcinkiewicz K, Baranowski R. Death recorded by Holter monitoring due to multiple traumatic injuries as a consequence of a car accident. *Kardiol Pol*. 2020; 78(12): 1301–1303, doi: [10.33963/KP.15702](https://doi.org/10.33963/KP.15702), indexed in Pubmed: [33293498](https://pubmed.ncbi.nlm.nih.gov/33293498/).