

This is a provisional PDF only. Copyedited and fully formatted version will be made available soon.



CARDIOLOGY
JOURNAL

ISSN: 1897-5593
e-ISSN: 1898-018X

Laser speckle contrast imaging to assess microcirculation

Authors: Marcin Hellmann, Leszek Kalinowski, Jean-Luc Cracowski

DOI: 10.5603/CJ.a2022.0097

Article type: Technology Note

Submitted: 2022-09-09

Accepted: 2022-10-19

Published online: 2022-10-27

This article has been peer reviewed and published immediately upon acceptance.
It is an open access article, which means that it can be downloaded, printed, and distributed freely,
provided the work is properly cited.
Articles in "Cardiology Journal" are listed in PubMed.

Laser speckle contrast imaging to assess microcirculation

Marcin Hellmann et al., Laser speckle to assess microcirculation

Marcin Hellmann¹, Leszek Kalinowski^{2,3}, Jean-Luc Cracowski⁴

¹Department of Cardiac Diagnostics, Medical University of Gdansk, Poland

²Department of Medical Laboratory Diagnostics-Fahrenheit Biobank BBMRI.pl, Medical University of Gdansk, Poland

³BioTechMed Center, Department of Mechanics of Materials and Structures, Gdansk University of Technology, Gdansk, Poland

⁴Grenoble-Alpes University, Inserm, UMR1300, HP2, Grenoble, France

Address for correspondence: Prof. Marcin Hellmann, MD, PhD, Department of Cardiac Diagnostics, Medical University, ul. Smoluchowskiego 17, 80-214 Gdańsk, Poland, tel: + 48 58 349 33 80, fax: + 48 58 349 33 79, e-mail: marcin.hellmann@gmail.com

Microcirculation plays a crucial role in tissue oxygenation and nutrient supply. Indeed, microvascular dysfunction may precede endothelial impairment in large arteries and clinical manifestations. It is becoming apparent that microcirculation is essentially involved in a variety of pathological conditions, and that microvascular dysfunction may be a biomarker in the development of cardiovascular disease [1]. Recently, accumulating evidence suggests that coronavirus disease 2019 (COVID-19) should be considered as a systemic microvascular endothelial disease with different clinical manifestations from severe and acute to completely asymptomatic course [2]. Hence, non-invasive and reliable methods for microcirculation status monitoring are still strongly needed.

Several methods are available to study the human microcirculation and to quantify microvascular blood flow. Among them, the recent non-invasive laser speckle contrast imaging (LSCI) provides a real-time monitoring of microvascular perfusion. Using LSCI, we showed that topical administration of treprostinil, a prostacyclin analog, increases cutaneous microvascular blood flow in diabetic patients [3]. Indeed, LSCI enables a precise

quantification of variations of skin blood flow in two-dimension. LSCI measurements coupled with acetylcholine and sodium nitroprusside iontophoresis showed that for both agents the vasodilatation is reduced in early-onset coronary artery disease patients suggesting concurrent endothelial-dependent and -independent skin microvascular dysfunction [4]. Taken together, in clinical studies, LSCI is mainly used to assess skin microcirculation (Fig. 1) [5]. However, quite recently, LSCI was applied intraoperatively to estimate parathyroid viability [6]. Using two-dimensional LSCI, we recently performed non-invasive real-time microcirculation imaging on the beating heart (Fig. 2) in a patient undergoing coronary artery bypass grafting surgery [7].

Laser speckle contrast imaging is a recently developed technique based on speckle contrast analysis that provides an index of blood flow. When motionless tissue is illuminated with a laser, a random interference pattern, or speckle, is observed independent of the structure of the tissue surface. Speckle contrast is calculated as the ratio of its standard deviation to its mean intensity. When the laser light is scattered by moving red blood cells, the speckle pattern decorrelates. LSCI is based on the two-dimensional quantification of variations in this speckle contrast. Due to the movement of red blood cells, each single speckle intensity will fluctuate as a function of their velocity, and the time-integrated speckle contrast will be reduced. The penetration depth of LSCI measurements is about 300 μm , whereas it is deeper (about 1–1.5 mm) with laser Doppler techniques. Therefore, LSCI mostly records blood flow in the skin's superficial papillary plexus while laser Doppler techniques record deeper dermal blood flow [8].

Laser speckle contrast imaging does not provide an exact measure of flow (mL/min). Measurements are therefore often expressed as arbitrary perfusion units (PU) or as cutaneous vascular conductance, which is flux divided by mean arterial pressure. The latter approach is more physiological as it takes into account differences and variations in blood pressure. Importantly, LSCI measurements can be carried out continuously, but are sensitive to movement artefacts.

In summary, LSCI allows non-invasive real-time monitoring of peripheral microcirculatory perfusion on a wide area of tissue with a very good spatial and temporal resolution and an excellent reproducibility. Therefore, LSCI combines the advantages of laser Doppler flowmetry and laser Doppler imaging [9]. As mentioned above, LSCI is mainly used in clinical studies to assess skin microcirculation [5]. However, LSCI is also successfully applied to animal studies and angiogenesis measurements [10].

A number of common clinical conditions are closely associated with microvascular dysfunction. The monitoring of the microvascular perfusion is therefore of essential interest in various experimental and clinical studies. Laser speckle contrast imaging measurements are reproducible and highly sensitive to acute changes in tissue perfusion. Of note, this technique coupled with vascular reactivity tests enables assessment of endothelial function. Additionally, LSCI can be easily applied in pharmacological studies aimed at assessing drug safety, efficacy and influence on microcirculation in cardiovascular diseases [3].

Conflict of interest: None declared

References

1. Hellmann M, Roustit M, Cracowski JL. Skin microvascular endothelial function as a biomarker in cardiovascular diseases? *Pharmacol Rep.* 2015; 67(4): 803–810, doi: [10.1016/j.pharep.2015.05.008](https://doi.org/10.1016/j.pharep.2015.05.008), indexed in Pubmed: [26321284](https://pubmed.ncbi.nlm.nih.gov/26321284/).
2. Gasecka A, Pruc M, Kukula K, et al. Post-COVID-19 heart syndrome. *Cardiol J.* 2021; 28(2): 353–354, doi: [10.5603/CJ.a2021.0028](https://doi.org/10.5603/CJ.a2021.0028), indexed in Pubmed: [33645626](https://pubmed.ncbi.nlm.nih.gov/33645626/).
3. Hellmann M, Roustit M, Gaillard-Bigot F, et al. Cutaneous iontophoresis of treprostinil, a prostacyclin analog, increases microvascular blood flux in diabetic malleolus area. *Eur J Pharmacol.* 2015; 758: 123–128, doi: [10.1016/j.ejphar.2015.03.066](https://doi.org/10.1016/j.ejphar.2015.03.066), indexed in Pubmed: [25843412](https://pubmed.ncbi.nlm.nih.gov/25843412/).
4. Souza EG, De Lorenzo A, Huguenin G, et al. Impairment of systemic microvascular endothelial and smooth muscle function in individuals with early-onset coronary artery disease: studies with laser speckle contrast imaging. *Coron Artery Dis.* 2014; 25(1): 23–28, doi: [10.1097/MCA.0000000000000055](https://doi.org/10.1097/MCA.0000000000000055), indexed in Pubmed: [24172594](https://pubmed.ncbi.nlm.nih.gov/24172594/).
5. Cracowski JL, Roustit M. Current methods to assess human cutaneous blood flow: an updated focus on laser-based-techniques. *Microcirculation.* 2016; 23(5): 337–344, doi: [10.1111/micc.12257](https://doi.org/10.1111/micc.12257), indexed in Pubmed: [26607042](https://pubmed.ncbi.nlm.nih.gov/26607042/).
6. Mannoh EA, Thomas G, Solórzano CC, et al. Intraoperative assessment of parathyroid viability using laser speckle contrast imaging. *Sci Rep.* 2017; 7(1): 14798, doi: [10.1038/s41598-017-14941-5](https://doi.org/10.1038/s41598-017-14941-5), indexed in Pubmed: [29093531](https://pubmed.ncbi.nlm.nih.gov/29093531/).
7. Łoś A, Hellmann M. Real-time microcirculation imaging during beating-heart coronary artery bypass grafting. *Kardiol Pol.* 2020; 78(7-8): 780–781, doi: [10.33963/KP.15322](https://doi.org/10.33963/KP.15322), indexed in Pubmed: [32347087](https://pubmed.ncbi.nlm.nih.gov/32347087/).
8. Briers D, Duncan D, Hirst E, et al. Laser speckle contrast imaging: theoretical and practical limitations. *J Biomed Opt.* 2013; 18(6): 066018, doi: [10.1117/1.jbo.18.6.066018](https://doi.org/10.1117/1.jbo.18.6.066018).
9. Roustit M, Millet C, Blaise S, et al. Excellent reproducibility of laser speckle contrast imaging to assess skin microvascular reactivity. *Microvasc Res.* 2010; 80(3): 505–511, doi: [10.1016/j.mvr.2010.05.012](https://doi.org/10.1016/j.mvr.2010.05.012), indexed in Pubmed: [20542492](https://pubmed.ncbi.nlm.nih.gov/20542492/).

10. Kuri PM, Pion E, Mahl L, et al. Deep learning-based image analysis for the quantification of tumor-induced angiogenesis in the 3D in vivo tumor model-establishment and addition to laser speckle contrast imaging (LSCI). *Cells*. 2022; 11(15), doi: [10.3390/cells11152321](https://doi.org/10.3390/cells11152321), indexed in Pubmed: [35954165](https://pubmed.ncbi.nlm.nih.gov/35954165/).

Figure 1. Skin microvascular perfusion on laser speckle contrast imaging with colours ranging from blue (low perfusion) to red (high perfusion).

Figure 2. Dynamic two-dimensional microvascular quantification during coronary artery bypass grafting surgery by laser speckle contrast imaging. The blue part corresponds to the myocardial tissue stabilizer (Octopus) used during beating heart surgery.

Image: 82 Time: 00:00:05.100

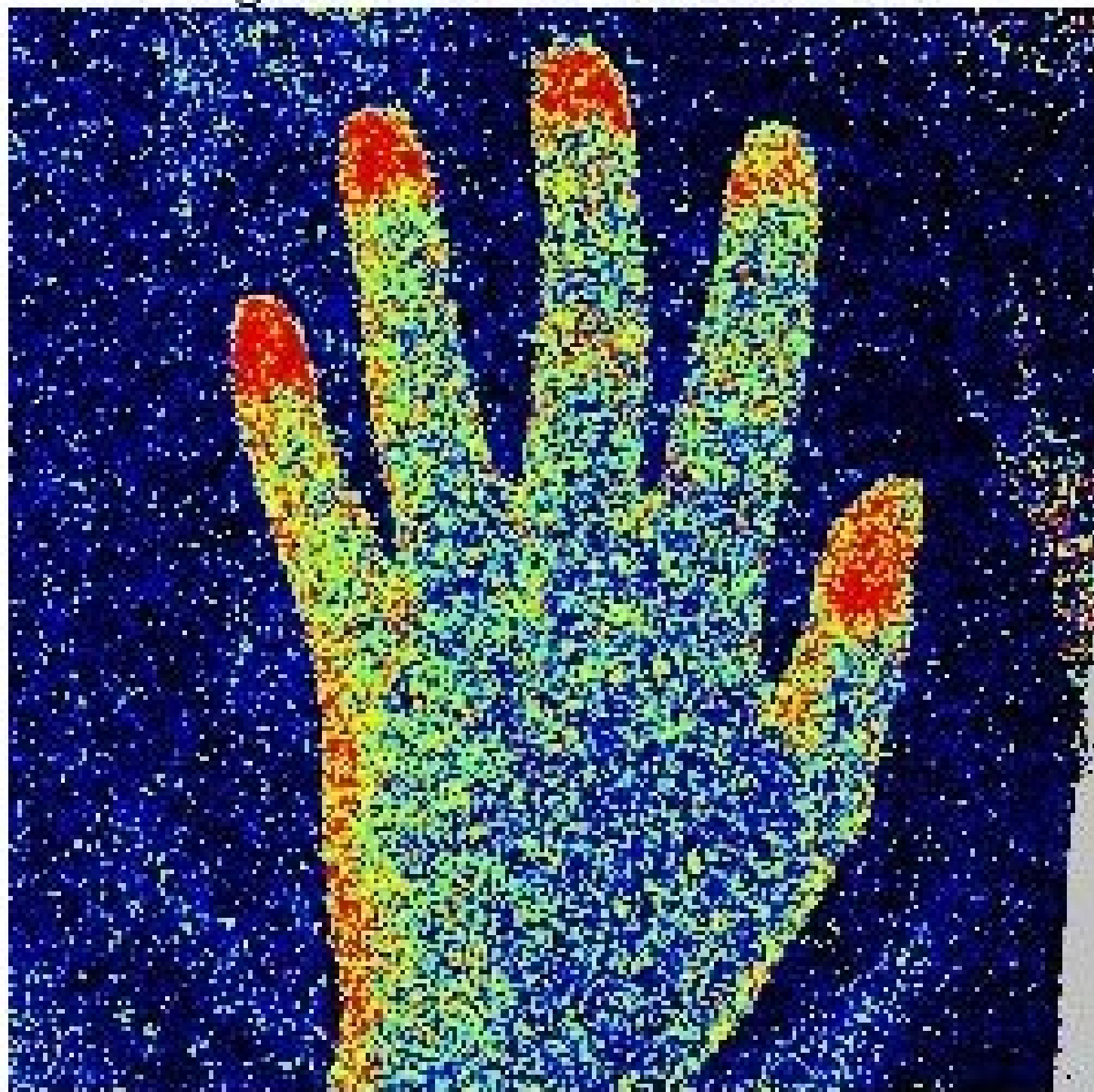


Image: 727 Time: 00:02:53.486

