

pISSN 1978-2071
 eISSN 2580-5967
 Jurnal Ilmiah Kedokteran
 Wijaya Kusuma (JIKW)
 Volume 11, No. 2 September
 2022

AUTHOR'S AFFILIATIONS

General Surgeon, RSUD Dr.
 Wahidin Sudiro Husodo Kota
 Mojokerto¹
 Neurosurgeon, RSUD Dr.
 Wahidin Sudiro Husodo Kota
 Mojokerto²
 Pediatrician, RSUD Dr. Wahidin
 Sudiro Husodo Kota Mojokerto³

CORRESPONDING AUTHOR

Arif Kusumo Rahardjo
 RSUD Dr. Wahidin Sudiro
 Husodo Kota Mojokerto
E-mail:
akusumo2015@gmail.com

Received: 6 June 2021;
 Accepted: 25 July 2022;
 Published: 30 September 2022

**Peritoneal Shunt Extraction in Children Using
 Laparoscopy: A Case Report**

Arif Kusumo Rahardjo^{1*}, Yusuf Hermawan², Vita Dwi Wijayanti³

Abstract

Laparoscopy is one way to perform various simple procedures or surgeries in the abdominal cavity. Laparoscopy can be useful in the management of ventriculo-peritoneal shunt (VP Shunt) fractures. The peritoneal component of the shunt remaining in the abdominal cavity can be removed using laparoscopy. A pediatric patient with hydrocephalus with a history of VP Shunt insertion 5 years ago, came with complaints of weakness, vomiting and difficulty eating. Physical examination revealed the presence of edema in the chamber area. A CT scan of the head and plain abdominal radiographs were performed. The diagnosis was made as a shunt fracture, with the peritoneal component of the shunt remaining in the abdominal cavity. The patient received treatment in the form of a revised VP shunt and peritoneal shunt extraction using standard laparoscopy which is commonly used for adult patients. The patient's condition improved after the procedure. Peritoneal shunt extraction in cases of VP shunt fracture can be safely performed using laparoscopy. If there are limited tools, this procedure can still be performed on children using standard laparoscopy which is usually used for adult patients. Authors report this case due to no previous report in Mojokerto area were known.

Keywords: extraction, shunt fracture, laparoscopy, case report, ventriculo-peritoneal shunt.

Case Report

Ekstraksi Peritoneal Shunt pada Anak-anak Menggunakan Laparoskopi: Sebuah Laporan Kasus

Abstrak

Laparoskopi merupakan salah satu cara untuk melakukan berbagai macam tindakan sederhana atau pembedahan pada daerah rongga perut. Laparoskopi dapat bermanfaat dalam penatalaksanaan kasus fraktur Ventriculo-Peritoneal Shunt (VP Shunt). Komponen peritoneal shunt yang tertinggal dalam rongga abdomen dapat dikeluarkan menggunakan laparoskopi. Seorang pasien anak-anak penderita hidrosefalus dengan riwayat pemasangan VP Shunt 5 tahun yang lalu, datang dengan keluhan badan lemas, muntah-muntah dan sulit makan. Pemeriksaan

fisik mendapatkan adanya edema pada area chamber. Pemeriksaan CT scan kepala dan foto polos abdomen dilakukan. Diagnosis yang dibuat adalah fraktur shunt, dengan tertinggalnya komponen peritoneal shunt pada rongga abdomen. Pasien mendapatkan tatalaksana berupa revisi VP Shunt dan ekstraksi peritoneal shunt menggunakan laparoskopi standar yang biasa digunakan untuk pasien dewasa. Kondisi pasien membaik pasca tindakan. Ekstraksi peritoneal shunt pada kasus fraktur VP Shunt dapat dilakukan menggunakan laparoskopi dengan aman. Apabila terdapat keterbatasan alat, tindakan ini tetap dapat dilakukan kepada anak menggunakan laparoskopi standar yang biasa digunakan untuk pasien dewasa. Penulis menyusun laporan ini, karena sebelumnya tidak didapatkan laporan mengenai kasus serupa di daerah Mojokerto.

Kata Kunci: ekstraksi, fraktur shunt, laparoscopi, laporan kasus, ventriculo-peritoneal shunt.

INTRODUCTION

Laparoscopy is one way to perform surgical procedures on the abdominal cavity area. Laparoscopy is one of several types of procedures that belong to the group of minimally invasive surgical procedures (Spight et al., 2015). Almost all surgical procedures can be performed using minimally invasive techniques (Vernon and Hunter, 2013).

Hydrocephalus is an abnormal accumulation of cerebrospinal fluid or *Liquor Cerebro Spinalis* (LCS), in the ventricles of the brain. Insertion of *Ventriculo-Peritoneal Shunt (VP Shunt)* is one of the frequently performed methods (Greenberg, 2016). *Shunt* fracture is one of the late complications of *shunt* insertion. *Shunt* fractures occur due to a combination of calcification processes of *the shunt*, mobility in the head and neck area and chronic stretching of *the shunt* due to patient growth (Lee et al., 2016). Peritoneal component of fractured *shunt* that remains in the abdominal cavity can be extracted using laparoscopy (Boipai et al., 2019).

CASE PRESENTATION

Patient information and clinical examination

A pediatric patient was taken by his parents to Dr Wahidin Sudiro Husodo General Hospital, Mojokerto City (government hospital) on September 29, 2020 because the patient appeared to be weak since 3 days earlier. The patient was taken in public civilian vehicles without a referral letter. The patient has vomiting and decreased appetite. The patient had hydrocephalus and underwent *VP Shunt* insertion surgery in another hospital at 2015. The patient stop visiting since 1 year postoperatively. There is no known history of drug allergies by the family.

Initial study conducted by Pediatrician, it was found that the patient's general condition was weak, moderately dehydrated, and there was edema in the *VP Shunt chamber* area. Laboratory examination of the blood showed that the patient had mild hyponatremia. Hemoglobin levels and leucocyte values are within normal limits. At that time we suspected there was malfunction of *VP Shunt*. Furthermore, the patient was consulted to the Neurosurgeon, and a CT scan of the head was performed (Figure 2). Hyponatremia is corrected using 3 percent NaCl solution. The patient is admitted to a non-intensive care ward.

On the third day of treatment, the patient had seizures, followed by repeated seizures on the fourth day. The results of subsequent studies, based on palpation in the *tract shunt* area, we suspected the absence of *peritoneal shunt* (Figure 3). An X-Ray examination of *thoracoabdomen* is carried out later for the evaluation of the integrity of the *shunt*.

CT scan showed a picture of the position of the *ventricular shunt* was obtained in the ventricle. The *thoracoabdomen* photo revealed a *peritoneal shunt* was detached from the chamber and both ends of the catheter are present in the abdominal cavity. The results of the *CT scan* and *thoracoabdomen* photos concluded that there was a fracture of the *VP Shunt*. Furthermore, it is planned to revise of *the VP Shunt* and the extract the retained *peritoneal shunt* using laparoscopy. Laparoscopy is selected to minimize trauma during surgery. *VP Shunt* revision needed to be taken immediately so that the emergency condition of the increase in intracranial pressure can be stopped. The extraction of peritoneal component of the shunt, which can be done electively, is performed on the same time of surgery after the revision of the *VP Shunt*.

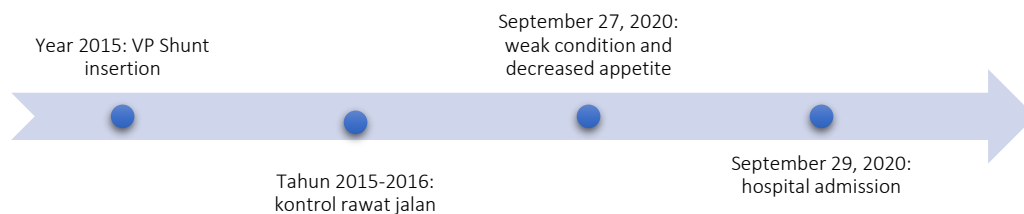


Figure 1. Case timeline

Intervention and its results

From the time of hospitalization until surgery, the patient had been treated for dehydration, hyponatremia, and seizures. The patient was transferred to Intensive Unit after a seizure occurred. The surgery carried out on the fifth day, namely insertion of a new *VP Shunt* system and the retrieval of the old *peritoneal component* of the *shunt* using laparoscopy.

The surgery began with general anesthesia in supine position. The insertion of a new *VP Shunt* system was performed by Neurosurgeon. After insertion of the new *VP Shunt* system, laparoscopic exploration of the abdominal cavity was carried out by General Surgeon (4 years working experience). Insertion of a 5 millimeters laparoscopic camera was carried out on the infraumbilicus area with an open technique. Insertion of the cannula is performed using a trokar on the abdominal area of the upper left quadrant. The gas pressure of CO₂ is set at 8 mmHg. Exploration of the abdominal cavity is then carried out (Figure Figure 6). Peritoneal identification of the old *shunt* was not difficult as the color of the old *shunt* catheter is milky white (Figure 6, Figure 8), while the color of the new *VP Shunt* catheter is clear. *The peritoneal shunt* was successfully extracted (Figure 7Figure 7).

Postoperatively, the patient went back to Intensive Unit and received therapy of fluids, anti-seizures, antibiotics, anti-inflammatories. In subsequent evaluations, seizures were no longer observed in the patient. Appetite was gradually improved. By the second post-surgical day, the patient was transferred to a regular treatment room. The next day, patient was discharged. Follow-up evaluations were carried out in the clinic on the 7th and 14th day. The patient was found to be in good health condition and the surgical wound healed completely.

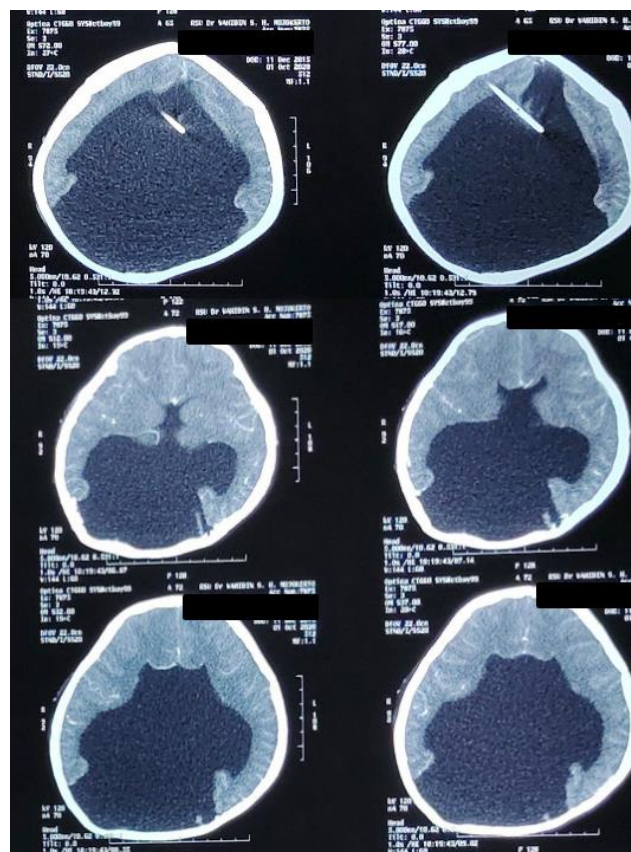


Figure 2. CT scan of the head

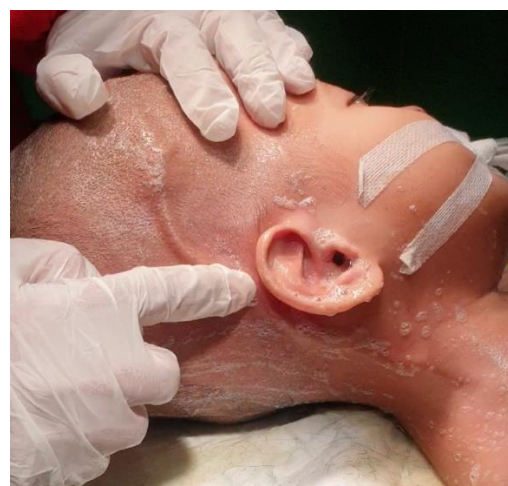

Figure 3. Palpation of the tract shunt area

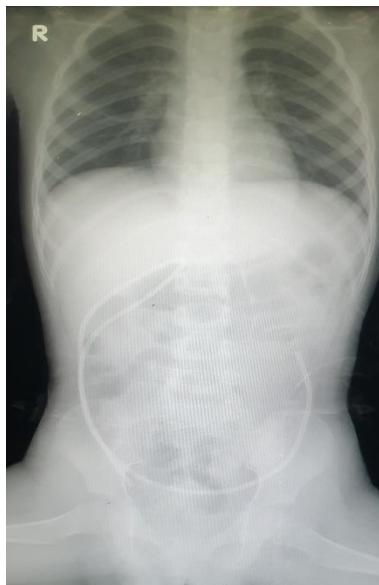


Figure 4. A plain photo of the abdomen shows both ends of the *VP Shunt* catheter within the abdominal area

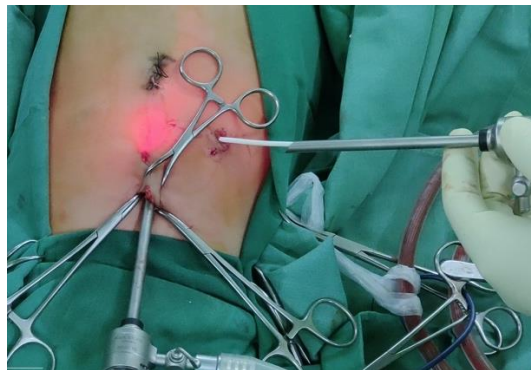

Figure 7. Peritoneal shunt extraction using laparoscopy

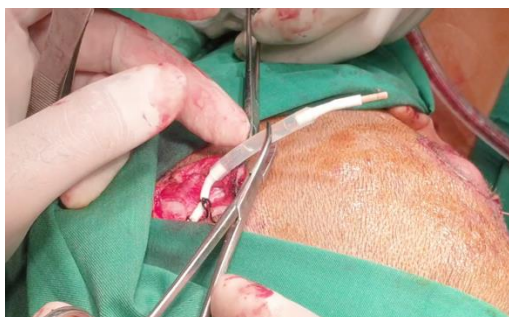

Figure 5. Visible chamber did not connected to the *peritoneal shunt*

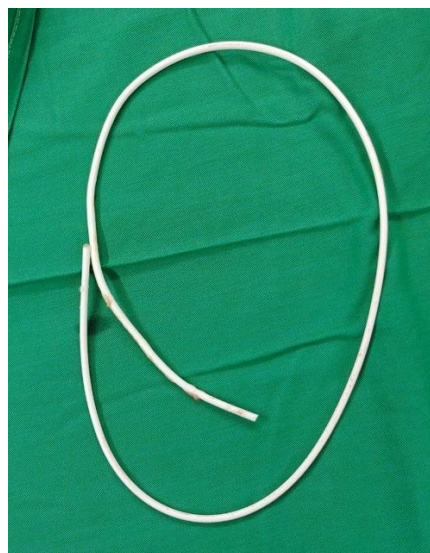

Figure 8. Retained *Peritoneal shunt*

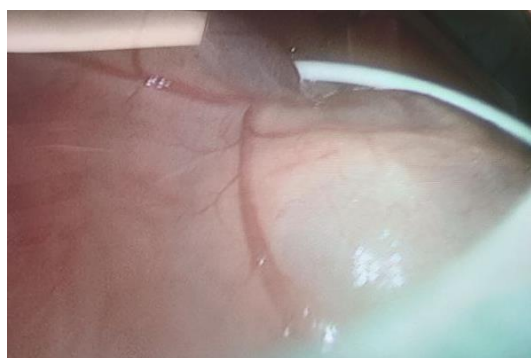


Figure 6. *Peritoneal shunt* is clearly visible at the time of laparoscopy

DISCUSSION

The insertion of VP shunt can cause complications in the form of infection, malposition, or shunt malfunction. When symptoms arise due to these complications, the patient often comes or is consulted first to Pediatrician. Careful study is needed to give proper management. Patients with a history of VP Shunt insertion who complaint of vomiting, weak, or having seizures, need to be suspected of having problems in the shunt system. A complete history taking and physical examination combined with adjunct examination are needed to rule out possible problems in the VP Shunt system. When the study found suspicion shunt system problem, patients can be treated with collaboration of Neurosurgeon. Failure to identify the source of intracranial problems can result in delay of management and mortality (Fernando et al., 2019).

In this case, a routine examination of serum electrolytes was carried out and mild hyponatremia results were obtained. These findings do not match the severity of the patient's clinical condition, namely vomiting, weakness, and seizures. Thus, there is a suspicion of intracranial problems (Bothwell et al., 2019).

VP Shunt malfunction is one of the complications that often occurs in the case of patients after the insertion of VP shunt (Paff et al., 2018). Therefore, more observation and attention is needed regarding the possibility of shunt malfunctions mainly due to shunt fractures in patients after shunt insertion.

Laparoscopy is one way to perform major surgery, with a small incision. Primitive laparoscopic using a cystoscope was first introduced in 1901 by Kelling, until now, laparoscopy is widely used for daily management (Spight et al., 2015). The laparoscopic method was chosen for the exploration of the abdominal cavity in the hope of providing the advantage of this technique over laparotomy surgery. Some authors mention that laparoscopic techniques are better when compared to open surgery regarding hospitalization time, anti-inflammatory use, and the return of postoperative physical activity (Coccolini et al., 2015). Laparoscopy can be safely used for the retrieval of medical devices that have migrated into intra-abdomen such as Intra Uterine Devices (Mosley et al., 2012) or fractured *peritoneal shunts* (Boipai et al., 2019).

When conducting exploration using laparoscopy in pediatric patients, one of the things to note is intra-abdominal pressure. In these case, an intra-abdominal pressure regulation of 8 mmHg was used (Pelizzo et al., 2019). In adult patients, the standard intra-abdominal pressure is set at 12-14 mmHg (Kanwer et al., n.d.). The laparoscopic equipment used in this patient is a standard set for adult patients, which is a cannula with a diameter of 5 millimeter. Some companies providing laparoscopic equipment have special laparoscopic series of children with a diameter of 2.5 and 3.5 millimeters. Despite that, during surgery the foreign body can be identified removed easily.

The downside of laparoscopic use is the unavailability of this device in some hospitals. Alternatively, laparotomy open surgery can be

performed to perform exploration and extraction of peritoneal shunts (Gigola et al., 2022).

CONCLUSION

The patient experienced an improvement of general condition after treatment. Thus, the authors conclude that the extraction of fractured *peritoneal* component of the can be done safely using laparoscopy with good results. The parents are satisfied with the treatment, and have given permission to display clinical photos and adjunct examinations on this report.

ACKNOWLEDGEMENT

The authors state there is no conflict of interest in the reporting of the case. Authors receive no funding for this study.

REFERENCES

Boipai, M., Barolia, D.K., Mathur, V., Farooq, A., Mathur, P., 2019. Laparoscopic removal of detached peritoneal end of ventriculo-peritoneal shunt. *J. Pediatr. Endosc. Surg.* 1, 83–84. <https://doi.org/10.1007/s42804-019-00011-2>

Bothwell, S.W., Janigro, D., Patabendige, A., 2019. Cerebrospinal fluid dynamics and intracranial pressure elevation in neurological diseases. *Fluids Barriers CNS* 16, 9. <https://doi.org/10.1186/s12987-019-0129-6>

Coccolini, F., Catena, F., Pisano, M., Gheza, F., Fagioli, S., Di Saverio, S., Leandro, G., Montori, G., Ceresoli, M., Corbella, D., Sartelli, M., Sugrue, M., Ansaloni, L., 2015. Open versus laparoscopic cholecystectomy in acute cholecystitis. Systematic review and meta-analysis. *Int. J. Surg.* 18, 196–204. <https://doi.org/10.1016/j.ijvs.2015.04.083>

Fernando, S.M., Tran, A., Cheng, W., Rochweg, B., Taljaard, M., Kyeremanteng, K., English, S.W., Sekhon, M.S., Griesdale, D.E.G., Dowlathshahi, D., McCredie, V.A., Wijdicks, E.F.M., Almenawer, S.A., Inaba, K., Rajajee, V., Perry, J.J., 2019. Diagnosis of elevated intracranial pressure in critically

- ill adults: systematic review and meta-analysis. *BMJ* 4225. <https://doi.org/10.1136/bmj.l4225>
- Gigola, F., Grimaldi, C., Bici, K., Ghionzoli, M., Spinelli, C., Muiesan, P., Morabito, A., 2022. Epidemiology and Surgical Management of Foreign Bodies in the Liver in the Pediatric Population: A Systematic Review of the Literature. *Children* 9, 120. <https://doi.org/10.3390/children9020120>
- Greenberg, M.S., 2016. Hydrocephalus, in: *Handbook of Neurosurgery*. Thieme, pp. 307–340.
- Kanwer, D.B., Kaman, L., Verma, G.R., Bala, I., n.d. Surgical Gastroenterology Comparative study of low pressure versus standard pressure pneumoperitoneum in laparoscopic cholecystectomy - A randomised controlled trial. *Trop. Gastroenterol.* 4.
- Lee, L., Low, S., Low, D., Ng, L.P., Nolan, C., Seow, W.T., 2016. Late pediatric ventriculoperitoneal shunt failures: a Singapore tertiary institution's experience. *Neurosurg. Focus* 41, E7. <https://doi.org/10.3171/2016.8.FOCUS16277>
- Mosley, F.R., Shahi, N., Kurer, M.A., 2012. Elective Surgical Removal of Migrated Intrauterine Contraceptive Devices From Within the Peritoneal Cavity: A Comparison Between Open and Laparoscopic Removal. *JSLs* 16, 236–241. <https://doi.org/10.4293/108680812X13427982377265>
- Paff, M., Alexandru-Abrams, D., Muhonen, M., Loudon, W., 2018. Ventriculoperitoneal shunt complications: A review. *Interdiscip. Neurosurg.* 13, 66–70. <https://doi.org/10.1016/j.inat.2018.04.004>
- Pelizzo, G., Puglisi, A., Di Mitri, M., De Silvestri, A., Mura, G.B., Amoroso, S., Pollicino, R., Calcaterra, V., 2019. Laparoscopy in infants: close intraoperative hemodynamic monitoring for patient safety. *J. Pediatr. Endosc. Surg.* 1, 15–22. <https://doi.org/10.1007/s42804-019-00004-1>
- Spight, D.H., Hunter, J.G., Jobe, B.A., 2015. Minimally Invasive Surgery, Robotics, Natural Orifice Transluminal Endoscopic Surgery, and Single-Incision Laparoscopic Surgery, in: *Schwartz's Principle of Surgery*. McGraw Hill, pp. 415–441.
- Vernon, A.H., Hunter, J.G., 2013. Fundamentals of Laparoscopic Surgery, in: *Maingot's Abdominal Operations*. McGraw Hill, pp. 63–74.